


Caso Clínico

Uma Úlcera de Difícil Cicatrização: Um Caso Exuberante de Dermatite de Contacto Alérgica ao L-Mesitran® Tulle

Joana Calvão¹, Ricardo Batista², Margarida Gonçalo^{1,3} 

¹Serviço de Dermatologia, CHUC

²Serviço de Saúde Ocupacional, CHUC

³Clínica de Dermatologia, Faculdade de Medicina, Universidade de Coimbra

RESUMO – O L-Mesitran Tulle® é um penso não aderente de polietileno popular, impregnado com o gel L-Mesitran Soft patenteado que contém Medilan™, considerada uma "lanolina hipoalérgica". A lanolina é um alergénio bem conhecido e a prevalência de alergia de contato aos álcoois de lanolina varia de 0,6% a 6,9%. Relatamos o caso de um doente que desenvolveu eczema ao redor de úlcera da perna enquanto realizava cuidados de penso com o L-Mesitran Tulle®, destacando que mesmo essa "lanolina de grau médico de alta pureza" (Medilan™) contida no L-Mesitran Tulle® pode causar dermatite de contacto alérgica.

PALAVRAS-CHAVE – Dermatite de Contacto Alérgica; Lanolina.

A Hard-to-Heal Cutaneous Ulcer: An Exuberant Case of Allergic Contact Dermatitis to L-Mesitran® Tulle

ABSTRACT – L-Mesitran Tulle® is a popular non-adherent polyethylene dressing impregnated with the patented L-Mesitran Soft gel that contains Medilan™, which is said to be a "hypoallergenic lanolin". Lanolin is a well know sensitizer and the prevalence of contact allergy to lanolin alcohols varies from 0.6% - 6.9%. We report the case of a patient who develop eczema around the leg ulcer while using L-Mesitran Tulle® as a wound dressing, highlighting that even this "high purity medical grade of lanolin" (Medilan™) contained in L-Mesitran Tulle® can cause an allergic contact dermatitis.

KEYWORDS – Bandages; Dermatitis, Allergic Contact; Lanolin.

INTRODUCTION

L-Mesitran Tulle® is a popular non-adherent polyethylene dressing impregnated with the patented L-Mesitran Soft gel, which main ingredients are 40% medical grade honey, propylene glycol, polyethylene glycol (PEG) 4000, vitamins C & E and Medilan™ - said to be a "medical grade hypoallergenic lanolin"/"the high purity medical grade of lanolin". The skin healing ability of honey has been attributed to its antimicrobial properties, its ability to modulate the skin's immune system and promote tissue repair.¹

We report the case of a patient who developed eczema around the leg ulcer while using L-Mesitran Tulle® as a wound dressing, although other allergens might also have contributed to the dermatitis.

CASE REPORT

A 52-year-old male, mechanical engineer, with no history of atopy and no chronic medication, presented with 2x2 cm ulcer on the pre-tibial region of the right leg. There was no underlying arterial disease but this painless ulcer that developed after trauma did not heal for 6 months despite several leg ulcer dressings, including L-Mesitran Tulle®. In the preceding 3 weeks he developed intensely itchy and exudative erythematous plaques, vesicles and some pustules on the ipsilateral leg, suggestive of acute eczema, with distant papulo-vesiculous lesions on the upper limbs. Oral prednisolone (starting with 40 mg/day, with 5 mg reduction every 3 days) was used in association with local care with potassium permanganate patches (1: 10 000) and topical

Correspondência: Joana Calvão
Serviço de Dermatologia
Centro Hospitalar e Universitário de Coimbra
Praceta Mota Pinto,
3000-075 Coimbra, Portugal
E-mail: joana.calvao.silva@gmail.com
DOI: <https://dx.doi.org/10.29021/spdv.78.1.1149>

Recebido/Received 2019/12/19	Aceite/Accepted 2020/02/08	Publicado/Published 2020/04/--
--	--------------------------------------	--

© Autor (es) (ou seu (s) empregador (es)) 2019. Reutilização permitida de acordo com CC BY-NC. Nenhuma reutilização comercial.
© Author(s) (or their employer(s)) 2019. Re-use permitted under CC BY-NC. No commercial re-use.

Caso Clínico

fluticasone cream and the leg ulcer dressing was replaced by Acquacel-Ag®.

Due to worsening of eczema on the leg, contact dermatitis was suspected and patch testing were performed. The European Baseline series and a cosmetics/vehicles and a topical medications series (Chemotechnique Diagnostics, Vellinge, Sweden) as well as small fragments of leg dressings, namely L-Mesitran Tulle® and Acquacel-Ag® were applied with finn chambers on the upper back. A semi-open test was performed with Prontosan® "as is", that was applied on the back, and after drying was covered only by a tissue tape. Patches were removed on day (D)2 and readings performed on D3 and D7. Strong positive reactions were observed to lanolin wool 30% pet. (+++), amerchol L101 50% pet. (+++) and L-Mesitran tulle® "as is" (+++), chlorhexidine digluconate 0.5% water (+) and Prontosan® "as is" in a semi-open test (+++) (Fig. 1). Patch tests with propolis 10%, propylene glycol 5% pet., Acquacel-Ag® "as is" and other dressings gave negative results. Treatment with Acquacel-Ag® was continued with improvement of the ulcer and total resolution of the eczema, reinforcing that L-Mesitran Tulle® containing lanolin was the main driver of his allergic contact dermatitis (ACD). We could not entirely clarify the positive reaction to Prontosan®, used only recently as a short contact disinfectant before the ulcer dressing application. An irritant reaction could not be completely excluded although more

than 20 controls tested also in a semi-open test were negative. A positive reaction to chlorhexidine (1,6-bis(4-chlorophenylbiguanido)hexane) might represent a cross-reaction to polyhexanide (polyhexamethylene biguanide), the other biguanide present in Prontosan®, but we could not test it as the patient did not collaborate in further testing.

DISCUSSION

Lanolin is a highly complex and variable mixture of long chain esters, lanolin alcohols and lanolin acids, derived from wool wax, the secretion of sheep sebaceous glands (Latin: *lana* = wool).²

Contact allergy to lanolin began to attract attention in the 1950s, and at the end of the 20th century it has achieved notoriety among the general public and non-dermatologists as a sensitizer.² The exact sensitizing component of lanolin remains unknown; however, most scientists agree that the alcohol fraction is the culprit allergen,^{3,4} and wool alcohols 30% in petrolatum (pet.) has been included in the European standard series since 1969.^{2,3,5}

The prevalence of contact allergy to lanolin alcohols varies from 0.6% - 6.9%.^{3,4,6} Several studies have reported that Amerchol™ L101, a blend of mineral oil and about 10% lanolin alcohols, gives a higher yield of positive patch tests than 30% wool alcohols.² A recent retrospective observational study from Copenhagen of consecutively patch tested

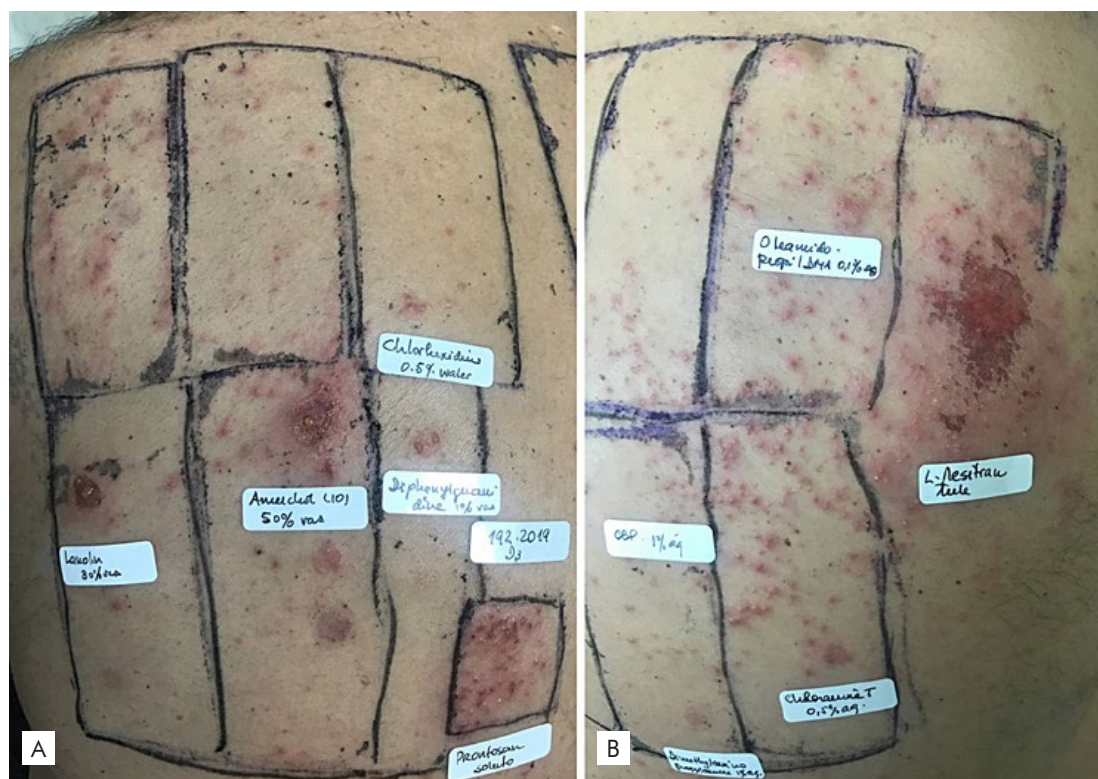


Figura 1 (a-b) - Patch test reading at day 3 showing strong positive reactions to lanolin wool 30% pet. (+++), amerchol L101 50% pet. (+++) and L-Mesitran tulle® "as is" (+++), as well as to chlorhexidine (1+) and to Protosan® as is in a semi-open test.

dermatitis patients (n=9577) between 1 January 2004 and 31 December 2015 showed an overall increasing prevalence of contact allergy to lanolin and agreed that inclusion of Amerchol™ L101 will increase the chance of detecting lanolin contact allergy.⁴ Uter *et al*⁷ have recently analysed data from the Information Network of Departments of Dermatology (IVDK) in Germany and did not observe an increasing trend of contact allergy to lanolin alcohol and/or Amerchol™ L101. In the beginning of the current year, Knijp J *et al*⁶ confirmed that using lanolin alcohol and Amerchol™ L101 is an effective combination of patch test preparations for diagnosing lanolin contact allergy and concluded that routinely testing with other lanolin derivatives may not be worthwhile, as it detects only a few additional patients.

In our Department we have been testing both lanolin alcohols and Amerchol L101 for more than 20 years, with a decreasing frequency of reactions in the last 10 years from 2.6% and 2.9% of positive reactions respectively to lanolin and Amerchol L101 in 2007/8 to 1.2% and 1.8% in 2017/18. This may be related with a decreasing trend of ACD to topical drugs, as shown also in other departments.⁸

Additionally, studies suggest that contact allergy to topical medicaments becomes more common with advancing age and that the incidence of positive patch test reactions to wool alcohols increases in patients with leg ulcers, stasis dermatitis, and other contact allergies,³ as in our patient.

There are some suggestions that "purified lanolin" is not so sensitizing,⁹ but this case illustrates that even this "high purity medical grade of lanolin" (Medilan™) contained in L-Mesitran Tulle® can cause ACD.

Conflitos de interesse: Os autores declaram a inexistência de conflitos de interesse na realização do presente trabalho.

Fontes de financiamento: Não existiram fontes externas de financiamento para a realização deste artigo.

Confidencialidade dos dados: Os autores declaram ter seguido os protocolos da sua instituição acerca da publicação dos dados de doentes.

Consentimento: Consentimento do tutor legal para publicação obtido.

Proveniência e revisão por pares: Não comissionado; revisão externa por pares.

Conflicts of interest: The authors have no conflicts of interest to declare.

Financing support: This work has not received any contribution, grant or scholarship.

Confidentiality of data: The authors declare that they have followed the protocols of their work center on the publication of data from patients.

Patient Consent: Consent for publication was obtained.

Provenance and peer review: Not commissioned; externally peer reviewed

ORCID

Joana Calvão

<https://orcid.org/0000-0002-1161-269X>

Margarida Gonçalves

<http://orcid.org/0000-0001-6842-1360>

REFERENCES

1. McLoone P, Oluwadun A, Warnock M, Fyfe L. Honey: a therapeutic agent for disorders of the skin. *Cent Asian J Glob Heal.* 2016;5:241. doi:10.5195/cajgh.2016.241
2. Wakelin SH, Smith H, White IR, Rycroft RJG, Mcfadden JP. A retrospective analysis of contact allergy to lanolin. *Br J Dermatol.* 2001;145:28-31. doi:10.1046/j.1365-2133.2001.04277.x
3. Nguyen JC, Chesnut G, James WD, Saruk M. Allergic contact dermatitis caused by lanolin (wool) alcohol contained in an emollient in three postsurgical patients. *J Am Acad Dermatol.* 2010;62:1064-5. doi:10.1016/j.jaad.2009.10.020
4. Fransen M, Overgaard LEK, Johansen JD, Thyssen JP. Contact allergy to lanolin: temporal changes in prevalence and association with atopic dermatitis. *Contact Dermatitis.* 2018;78:70-5. doi:10.1111/cod.12872
5. Epstein E, Mateo S. The detection of lanolin allergy. *JAMA Dermatol.* 1972;106:678-81.
6. Knijp J, Bruynzeel DP, Rustemeyer T. Diagnosing lanolin contact allergy with lanolin alcohol and Amerchol L101. *Contact Dermatitis.* 2019;80:298-303. doi:10.1111/cod.13210
7. Uter W, Schnuch A, Geier J. Contact sensitization to lanolin alcohols and Amerchol® L101 – analysis of IVDK data. *Contact Dermatitis.* 2018;78:355-71. doi:10.1111/cod.12907
8. Gilissen L, Goossens A. Frequency and trends of contact allergy to and iatrogenic contact dermatitis caused by topical drugs over a 25-year period. *Contact Dermatitis.* 2016;75:290-302. doi:10.1111/cod.12621
9. Stone L. Medilan: A hypoallergenic lanolin for emollient therapy. *Br J Nurs.* 2000;9:54-7. doi:10.12968/bjon.2000.9.1.6415