

We are IntechOpen, the world's leading publisher of Open Access books Built by scientists, for scientists

4,800

Open access books available

122,000

International authors and editors

135M

Downloads

Our authors are among the

154

Countries delivered to

TOP 1%

most cited scientists

12.2%

Contributors from top 500 universities



WEB OF SCIENCE™

Selection of our books indexed in the Book Citation Index
in Web of Science™ Core Collection (BKCI)

Interested in publishing with us?
Contact book.department@intechopen.com

Numbers displayed above are based on latest data collected.

For more information visit www.intechopen.com



Specificities of Adult Orthodontics

Mourad Sebbar, Nassiba Fatene, Asmaa El Mabrak, Narjisse Laslami,
Zouhair Abidine and Zakaria Bentahar

Additional information is available at the end of the chapter

<http://dx.doi.org/10.5772/59614>

1. Introduction

Adult orthodontics is becoming a larger proportion of many practices. Adult orthodontics is concerned with striking a balance between achieving optimal proximal and occlusal contact of the teeth, acceptable dentofacial esthetics, normal function, and reasonable stability. With the adult, it is more frequently concerned with physiological adaptation and is often symptom related, whereas with the child the dealing is with the signs. In the past three decades, a major reorientation of orthodontic thinking has occurred regarding adult patients [1].

Changed lifestyles and patient awareness have increased the demands for adult orthodontic treatment and multidisciplinary dental therapy has allowed better management of the more complicated and unique requirements of the adult patient population, thereby greatly improving the quality of care and treatment prognosis. In addition to goal clarification, adult patients desire treatment efficiency, convenience in appointment timings and good communication with other health care professionals. Almost 80% of the adult patients require interdisciplinary treatment planning and treatment execution. With the adult, consultation with another specialist isn't occasional. It is the rare adult whom one treats orthodontically without finding it necessary to collaborate with another specialist. This represents both the challenge and the excitement of adult orthodontics [2].

The objectives of adult orthodontics correspond to the general objectives of orthodontics i.e.: optimum occlusal function; improve the aesthetics of the face and teeth; contribute to the longevity of the stomatognathic system. However, a fourth objective can add in adults: realize a treatment of "aid" to the prosthesis.

The purpose of this chapter is to review, through clinical cases, the scope, effectiveness and limitations of orthodontic treatment in adult patients.

2. Psychological considerations

The demand for correction of malocclusion is often psychological and sociological rather than somatic. The relationship between psychology and orthodontics has been either ignored, or dealt with in mechanical ways. This is an area in which speculation and given work of irresponsible kind takes place [3].

Beauty is often more than skin deep because the psychological damage to a person who feels unattentive can be extreme. Orthodontic treatment provides a person a strong sense of feeling along with awareness, that he or she is not powerless, but that through proper co-operation can change and control outcomes.

Fundamental knowledge of psychology is necessary for modern orthodontics. The study of actions and reactions of individuals in social situations and the influence of such reactions on an individual is known as “dialectic psychology” [4].

Several authors have commented on the increase in the number of adults coming for orthodontic [5, 6]. This phenomenon has been attributed to various factors including the improved appearance of fixed appliances [7], increased awareness of the possibilities of orthodontic treatment, and the social acceptability of fixed appliances. Regardless of this, there is little information on this subgroup of patients; in particular, there is a lack of research on adults’ motives for seeking orthodontic treatment. As early as 1971, Edgerton and Knorr [8] proposed the source of motivation to be the most crucial factor in determining and predicting patient satisfaction with treatment. This statement was made in relation to patients seeking esthetic surgery; however, it is likely that this hypothesis can be extrapolated to many types of treatment, including adult orthodontic treatment.

3. Biological considerations

The orthodontic treatment of adult patients differs from that of children in that there is no further appreciable skeletal growth in adult patients and the treatment is often multidisciplinary. There are, however, slow skeletal changes taking place in the facial bones during adulthood and the dentoalveolar compensation mechanism still occurs. The initially slower tissue response in adults compared with that in children does not significantly affect the total treatment time, since adult patients are general more co-operative than children, which seems to compensate for the slower tissue response [9].

- **Age changes in bone:** Cortical bone becomes denser and the spongy bone reduces with age. Marginal bone loss is more common in adults, which leads to apical shifting of the center of resistance of the involved tooth resulting in increased tipping moment produced by the applied force. This requires proper biomechanics utilizing adequate counter moment to achieve bodily movement of periodontally involved teeth [10].
- **Periodontal considerations:** A viable periodontal ligament is important for cell proliferation on application of mechanical force. There is a reduction in the periodontal ligament

vascularity with aging and insufficient source of preosteoblasts, which may explain the delayed response to orthodontic forces described in adults. It is mandatory to employ lighter force levels in adults as heavier forces result in vascular compression and necrosis of the blood vessels of the periodontal ligament. There is high-risk of iatrogenic damage to the periodontium with uncontrolled forces and it is important to keep the periodontal status under control during treatment [11, 12].

- **Vulnerability for root resorption:** Adults are more vulnerable to root resorption on application of orthodontic force. This is most commonly seen during intrusion of anterior and posterior teeth. Light continuous force must be employed to minimize the risk of root resorption and the patients must be informed of the potential risk before starting the treatment. It is mandatory to take periodical IOPA radiographs to evaluate for signs of root resorption. In case resorption is detected, active forces must be withdrawn for 7-8 weeks and further treatment can be continued after cessation of root resorption [13].

4. Diagnostic considerations

Careful diagnosis and treatment planning on a multidisciplinary approach is required to treat most adult patients. The adult, unlike the child, is usually a patient with high expectations from orthodontic treatment. He presents with minimal or no growth potential and meager accommodation to mechanics. In addition, the adult may exhibit a potential for such pathological changes as knife-edge ridges increased thickness of cortical plates, buried roots, impactions, gingival recession, periodontal breakdown, missing teeth, mesial tilting and extrusion of molars due to nonreplacement of extracted posterior teeth, TMJ problems, osteoporosis, osteomalacia and diabetes mellitus. These conditions, which obtain as a result of hormonal, vitamin or systemic disorders common to the adult, necessitate more careful and extensive diagnosis evaluations.

Orthodontic diagnosis involves development of a comprehensive database of pertinent information. The standard diagnostic aids such as case history, clinical examination and study casts, radiographs and photographs are mandatory [4].

Intraoral Periapical (IOPA), occlusal and TMJ films should be obtained routinely in addition to the panoramic radiograph and the cephalogram. The “problem oriented diagnostic approach” as described by Proffit and Ackerman, 1 is strongly recommended to ensure that no aspect of the patient need is neglected [14].

Additional diagnostic procedures that we should consider in an adult patient are:

- A full series intraoral periapical radiographs and TMJ X-rays.
- Diet evaluation
- Requirement of multidisciplinary approach towards treatment. Diagnostic steps involved in treating adult patients:
- Collection of accurate history and thorough patient examination

- Analyze the database
- Develop a problem list and priority
- Prepare tentative treatment plan according to the priorities
- Interact with other specialists involved. Acquire patient acceptance for the proposed treatment plan.

5. Therapeutic considerations

In the recent times, with the increasing expectations of the patients to an esthetically and functionally stable treatment result, the practice of dentistry is changing from a single specialist or general dentist practice to that of a team approach.

This enables the best utilization of the skills and expertise of clinicians of different specialties for the best possible treatment outcome of the patient. Such joint care of a patient's dental needs is defined as interdisciplinary treatment [15].

Interdisciplinary approach is indispensable for patients with mutilated dentition. Patients with congenital defects can be best treated with such a team work only. It is also of utmost importance in adult patients presenting with severe jaw discrepancies, abraded or worn teeth, old failing restorations, tipped teeth, multiple edentulous spaces from previous tooth extraction, periodontal breakdown, recession, and many other periodontal and restorative problems [16]

The role of orthodontist in such an interdisciplinary treatment approach can be primary or secondary. Primary as in a case wherein an orthodontic patient requires adjunctive other specialties treatment as prosthetic replacement of missing teeth, tooth build-up to match a Bolton discrepancy, periodontal rehabilitation, surgical exposure of an impacted tooth, etc. Secondary as in cases where the orthodontic treatment rendered is an adjunct to other treatment planned. Like in the case of space creation or tooth up righting to facilitate prosthetic replacement of a missing tooth, etc. [17].

Patient may have high expectations and hesitation in accepting visibility of orthodontic appliances. For esthetic reasons, patient may demand ceramic brackets or lingual orthodontics. Patient must be informed about the limitations of the treatment.

Closure of old extraction site may be difficult especially in molar region [18]. It may need uprighting to open the space mesially to receive prosthesis.

While bonding, special considerations may be required due to presence of restorations such as porcelains and metallic surfaces [19]. Excess adhesive around orthodontic attachments should be removed as surface roughness of adhesive attracts more plaque retention. Strict oral hygiene procedures must be reinforced as patients with periodontal problems may have various difficult areas to clean. All restorations must be properly polished to reduce the tendency of plaque retention. Stainless steel ligatures may be preferred to elastomeric modules due to less retentive to plaque [20].

Quantitative and qualitative changes in bone and compromised periodontal support and missing tooth may need special consideration to plan anchorage [21]. Headgears may not be acceptable to an adult due to esthetic reasons. Hence intraoral anchorage devices such as palatal arches and controlled forces are used. Microimplants can also be used to avoid dependence on teeth for anchorage.

Choice of extraction for orthodontic treatment may be affected by periorestorative problems or already extracted tooth. Occlusion achieved in adults, are stable in a healthy patient but compromised periodontal status may need permanent retention [22, 23].

5.1. Orthodontics-periodontics relationships

Under severe control against formation of dental biofilm and elimination or surveillance of periodontal pockets, patients who present susceptible or compromised periodontal status can be submitted to orthodontic treatment, like our patient who consulted for dental crowding which complicate hygiene measures (fig.1) [24, 25, 26]. Moreover, the orthodontic treatment allows that the stable periodontal status is maintained (fig 2).

Although there is no clear correlation between malocclusion and periodontal disease or between the effects of orthodontic treatments on periodontal improvement the literature describes clear interaction between Orthodontics and Periodontics [27].

Probable contributions of orthodontics in the periodontics field are:

1. It allows better oral hygiene by the patient, since it provides well shaped dental arches. Without dental crowding, malocclusion as a periodontal disease facilitator is eliminated (fig. 3)
2. It allows vertical occlusal impact parallels to the long axes of the teeth. Therefore, the applied muscle force is uniformly distributed all over the dental arch (fig. 4);
3. It contributes, along with prosthetic rehabilitations, for a normal vertical dimension;
4. In selected cases, it allows that the adequate dental crown-root relationship is achieved with induced orthodontic extrusion, with no bone loss;
5. It facilitates that bone vertical defects are corrected or improved with dental uprighting;
6. It improves the positioning of prosthetic pillars for fixed prostheses and of the next teeth of osteointegrated implants;
7. It decreases or eliminates effects of bruxism, as pain or muscle spasms, during the orthodontic therapy;
8. With the current available orthodontic technology and with correct planning and execution, it allows precise, light and efficient orthodontic movements.

Periodontal status is important and must be evaluated before contemplating orthodontic treatment in adult patients. If the periodontal disease is not treated and plaque control methods initiated before initiating orthodontic treatment, then the orthodontic tooth movement causes

further periodontal destruction. This is particularly true if the teeth are moved in the direction of inflamed periodontal pockets that extend beyond the alveolar crest [28]. It is highly necessary to assess the patients' potential for bone loss and gingival recession during orthodontic tooth movement. The patient should be screened for the risk factors of periodontal disease.

Pre-treatment consultation with the periodontist should be routine and orthodontic objectives be altered according to his advice. Movement of teeth in the presence of periodontal inflammation will result in an increased loss of attachment and irreversible crestal bone loss.

Case n°1

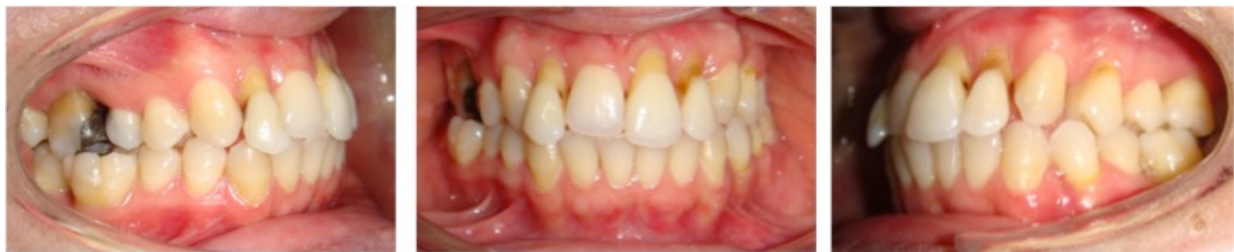

Figure 1. A young woman aged 20 years and the reason for consultation was gingival recession and dental crowding

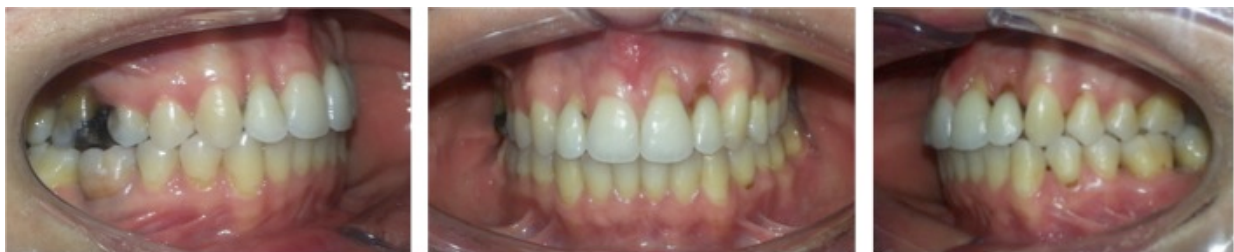

Figure 2. Orthodontic treatment consisted of an alignment and correction crowding, the patient was sent after removal of the orthodontic appliance to the periodontist for a gingival graft to cover gingival recession

Case n°2

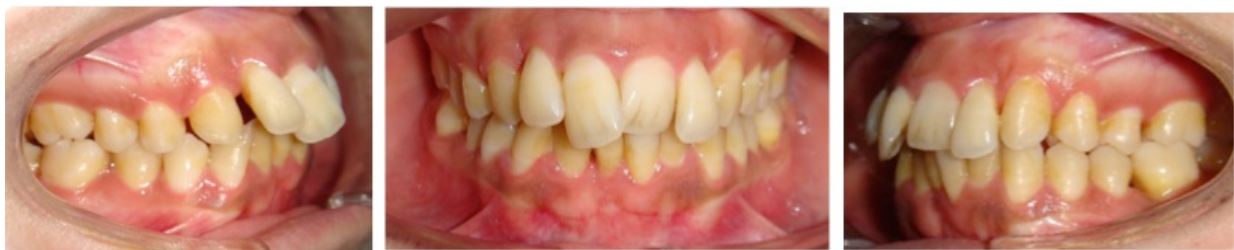

Figure 3. A patient who consults for malpositions and dental extrusions

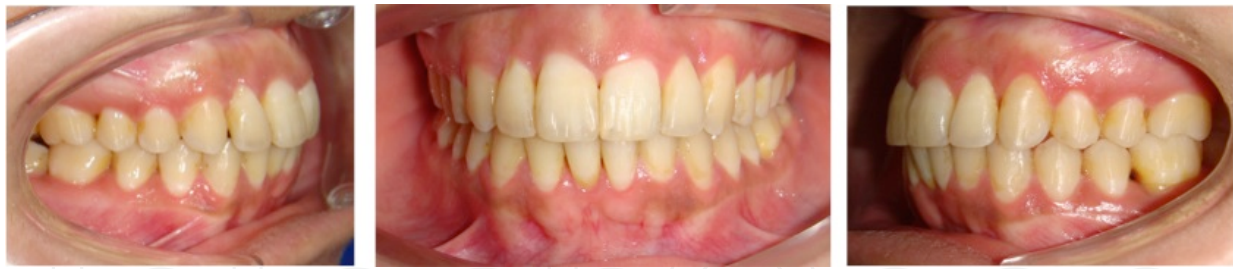

Figure 4. Orthodontic treatment was aimed at correcting dental malposition and regain proper alignment will facilitate the oral hygiene.

5.2. Orthodontic-prosthesis relationships

Adult patients usually require adjunctive and comprehensive treatment involving multidisciplinary treatment approach. Correcting the malocclusion helps in improving the quality of periodontal and restorative treatment outcomes besides providing esthetic benefits.

Adult are now more frequently referred for orthodontic treatment to improve the positioning and alignment of teeth prior to the replacement of missing teeth (fig. 5, 7). Such tooth movements may be undertaken to achieved parallel abutments of the teeth used to hold the prosthesis, to create space for a pontic (the false tooth in a bridge) or to make space for a dental implant (usually a titanium device that integrates with the jaw bone and can be used to support a crown or dental bridge). (fig. 6, 8)

It is often possible by orthodontic treatment to close spaces or re-position the remaining teeth following tooth loss. A good example of the usefulness of orthodontic treatment is when canines and premolars are moved posteriorly, eliminating either the need for a removable partial prosthesis to replace missing molars, or to allow insertion of a short-span fixed bridge, rather than the use a removable, partial prosthesis [9].

Adult patients have many preexisting conditions that are usually not present in adolescent patients. Hence, additional treatment objectives are established at the start of the treatment. Though acceptable esthetics is an integral part of treatment goal, but function, stability and health of dentition is given paramount importance. Additional treatment objectives are determined to facilitate and improve effectiveness of periorestorative treatment by [29]:

- Improving axial inclination of teeth, thereby improving root positioning with sufficient bone between roots for good vascular supply and proper contact area;
- Achieving parallelism of abutment teeth to minimize tooth cutting for fabrication of prosthesis;
- Most favorable distribution of abutment teeth to receive prosthesis for better stability;
- Uprighting and extrusion of posterior teeth with occlusal equilibration sometimes followed by endodontic treatment to improve vertical osseous defects and crown root ratio;
- Forced extrusion of teeth damaged up to one third of cervical line to provide better support at the margin of the prosthesis;

- To restore functional occlusion keeping in mind existing skeletal relationship rather than aiming for Andrew's six keys to normal occlusion;
- Achieving better lip support for flaccid & long upper lip by maintaining anterior teeth in slight procumbent position with correction of overjet by proclining & maintaining lower incisors in more procumbent position than normal position to avert wrinkles around the lips; & restoring vertical dimension with bite plate before placing prosthesis in bite collapse.

Case n°3

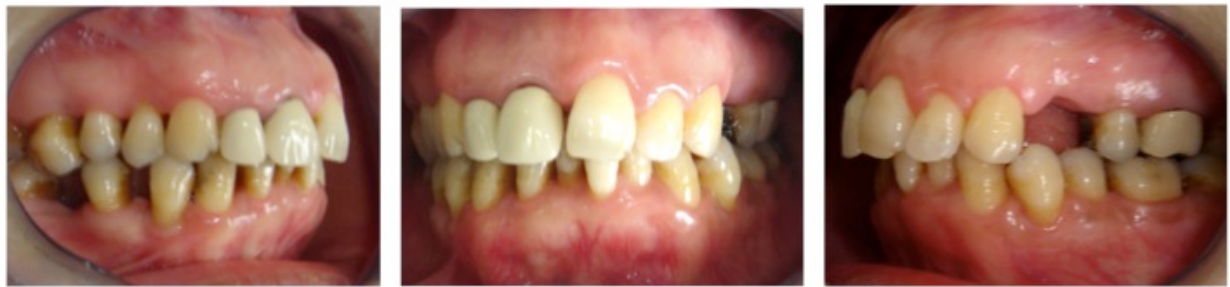

Figure 5. Clinical examination in this patient showed defective prostheses with poor periodontal status.

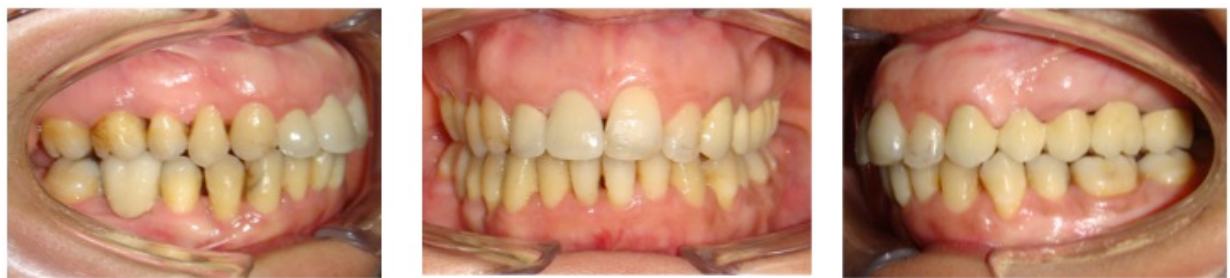

Figure 6. Orthodontic treatment was performed to correct the malocclusion. The patient also received a prosthetic rehabilitation.

Case n°4

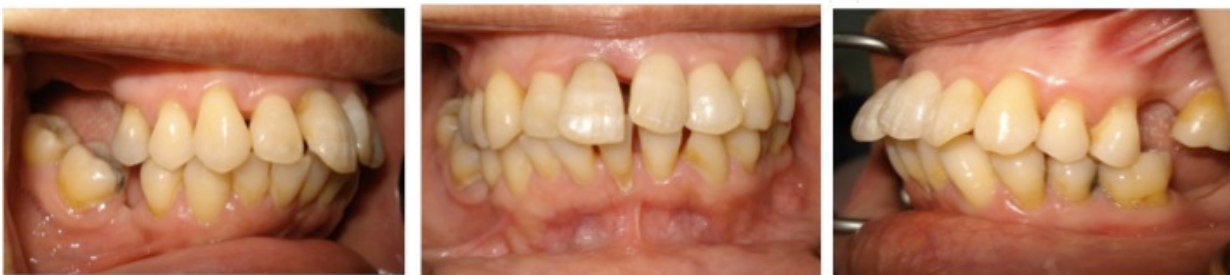

Figure 7. A patient aged 50years addressed for orthodontic treatment for future prosthetic rehabilitation.

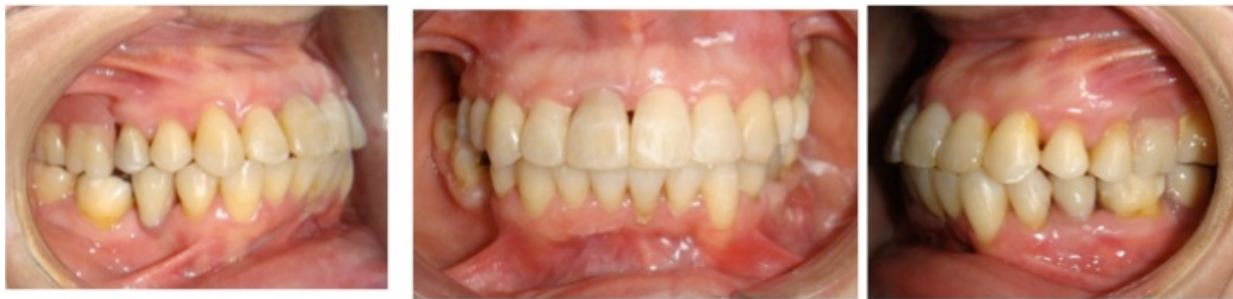

Figure 8. Orthodontic treatment was to correct malpositions and dental rotations and creates spaces for future prostheses. A provisional prosthesis was performed until achieve dental implants

5.3. Orthodontics-orthognathic surgery relationships

Skeletal malocclusion (dysgnathia) is defined as the congenital or acquired abnormal position or morphology of one or both jaws. There might be symmetry or asymmetry with disruption of the maxillomandibular relationship or the relationship of the jaws to the skull base combined with malocclusion or joint disruption [30]. The main treatment objectives for serious skeletal malocclusions are aesthetic, functional and psychological rehabilitation. For this kind of cases these goals may be achieved [31]. The orthodontist can move teeth and alveoli but this has no substantial impact on the adult basal jaw bone. The main orthodontist's task is teeth alignment. The oral & maxillofacial surgeon is responsible for the surgical correction of jaws and their associated structures. Generally speaking, the diagnosis and treatment plan of orthognathic cases require a systematic team approach [32].

Orthognathic surgery involves risks and this is why we need to proceed with it only after careful planning. It is particularly important to understand the patient's view; this establishes trust and communication and helps achieve high quality results [33].

Indications of orthognathic surgery [34, 35]

Given the relationship between facial skeletal deformities and masticatory dysfunction, as well as the limitations of non-surgical therapies to correct these discrepancies, orthognathic surgery should be considered medically appropriate in the following circumstances.

- a. Anteroposterior discrepancies: established norm=2mm
 1. Maxillary/Mandibular incisor relationship:
 - Horizontal overjet of +5mm or more.
 - Horizontal overjet of zero to a negative value (fig. 9).
 2. Maxillary/Mandibular anteroposterior molar relationship discrepancy of 4mm or more (norm 0 to 1mm).
- b. Vertical discrepancies
 1. Presence of a vertical facial skeletal deformity which is two or more standard deviations from published norms for accepted skeletal landmarks.

2. Open Bite
 - No vertical overlap of anterior teeth.
 - Unilateral or bilateral posterior open bite greater than 2mm
 3. Deep overbite with impingement or irritation of buccal or lingual soft tissues of the opposing arch.
 4. Supraeruption of a dentoalveolar segment due to lack of occlusion.
- c. Transverse discrepancies
1. Presence of a transverse skeletal discrepancy which is two or more standard deviations from published norms.
 2. Total bilateral maxillary palatal cusp to mandibular fossa discrepancy of 4mm or greater, or a unilateral discrepancy of 3mm or greater, given normal axial inclination of the posterior teeth.
- d. Asymmetries

Anteroposterior, transverse or lateral asymmetries greater than 3mm with concomitant occlusal asymmetry.

Preoperative orthodontics (fig. 10)

The goals of preoperative orthodontic treatment are to allow for maximum surgical correction of the abnormality, to facilitate potential sectional surgical procedures and to provide the possibility for creating an ideal, stable occlusion (Tompach et al., 1995). The major part of orthodontic treatment takes place before surgery and might last one and a half to two years (Slavnic & Marcusson, 2010; Diaz et al., 2010) [36, 37, 38]

1. Arch alignment

The first goal of preoperative orthodontics is to align the dental arches or their parts so that they might be compatible with each other. Correcting crowding and rotations, management of impacted teeth and arch length discrepancies is mainly a concern of preoperative orthodontics, because it facilitates arch intercuspation; otherwise, the surgical result would be restricted. [37]

2. Arch flattening

The planning of dental arch flattening is particularly important. Dental flattening and alignment are usually a common one-step process in conventional orthodontics. This is not the case for all surgical cases. When the mandible is surgically moved forward or backward, the position of the lower incisor is what determines the lower facial height. [38]

3. Exacerbations

In serious skeletal discrepancies, the teeth try to maintain some contact, under the effect of external and internal forces, so as to compensate for the skeletal problem. Although this

compensation improves occlusal relationships and the patient's appearance, it restricts the extent of surgical correction. In skeletal Class III cases, the upper incisors are often labially inclined, while the lower ones are lingually inclined. On the contrary, in cases of skeletal Class II the upper incisors are often upright and the lower labially inclined. A consequence of these compensatory changes is that the overjet is virtual in regard to the actual magnitude of the skeletal discrepancy. Preoperative orthodontics aims at exacerbating dental relationships, by removing the camouflage effect and placing the incisors in normal inclination for the skeletal bases, if this is feasible (Jacobs & Sinclair, 1983). [39]

4. Intercuspation of the two arches

One of the goals of preoperative orthodontics is to achieve harmonisation of dental arches at all levels during surgery. Before the end of the preoperative phase, upper and lower rigid rectangular wires need to be passively in position for eight weeks before surgery. Some type of hooks or brackets with thick attachments should be placed on the wires Kobayashi so as to facilitate immobilization during surgery. [40]

Surgical procedures. [41]

- Le Fort I Osteotomy (fig 11)

The vertical position of the maxilla is recorded by measuring the distance between the medial canthus and the orthodontic arch wire. These vertical measurements are absolutely critical. The cut should be made at least 5 mm above the apices of the teeth. If cuts are complete, the maxilla is downfractured with manual pressure. The amount the maxilla will be impacted or elongated was determined in the treatment plan.

- Surgically Assisted Rapid Palatal Expansion

Correction of transverse maxillary constriction can be corrected in adolescence with nonsurgical orthodontic appliances. As the sutures begin to close during late adolescence, relapse increases. A multipiece LeFort osteotomy can be performed to provide simultaneous maxillary expansion, but the degree of relapse is high. In the young adult, the preferred procedure is the surgically assisted rapid palatal expansion (SARPE). The orthodontist places a palatal expander prior to the procedure.

- Bilateral Sagittal Split Osteotomy

The cut is made with electrocautery about 1 cm from the lateral aspect of the molars and extends from midramus to the region of the second molar. If insufficient tissue is left on the dental side of the incision, closure is more difficult. A periosteal elevator is used to expose the lateral mandible and the anterior coronoid process in a subperiosteal plane.

- Two-Jaw Surgery

Moving the maxilla and the mandible in one procedure require osteotomizing both jaws and precisely securing them into the position determined by the treatment plan. If proper treatment planning, model surgery, and splint fabrication are performed, each jaw should be able to be placed into its desired position with precision. The mandibular bony cuts are made first but

terminated prior to osteotomy completion. The maxillary osteotomy is made, and the maxilla is placed into its new position using the intermediate splint. The splint is used to wire the teeth into intermaxillary fixation. The intermediate splint indexes the new position of the maxilla to the preoperative (uncorrected) position of the mandible.

Postoperative orthodontics (fig 12)

The aim of postoperative orthodontics is to bring the teeth to their final positions and secure balanced occlusion; finally retention planning should be achieved. This phase of the treatment starts two to four weeks later, after a satisfactory range of mandibular movement has been achieved and there is good bone healing. [42] (fig 13)

Case n°5

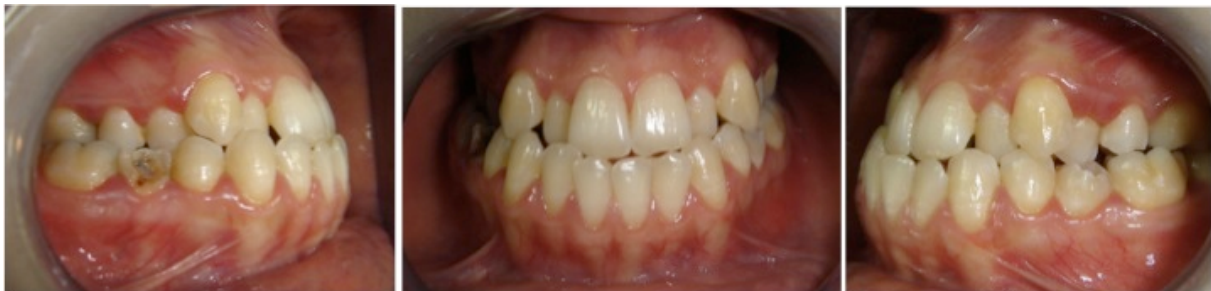

Figure 9. A patient aged 23 years presented to an aesthetic pattern with a skeletal Class III with facial asymmetry.

Clinical examination revealed anterior crossbite with a deviation of the median incisors on the right side

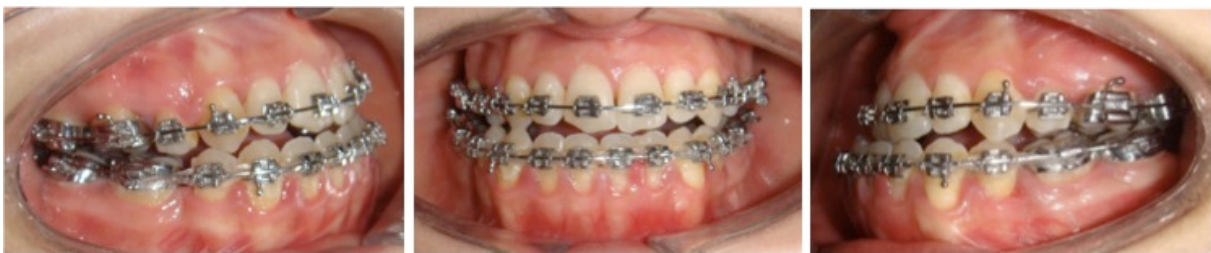

Figure 10. we opted for orthognathic surgery. Orthodontic treatment aimed to raise dental compensations with extraction: 14.24.34.44.

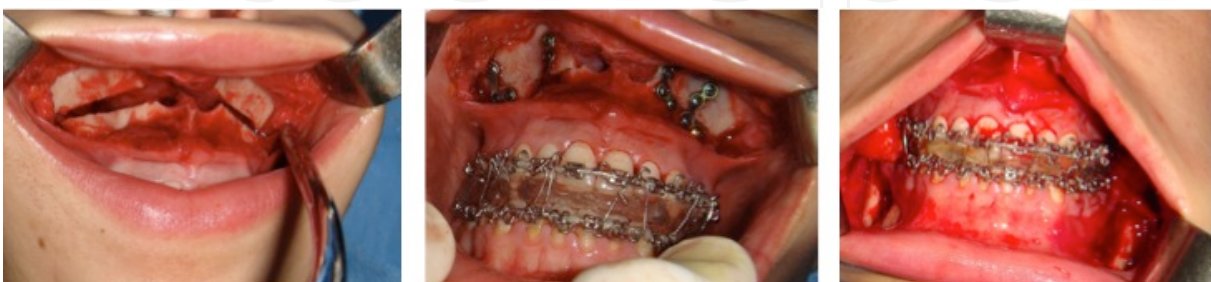


Figure 11. Orthognathic surgery consisted of an osteotomy Lefort 1 for maxillary advanced and sagittal mandibular osteotomy to go back and refocus the mandible

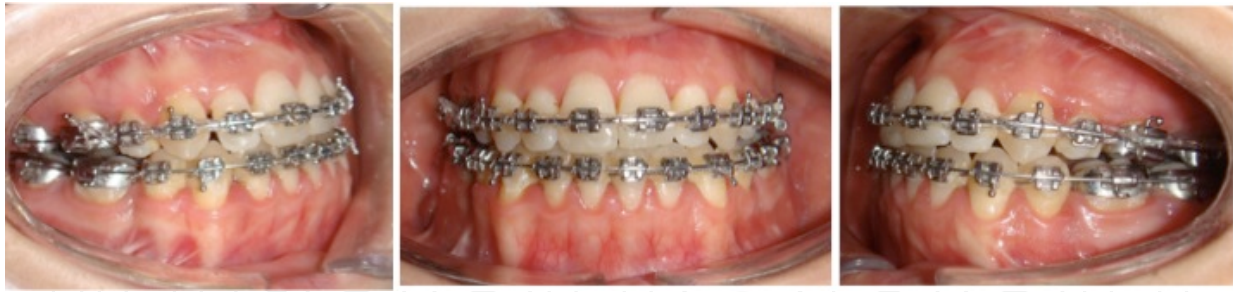

Figure 12. Some months after the surgery, orthodontic treatment is to install a good occlusion

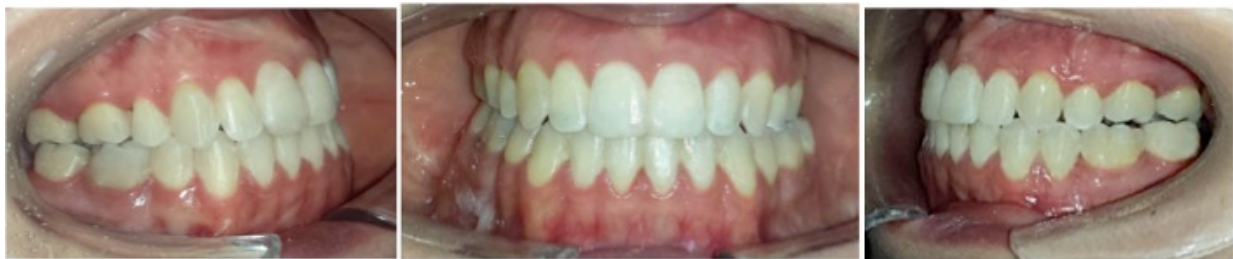

Figure 13. After 26 months, we were able to obtain a satisfactory aesthetic and functional result

6. Conclusion

Adult patients provide us the opportunity to render the greatest service possible in orthodontics. There is a great need for orthodontic treatment for the adult patient. Treating adults is a very pleasant and gratifying experience both clinically and personally [43]. Adult patients are cleaner, more careful, more punctual, prompt payers, have much less pain than youngsters, and treatment time is either the same or less than that of younger patients. Continuing education of the general public will result in an increasing demand for this type of service. The orthodontist should update his knowledge and his thinking in this aspect of his responsibility, and should try as much as possible to co-ordinate his efforts with those of his confreres in other branches of dentistry in order to render to the population a better and more complete dental health service [46]. The problems that may arise are minimal in comparison with the great results that the clinician can obtain in consistently improving the function, aesthetics, and psychological outlook of the adult patient. With the adult, diagnosis is really simpler than it is for a child. The diagnosis more or less “leaps out at you” and, sometimes, the diagnosis is even made by the patient. Treatment is sometimes more difficult for the adult, because it requires the combined expertise of a number of specialties, and growth is not on your side. Without growth and with some of the symptomatology that occurs, requiring other specialists, orthodontic treatment of adults can be more complex than treatment of the child.

Author details

Mourad Sebbar^{1*}, Nassiba Fatene², Asmaa El Mabrak², Narjisse Laslami², Zouhair Abidine¹ and Zakaria Bentahar²

*Address all correspondence to: sebbar.mourad@gmail.com

1 Hospital Moulay Abdellah, Mohammedia, Morocco

2 Department of orthodontics; Faculty of dentistry, Casablanca, Morocco

References

- [1] Fastlicht J. Adult orthodontics, *Journal of clinical orthodontics* 1982; 16 :606-618.
- [2] Thomas M Graber, Robert L Vanarsdall, Katherine W L Vig. *Orthodontic: Current principles and technique*, 4 th edition: 937-985.
- [3] Seema G, Somesh G, Deepak A. psychological aspects of orthodontic treatment. *J Ind Orthod Soc* 2001;34:92-94.
- [4] Pabari S, Mole DR, Cunninghamc SJ. Assessment of motivation and psychological characteristics of adult orthodontic patients. *Am J Orthod Dentofacial Orthop*. 2011;140(6):e263-72.
- [5] Khan RS, Horrocks EN. A study of adult orthodontic patients and their treatment. *Br J Orthod* 1991;18:183-94.
- [6] Nattrass C, Sandy JR. Adult orthodontics—a review. *Br J Orthod* 1995;22:331-7.
- [7] ZachrissonBU. Global trends and paradigm shifts in clinical orthodontics. *World J Orthod* 2005;6(Suppl):3-7.
- [8] Edgerton MT Jr, Knorr NJ. Motivational patterns of patients seeking cosmetic (esthetic) surgery. *Plast Reconstr Surg* 1971;48: 551-7.
- [9] Hagg U, Corbet EF, Rabie AM. Adult orthodontics and its interface with other discipline. *HKMJ* 1996-2: 186-90.
- [10] Shei O, Waerhaug J, Lovdal A, Arnulf A. Alveolar bone loss as related to oral hygiene and age. *J Periodontol* 1959; 26:7-16.
- [11] Cohn SA. Disuse atrophy of the periodontium in mice. *Arch Oral Biol* 1965;10(6): 909-19.
- [12] Melsen B. Tissue reaction following application of extrusive and intrusive forces to teeth in adult monkeys. *Am J Orthod* 1986;89(6):469-75.

- [13] Melsen B. Limitations in adult orthodontics. Current controversies in orthodontics. Quintessence Publishing Co 1991;147-80.
- [14] Meeran NA, Madhuri, Parveen J. The Scope and Limitations of Adult Orthodontics. Ind J Multidiscipl Dent 2011;2(1):383-387.
- [15] Kharbanda O.P. Orthodontics: Diagnosis and Management of Malocclusion and Dentofacial Deformities 2nd edition, Elsevier; 2013.
- [16] Kokich V.G, Spear F.M. Guidelines for managing the orthodontic-restorative patient. Semin Orthod 1997; 3: 3-20.
- [17] Savana K, Ansari A, Hamsa R, Kumar M, Jain A, Singh A. Interdisciplinary Therapy in Orthodontics: An Overview. Int J Advanced Health Sci | 2014 ;1(5) :23-31.
- [18] Hom BM, Turley PK. Effects of space closure of the mandibular first molar area in adults. Am J Orthod Dentofac Orthop 1984;105:25-34.
- [19] Zachrisson BU, Buyukyilmaz T. Recent advances in bonding to gold, amalgam and porcelain. J Clin Orthod 1993;27:661-75.
- [20] Forsberg CM, Brattstrom V, Malmberg E, Nord CE. Ligature wires and elastomeric rings: two methods of ligation and their association with microbial colonization of *Streptococcus mutans* and *Lactobacilli*. Eur J Orthod 1991;13:416-420.
- [21] Ong MA, Wang HL, Smith FN. Interrelationships between periodontics and adult orthodontics. J Clin Periodontol 1998;25:271-277.
- [22] Harris EF, Vaden JL, Dunn KL. Effects of patient age on post orthodontic stability in Class II, division 1 malocclusion. Am J Orthod Dentofac Orthop 1994;105:25-34.
- [23] Kahl-Nieke B. Retention and stability considerations for adult patients. Dent Clin North Am 1996;40:961-994.
- [24] Elliasson LA, Hugoson A, Kurol J, Siwe H. The effects of orthodontic treatment on periodontal tissues in patients with reduced periodontal support. Eur J Orthod 1982;4:1-9.
- [25] Boyd RL, Leggot PJ, Quinn RS, Eakle WS, Chambers DW. Periodontal implications of orthodontic treatment in adults with reduced or normal periodontal tissues versus those of adolescents. Am J Orthod Dentofac Orthop 1989;96:191-8.
- [26] Ong M A Wang HL. Periodontic and orthodontic treatment in adults. Am J Orthod Dentofac Orthop 2002;122:420-8.
- [27] Del Santo M. Periodontium and Orthodontic Implications: Clinical Applications. Int J Stomatol Res 2012, 1(3): 17-23.
- [28] Wennström JL, Stokland BL, Nyman S, Thilander B. Periodontal tissue response to orthodontic movement of teeth with infrabony pockets. Am J Orthod Dentofacial Orthop 1993;103(4):313-9.

- [29] Bagga DK. Limitations in Adult Orthodontics: A Review. *J Oral Health Comm Dent* 2009;3(3):52-55.
- [30] Slavnic S, Marcusson A. (2010). Duration of orthodontic treatment in conjunction with orthognathic surgery. *Swedish Dental Journal*, Vol. 34, No. 3, pp. 159-166, ISSN 0347-9994.
- [31] Sabri R. (2006). Orthodontic Objectives in Orthognathic surgery: state of the art today. *World Journal of Orthodontics*, Vol. 7, No. 2, pp. 177-191, ISSN 1530-5678.
- [32] Wolford LM, Stevao ELL, Alexander CM, Goncalves JR. (2004). Orthodontics for Orthognathic Surgery, In: Peterson's Principals of Oral and Maxillofacial Surgery, Miiro M, Ghali GE, Larsen PE, Waite P, pp. 1111-1134, BC Decker Inc, ISBN 1-55009-234-0, Canada.
- [33] Wolford LM. (2007). Surgical Planning in Orthognathic Surgery, In: *Maxillofacial Surgery*, Booth PW, Schendel SA, Hausamen J-E, pp. 1155-1210, Churchill Livingstone Elsevier, ISBN-13 978-0-443-10053-6, St. Louis USA.
- [34] Arnel W, McLaughlin R. Overview, treatment goals re-stated. In: *Facial and Dental Planning for Orthodontists and Oral Surgeons*. St Louis, MO: Mosby/Elsevier; 2004:2-3
- [35] Bousaba S, Siciliano S, Delatte M, Faes J, Reyckler H, Indications for orthognathic surgery, the limitations of orthodontics and of surgery, *Rev Belge Med Dent* (1984). 2002;57(1):9-23.
- [36] Tompach PC, Wheeler JJ, Fridrich KL. (1995). Orthodontic considerations in orthognathic surgery. *The International Journal of Adult Orthodontics and Orthognathic Surgery*. Vol.10, No2, pp.97-107, ISSN 0742-1931.
- [37] Slavnic S, Marcusson A. (2010). Duration of orthodontic treatment in conjunction with orthognathic surgery. *Swedish Dental Journal*, Vol. 34, No. 3, pp. 159-166, ISSN 0347-9994.
- [38] Diaz PM, Garcia RG, Gias LN, Aguirre-Jaime A, Pérez JS, de la Plata MM, Navarro EV, Gonzalez FJ. (2010). *Journal of Oral and Maxillofacial Surgery*. Vol. 68, No. 1, pp. 88-92, ISSN 0278-2391.
- [39] Jacobs JD, Sinclair PM. (1983). Principles of orthodontic mechanics in orthognathic surgery cases. *American journal of orthodontics*. Vol. 84, No 5, pp. 399-407, ISSN 0002-9416
- [40] Reyneke JP. (2003). *Essentials of Orthognathic Surgery*, Quintessence Publishing Co, ISBN 0- 86715-410-1, China
- [41] Proffit WR, Sarver DM. Treatment planning: optimizing benefit to the patient. In: Proffit WR, White RP, Sarver DM, eds. *Contemporary Treatment of Dentofacial Deformity*. St. Louis: Mosby; 2003:213–223.

- [42] Proffit WR, Sarver DM. (2003). Treatment planning: Optimizing benefit to the patient. In *Contemporary Treatment of Dentofacial Deformity*. Proffit WR, White RP, Jr, SarverDM, pp. 172-244, Mosby, ISBN 0-323-01697-9, St.Louis USA.
- [43] Robert C. Chiappone. Special considerations for Adult Orthodontics. *J clin orthod* 1976; 10 :535- 545.
- [44] Harvey L. Levitt. Adult Orthodontics. *J clin orthod* 1971; 5: 130-155.

IntechOpen

IntechOpen

