

Laparoscopic Transperitoneal Pyeloplasty*

J. Stuart Wolf, Jr., M.D., FACS

Abstract

Laparoscopic pyeloplasty is a first-line option for the management of ureteropelvic junction obstruction. It has a greater success rate than endopyelotomy and is associated with a shorter and less intense convalescence than open surgical pyeloplasty. The technique is well established and reproducible, although the procedure is more difficult in certain situations, such as after a previous pyeloplasty. Because laparoscopic suturing is needed, it is considered an advanced laparoscopic procedure. Suturing devices can facilitate suturing, but they are not optimal for all repairs. This article and the accompanying video summarize the preoperative, intraoperative, and postoperative considerations for laparoscopic pyeloplasty.

Introduction

WITH THE RECOGNITION that endopyelotomy may not have the favorable long-term results that had been expected,^{1–5} laparoscopic and robot-assisted pyeloplasty have moved to the forefront of minimally invasive alternatives to open surgical pyeloplasty. In this article, we describe our approach to laparoscopic pyeloplasty.

Indications and Contraindications

Indications for pyeloplasty include symptomatic ureteropelvic junction (UPJ) obstruction or UPJ obstruction with sequelae, such as pyelonephritis, loss of renal function, or renal calculi. Repair of an asymptomatic symptomatic UPJ obstruction that has not led to decreased renal function, infections, or stones can be considered, with the intention of preventing future problems, but it must be recognized that there are no good data on which to base this decision. There are no absolute contraindications to the laparoscopic approach to pyeloplasty except the usual surgical contraindications (untreated coagulopathy, active infections, etc.). Anticipate difficulty with the laparoscopic approach in cases of significant previous infections, intrarenal pelvis, or previous pyeloplasty. Once experience is gained, these cases can be managed laparoscopically, but they are not good choices for the novice. Previous endopyelotomy usually does not present a problem unless there has been significant urinary leakage.

Preoperative Evaluation

In addition to the usual medical evaluation, we recommend CT, MRI, or ultrasonography to assess the abdominal anatomy. A nuclear medicine renal scan is recommended to assess

renal function and drainage, unless other imaging is characteristic, ipsilateral renal function appears adequate, and the patient's symptoms are classic. Retrograde ureterography should be performed to assess ureteral and renal pelvic anatomy. This can be performed as part of the initial evaluation or at the time of intended pyeloplasty.

Preoperative Preparation

Any urinary tract infection should be treated before surgery. On the preoperative day, give the patient clear liquids and an oral magnesium citrate bowel preparation. After taking nothing by mouth for 6 hours and administering intravenous antibiotics effective against skin and genitourinary organisms, place the patient under general anesthesia with oral endotracheal intubation.

Instrumentation

- Nondisposable
 - Laparoscope, 5 mm if available, 30- or 45-degree lens
 - Video setup, light source and necessary cords
 - Surgical instruments
 - Scissors, standard and microscissors
 - Two needle holders
 - Maryland grasper
 - Bowel grasper
 - Bipolar grasper
 - Fascial closure device
 - Needle-suture passer
- Disposable
 - Laparoscopic ports, 5 and 12 mm
 - Veress needle
 - Insufflation tubing

Department of Urology, University of Michigan Health System, Ann Arbor, Michigan.

*A coordinating article with video is available in Videourology 25/1 at www.liebertonline.com/vid/doi/full/10.1089/vid.2010.0143

- Irrigator-aspirator
- Bipolar hook cautery (PKS Plasma J-Hook, Gyru-ACMI)
- Endo-stitch (Covidien, Norwalk, CT)
- Sutures
 - 4-0 Polysorb™ for Endo-stitch
 - 4-0 Vicryl™ on RB-1 for free needle suturing
- 10F round closed suction drain
- Internal ureteral stent
- Urethral catheter

Surgical Steps

Cystoscopy, retrograde ureterography, and ureteral stent placement

Perform cystoscopy and retrograde ureterography to confirm ureteral and renal pelvic anatomy. This step can be omitted if retrograde ureterography has already been performed. Alternatively, some surgeons place the stent in an antegrade fashion laparoscopically. Insert a urethral catheter for drainage.

Position for laparoscopy

Place the patient in a modified lateral decubitus position, 45 degrees from horizontal, with the ipsilateral side up. The table is flat, without flexion. Pad all pressure points well. Draw the ipsilateral arm over the chest and fix it in a neutral position.

Laparoscopic entry and port placement

We prefer the transperitoneal route to laparoscopic pyeloplasty, because it provides more room for suturing and optimal angles for transposition of the UPJ when necessary. Figure 1 illustrates our recommendation for port placement for a right-sided transperitoneal laparoscopic pyeloplasty. The midline ports are for the laparoscope (middle port) and the surgeon (working through the umbilical port and the most cephalad port). The fourth port is in a lateral position, in line with the umbilicus, for the assistant surgeon. In an obese patient, displace the ports laterally and cephalad. All ports are 5 mm initially, assuming a 5-mm laparoscope is available. The umbilical port is placed directly through the base of the umbilicus. If the Endo-stitch device is used for the repair, then upsize the umbilical port from 5 to 12 mm. If free-hand suturing is used, then an RB-1 needle bent open slightly can pass through a 5-mm port.

Insufflate through the site for the lateral 5-mm port using a Veress needle, to 15 mm Hg. After inspecting for injury, place the remaining ports. Suture the ports into place, or use ports with retention devices, unless the fascia is very tight. We anesthetize all port sites with 0.5% bupivacaine.⁶

Exposure of retroperitoneum

Reflect the colon and mesentery, staying outside the Gerota fascia until reflection is complete. Liver or splenic retraction usually is not needed. The end point is to be able to visualize the medial aspect of the lower pole of the kidney and proximal ureter without active retraction of bowel. In very obese patients, a bowel retractor may be necessary. Once bowel reflection is complete, then incise the Gerota fascia to expose the area of the UPJ.

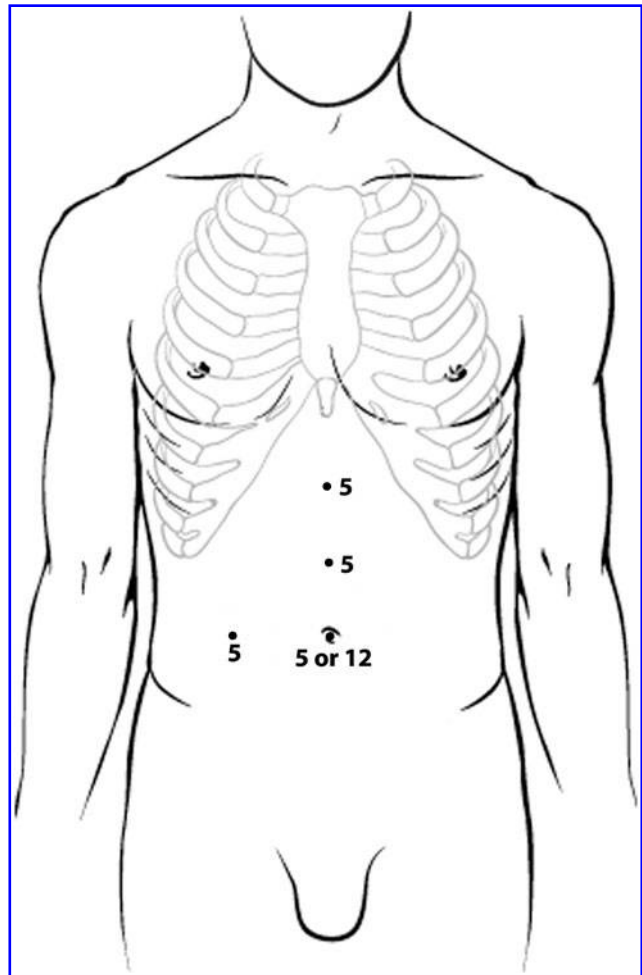


FIG. 1. Port placement for right-sided transperitoneal laparoscopic pyeloplasty.

Dissection of the UPJ

Expose the UPJ either by identifying the renal pelvis and dissecting caudally, or by identifying the ureter and proceeding cephalad. Free up the UPJ, renal pelvis, and proximal ureter from investing tissue to allow mobilization for subsequent repair. The degree of mobilization needed depends on the selected repair. Carefully preserve any crossing vessels.

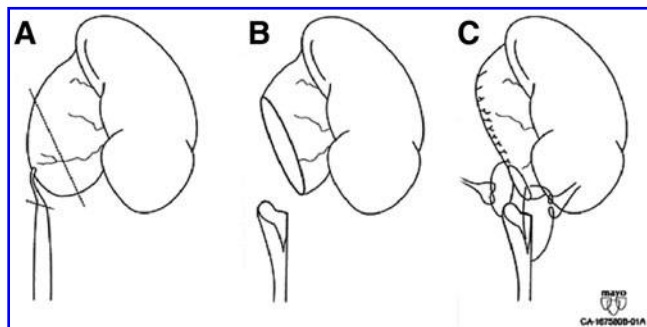


FIG. 2. Anderson-Hynes dismembered pyeloplasty. Reprinted with permission from the International Brazilian Journal of Urology.⁷

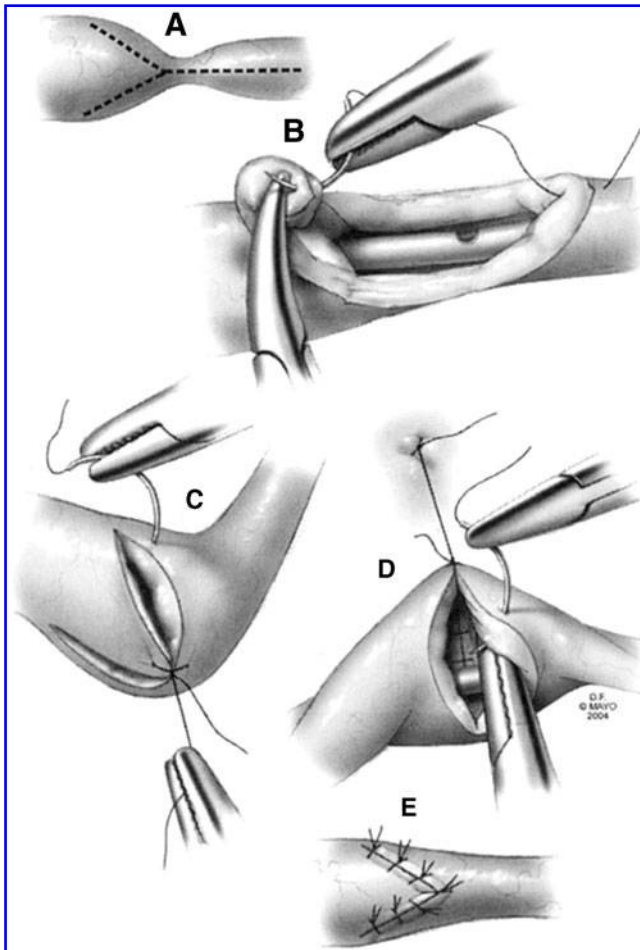


FIG. 3. Y-V plasty. Reprinted with permission from the Textbook of Laparoscopic Urology.⁸

Decide on type of repair

It is important to select the type of repair to be used before incising the UPJ. The Anderson-Hynes dismembered pyeloplasty is our standard repair (Fig. 2).⁷ This complete reconstruction of the UPJ allows transposition of the UPJ in front of any anterior crossing vessels, if present. It allows easy tapering of the renal pelvis if that is deemed necessary (although the renal pelvis can be tapered during a nondismembered repair as well). We choose a different repair only for specific reasons. If there is no crossing vessel, then a nondismembered repair can be used.

The most common nondismembered repairs are the Fengerplasty and the Y-V plasty (Fig. 3).⁸ We prefer the latter, because it has better results in our hands and can be used for long obstructed segments (Fig. 4), although it is usually applied for short obstructions. If the obstructed segment is long and the tissue cannot be mobilized enough for an Anderson-Hynes pyeloplasty or a Y-V plasty, then consider a flap pyeloplasty (Fig. 5).⁷ This repair does require a generous renal pelvis.

Vasculopexy is dissection and relocation of a vessel to a new position using sutures placed in the perivascular tissue. Along with ureterolysis, this can be the only repair in some patients,^{9–11} but more commonly it is combined with another type of repair. Finally, when small renal stones are present, they can be removed using the simple technique of laparoscopic pyelolithotomy.

In the accompanying video and in the next three sections of this article, we describe the three most common techniques used during laparoscopic pyeloplasty in our hands: the Anderson-Hynes dismembered pyeloplasty, the Y-V plasty, and laparoscopic pyelolithotomy.

Anderson-Hynes dismembered pyeloplasty

The initial incision into the renal pelvis is made with a scissors placed through the cephalad port. First, the anterior pyelotomy is created, cutting from the upper medial aspect of the renal pelvis toward the lateral corner of the UPJ, leaving enough tissue on the bottom of the renal pelvis for the

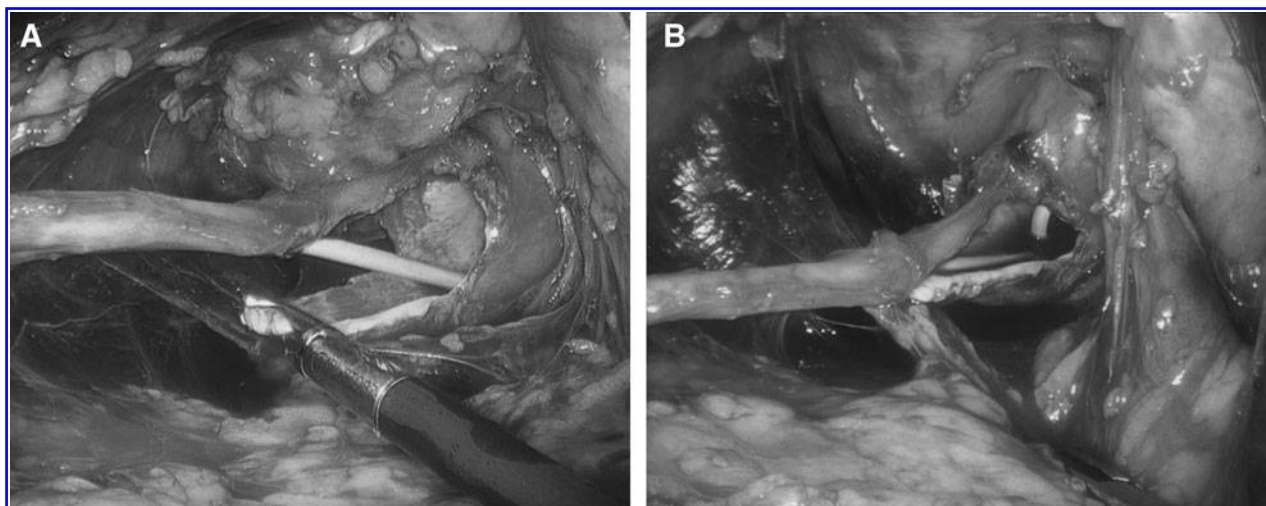


FIG. 4. Intraoperative photograph of Y-V plasty for a long obstruction. (A) Pelvic flap moved inferiorly toward apex of ureteral incision; (B) first suture tied down.

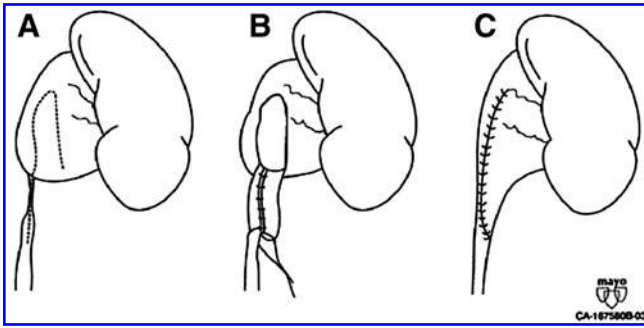


FIG. 5. Flap pyeloplasty. Reprinted with permission from the International Brazilian Journal of Urology.⁷

subsequent repair. The cephalocaudad placement of this incision determines the amount of renal pelvic tissue to be excised. If the angles allow, the lateral spatulation of the proximal ureter is performed after completing the anterior pyelotomy. The ureter is stabilized by its remaining attachment to the renal pelvis, which facilitates this step. If the spatulation cannot be performed now, then do it after completing the dismemberment. The final part of the dismemberment is creation of the posterior pyelotomy in line with the anterior pyelotomy. This completely dismembers the UPJ. Leave the flap of renal pelvic tissue that will eventually be discarded on the ureter for now; it serves as a "handle" for manipulating the ureter so that direct grasping of the ureter can be avoided. Move the renal pelvis and ureter in front of the crossing vessels (when present). Adjust the tissues until a satisfactory position of the repair is established. Additional mobilization of the proximal ureter and/or renal pelvis may be necessary.

Some urologists use only the Endo-stitch, and some use only free-needle suturing. We select one or the other based on the nature of the tissue and the type of repair. If the tissue has adequate thickness, if it is not friable, and if the ureteral lumen is adequate, then we prefer to use the Endo-stitch for the Anderson-Hynes pyeloplasty, because it makes suturing faster and easier compared with free-needle suturing, and knot-tying is greatly simplified. If any of these qualities are deficient, however, then we use free-needle suturing, because the needle is smaller and can be placed more delicately and at more angles. Currently, we use the Endo-stitch for about half of our Anderson-Hynes pyeloplasties.

Place the first suture of the Anderson-Hynes pyeloplasty outside-in at the inferior apex of the renal pelvis, and then inside-out at the inferior apex of the ureteral spatulation. The first knot is very important, because it sets up the remaining repair. A simple knot will suffice if there is no tension, but making the first throw a surgeon's knot or a slipknot will ensure good tissue coaptation. Throw this first knot with the suture anterior to the renal pelvis and then transfer the needle lateral to the ureter to move the suture to the posterior aspect of the renal pelvis (we find it easier to do the posterior aspect of the repair first). Run the suture to complete the posterior anastomosis of the spatulated ureter to the renal pelvis. The bites should be fairly close together to allow for a watertight closure. Excise the portion of the flap of pelvic tissue to be discarded. With a new suture, complete the anterior anastomosis of the spatulated ureter to the renal pelvis in a running

fashion, starting from the caudad aspect. When the upper end of the ureter is reached, the closure transitions to renal pelvis being closed to renal pelvis. If a large amount of renal pelvic tissue has been excised, then a third suture might be needed to complete the pyelotomy closure. At the completion of the repair, the renal pelvis is tapered, and the UPJ is dependent and has a funnel shape.

Y-V plasty

For the fine incisions needed for this repair, a microscissors is useful. For the typical short obstruction to which this repair is applied, make the initial incision at the anterior aspect of the UPJ right at the site of obstruction. Create the lateral arm of the "Y," starting at the initial incision and angling up toward the kidney, and then incise the medial arm of the Y, at about a 60-degree angle. The arms should be of about equal length, and for a short obstruction only need to be a centimeter or so in length. Finally, create the stem of the Y inferiorly along the anterior aspect of the ureter until healthy ureter is reached. The initial suture is placed between the apex of the ureteral incision and the tip of the renal pelvic flap. The accompanying video depicts use of the Endo-stitch device for this suturing, but currently we use free-needle suturing for Y-V plasty, because the repair is more delicate and exact than the Anderson-Hynes pyeloplasty. When the first knot is tied down, the pelvic flap is advanced into the ureteral incision, and the approximate appearance of the repair can be appreciated. Use a few additional interrupted sutures to close the lateral and medial aspects of the repair.

Laparoscopic pyelolithotomy

After making the pyelotomy and before closing the defect, insert a flexible cystoscope through a laparoscopic port and, under vision from the laparoscope, pass the tip of the cystoscope through the pyelotomy into the renal pelvis. Irrigate through the cystoscope with physiologic saline, and transfer the light source and camera to the cystoscope. Engage stones with a nitinol tiplless basket, and remove the scope and stone together out of the laparoscopic port.

Drain placement and exit

Assess the operative site for bleeding at 5 mm Hg pneumoperitoneum pressure. Close the fascia of the umbilical port if it has been upsized to 12 mm. Place a 10F round closed suction drain at the umbilical site. This site hides the more prominent scar that occurs when the skin is not closed at the drain site. A 10F round drain can fit through the fascia even if a 12-mm site has been closed. After desufflating, close the skin with sutures or wound glue, and apply sterile dressings.

Postoperative Care

Provide intravenous fluids, and advance the patient's diet as tolerated. Use parenteral ketorolac and narcotics as needed for pain control, and transition from parenteral to oral medications as tolerated. Maintain the urethral catheter to dependent drainage and the drain to bulb suction until the morning of postoperative day 2 (or postoperative day 1 if the patient is doing well and might be ready for discharge that day). Remove the urethral catheter, and remove the suction drain and discharge the patient a few hours later after the patient has

TABLE 1. RESULTS OF ADULT LAPAROSCOPIC PYELOPLASTY, SERIES OF 100 OR MORE PATIENTS

Series	No. of repairs	Route	No. of dismembered	Operative time (minutes)	% Minor complications	% Major complications	%. Conversions	Follow-up (months)	% Failure
Inagaki 2005 ¹²	147	TP	106	246	5.4%	4.1%	0	24	4.8%
Moon 2006 ¹³	170	RP	170	140	5.3%	1.8%	1.2%	12	3.8%
Rassweiler 2007 ¹⁴	143	RP	45	125	3.5%	2.1%	0.7%	63	5.6%
Yanke 2008 ¹⁵	116	TP	—	—	—	—	—	20	11%
Chuanyu 2009 ¹⁶	150	RP	150	105	—	—	0	16	2.0%
Symons 2009 ¹⁷	118	TP	94	205	12%	0	0	12	5.5%
Pouliot 2010 ¹⁸	111	TP & RP	109	128	14%	5.4%	0.9%	7.1	14%
Wagner 2010 ¹⁹	105	TP	105	150	5.7%	6.7%	0	51	3.8%
Total (weighted)	1060		779	157	7.3%	3.1%	0.4%	26.4	5.9%

TP = transperitoneal; RP = retroperitoneal.

voided and if the drain output remains low. If there is concern about urine leak, check the creatinine level on the drain fluid and do not remove the drain if urine is confirmed.

Management of Intraoperative Complications

The approach to hemostasis of the incised collecting system tissue must be very careful and deliberate. Use bipolar or ultrasonic energy to reduce risk of devascularizing the delicate collecting system. Minor oozing should be tolerated. An additional problem can arise if the initial renal pelvic incision is too cephalad, especially at the medial aspect. If the incision is too cephalad, then the bottom of the renal pelvis that is to be closed to the ureter is inadequate.

Management of Postoperative Complications

If the suction drain contains urine, reinsert the urethral catheter, and send the patient home with the drain in place. Remove the drain when output ceases. A leak for more than a week is very rare. In our experience, leaks that start more than 48 hours after surgery are also rare, but some do appear between 24 and 48 hours after surgery, which is the reason we recommend keeping the drain in place until postoperative day 2 in most cases.

Published Literature

Table 1 contains a summary of reports of laparoscopic adult pyeloplasties, including only series of more than 100 procedures.^{12–19} Series without adequate reported follow-up are excluded. In the more than 1000 procedures reported, performed using both transperitoneal and retroperitoneal approaches but with mostly dismembered repairs, the minor and major complication rates are acceptable at 7.3% and 3.1%, respectively. The conversion rate is low at 0.4%. With a mean follow-up of 26.4 months, the failure rate is only 5.9%. The definition of success varies from study to study, and in general, the reports with the most stringent definition of success have greater failure rates.

Summary

Laparoscopic pyeloplasty is a mature surgical procedure with extensive worldwide experience. Results are generally excellent, although the procedure is more difficult in certain situations. Because laparoscopic suturing is needed, this is

considered an advanced procedure. Although the Endo-stitch device does facilitate suturing, it is not optimal for all repairs. Laparoscopic pyeloplasty is a first-line option for the management of UPJ obstruction.

Disclosure Statement

No competing financial interests exist.

References

- Knudsen BE, Cook AJ, Watterson JD, et al. Percutaneous antegrade endopyelotomy: Long-term results from one institution. *Urology* 2004;63:230–234.
- Weikert S, Christoph F, Müller M, et al. Acucise endopyelotomy: A technique with limited efficacy for primary ureteropelvic junction obstruction in adults. *Int J Urol* 2005;12:864–868.
- Dimarco DS, Gettman MT, McGee SM, et al. Long-term success of antegrade endopyelotomy compared with pyeloplasty at a single institution. *J Endourol* 2006;20:707–712.
- Dobry E, Usai P, Studer UE, Danuser H. Is antegrade endopyelotomy really less invasive than open pyeloplasty? *Urologia Int* 2007;79:152–156.
- Szydełko T, Kopec R, Kasprzak J, et al. Antegrade endopyelotomy versus laparoscopic pyeloplasty for primary ureteropelvic junction obstruction. *J Laparoendosc Adv Surg Tech A* 2009;19:45–51.
- Khaira HS, Wolf JS Jr. Intraoperative local anesthesia decreases postoperative parenteral opioid requirements for transperitoneal laparoscopic renal and adrenal surgery: A randomized, double-blind, placebo controlled investigation. *J Urol* 2004;172:1422–1426.
- Kausik S, Segura JW. Surgical management of ureteropelvic junction obstruction in adults. *Int Braz J Urol* 2003;29:3–10.
- Chow GK. Laparoscopic pyeloplasty: Technique. In: Gill IS, ed. *Textbook of Laparoscopic Urology*. New York: Informa Healthcare, 2006, pp. 295–302.
- Meng MV, Stoller ML. Hellström technique revisited: Laparoscopic management of ureteropelvic junction obstruction. *Urology* 2003;62:404–408.
- Nouralizadeh A, Simforoosh N, Basiri A, et al. Laparoscopic management of ureteropelvic junction obstruction by division of the aberrant vein and cephalad relocation of the crossing artery: A long-term follow-up of 42 cases. *J Endourol* 2010;24:987–991.
- Schuster TK, Jacobs BL, Gayed BA, Averch TD. Preliminary experience with laparoscopic ureteropelvic junction release

- in the treatment of ureteropelvic junction obstruction. *J Endourol* 2010;24:393–396.
12. Inagaki T, Rha KH, Ong AM, et al. Laparoscopic pyeloplasty: Current status. *BJU Int* 2005;95(suppl 2):102–105.
 13. Moon DA, El-Shazly MA, Chang CM, et al. Laparoscopic pyeloplasty: Evolution of a new gold standard. *Urology* 2006;67:932–936.
 14. Rassweiler JJ, Subotic S, Feist-Schwenk M, et al. Minimally invasive treatment of ureteropelvic junction obstruction: Long-term experience with an algorithm for laser endopyelotomy and laparoscopic retroperitoneal pyeloplasty. *J Urol* 2007;177:1000–1005.
 15. Yanke BV, Lallas CD, Pagnani C, et al. The minimally invasive treatment of ureteropelvic junction obstruction: A review of our experience during the last decade. *J Urol* 2008;180:1397–1402.
 16. Chuanyu S, Guowei X, Ke X, et al. Retroperitoneal laparoscopic dismembered Anderson-Hynes pyeloplasty in treatment of ureteropelvic junction obstruction (report of 150 cases). *Urology* 2009;74:1036–1040.
 17. Symons SJ, Bhirud PS, Jain V, et al. Laparoscopic pyeloplasty: Our new gold standard. *J Endourol* 2009;23:463–467.
 18. Pouliot F, Lebel MH, Audet J-F, Dujardin T. Determination of success by objective scintigraphic criteria after laparoscopic pyeloplasty. *J Endourol* 2010;24:299–304.
 19. Wagner S, Greco F, Inferrera A, et al. Laparoscopic dismembered pyeloplasty: Technique and results in 105 patients. *World J Urol* 2010;28:615–618.

Address correspondence to:

J. Stuart Wolf, Jr., M.D., FACS
Department of Urology
University of Michigan Health System
1500 East Medical Center Drive, TC 3875
Ann Arbor, MI 48109-5330

E-mail: wolfs@umich.edu

Abbreviations Used

CT = computed tomography
 MRI = magnetic resonance imaging
 UPJ = ureteropelvic junction

This article has been cited by:

1. Stilianos Giannakopoulos , Ioannis Efthimiou , Athanasios Bantis , Christos Kalaitzis , Stavros Touloupidis . A Simplified Technique for Ureteral Spatulation in Laparoscopic Pyeloplasty. *Journal of Endourology*, ahead of print. [\[Abstract\]](#) [\[Full Text\]](#) [\[PDF\]](#) [\[PDF Plus\]](#)