

ARP Case Report n° 17: What is your diagnosis?

Caso Clínico ARP n° 17: Qual o seu diagnóstico?

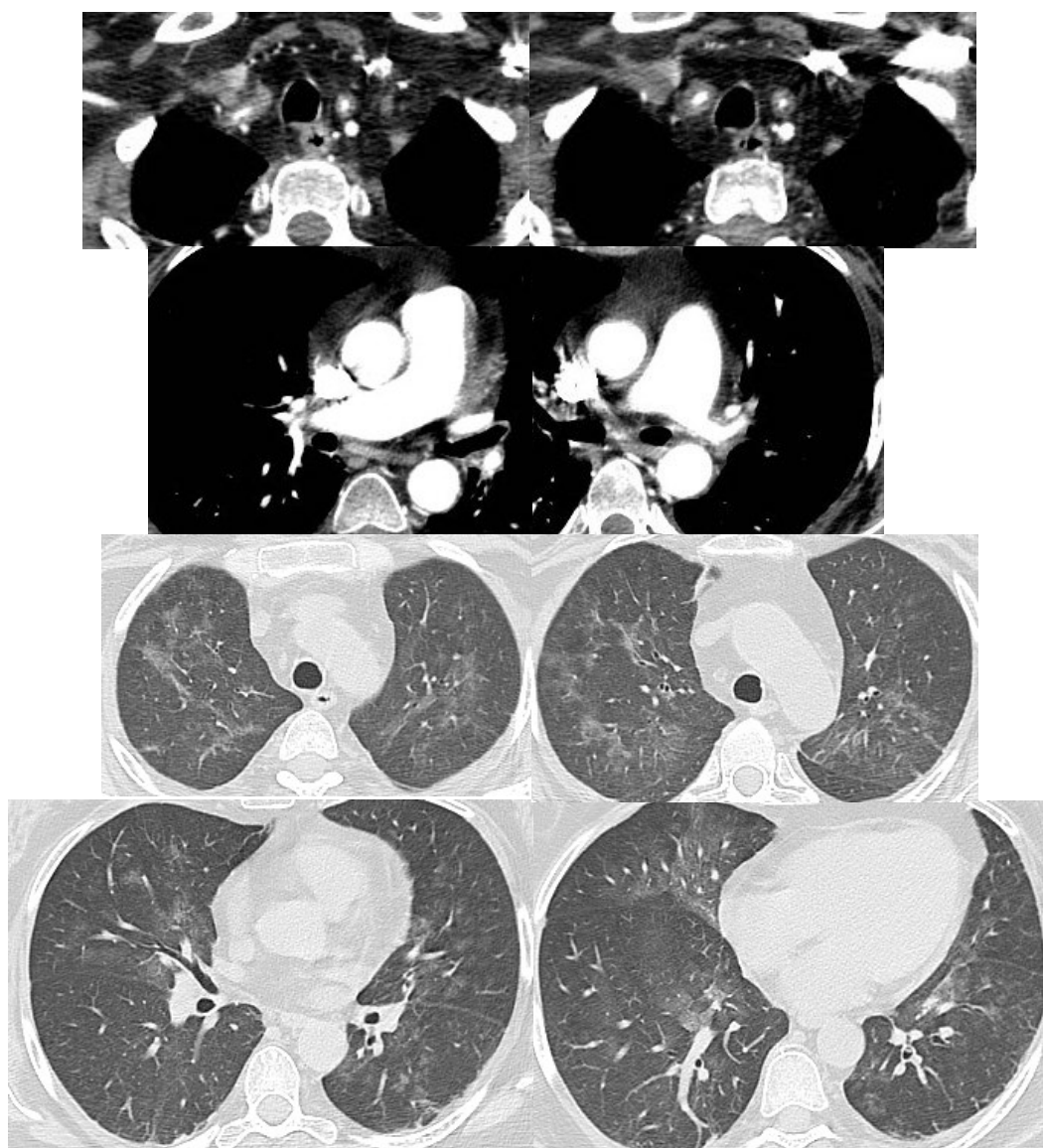
Margarida Ferreira, Nuno Neves

Department of Radiology, Infante D. Pedro Hospital (CHBV), Aveiro, Portugal

Presentation of the Case

39 year old female, presenting at ER with aphasia and right hemiparesis. A few hours later, develops mild hemoptysis. Thoracic CT performed to exclude pulmonary

embolism. Patient taking immunosuppressants for suspected demyelinating disease (multiple sclerosis?), due to relapsing-remitting but progressive episodes of limb weakness and numbness and impaired and blurred vision.



Send your answer containing the diagnosis (s) to the email address actarp.on@gmail.com.
The names of the authors of the correct answers will be published in the next issue of the ARP in the case solution.