

## Caso Clínico / Radiological Case Report

**Acenocoumarol-Related Fatal in-Utero Subdural Hematoma***Hematoma Subdural Fatal in-Utero, Secundário a Terapêutica com Acenocoumarol*Mariana C. Diogo<sup>1</sup>, Cláudia Rijo<sup>2</sup>, Álvaro Cohen<sup>2</sup>, Carla Conceição<sup>1</sup>

<sup>1</sup> Department of Neuroradiology, Hospital Dona Estefânia, Centro Hospitalar de Lisboa Central, Lisboa, Portugal

<sup>2</sup> Gynecology and Obstetrics Department, Maternidade Alfredo da Costa, Centro Hospitalar de Lisboa Central, Lisboa, Portugal

**Correspondência**

Mariana Cardoso Diogo  
Departamento de Neuroradiologia  
Hospital Dona Estefânia, Centro Hospitalar de Lisboa Central  
Rua José António Serrano,  
1150 - Lisboa  
Portugal  
e-mail: mariana\_cdiogo@hotmail.com

**Abstract**

Fetal intracranial hemorrhages are typical of the germinal matrix, associated with fetal or placental problems. Subdural hemorrhages in utero are extremely rare but have been reported in coagulation disorders or maternal trauma. We present a case of atraumatic subdural hematoma in a 35 gestational week fetus, whose mother was under oral anticoagulation for prosthetic mitral valve. The mother complained of reduced fetal movement and ultrasound was inconclusive. Fetal magnetic resonance imaging (MRI) was performed the following day. MRI revealed an extensive subdural hematoma involving both hemispheric convexities and the tentorium, with significant mass effect. No heartbeat was detected in an US performed 1 day after MRI. Autopsy confirmed the diagnosis. To our knowledge it is the most extensive acenocoumarol-related in-utero SDH reported, and an excellent example of how fetal MRI might aid in prenatal diagnosis of fetal hemorrhagic complications.

**Key-words**

Fetal MRI; Subdural hematoma;  
Anticoagulation; Mechanic heart valve;  
Acenocoumarol.

**Resumo**

Apresentamos o caso de um hematoma subdural traumático num feto de 35 semanas de gestação, cuja mãe se encontrava sob terapêutica anticoagulante com acenocoumarol, devido a prótese mitral mecânica. A ecografia, realizada às 35 semanas de gestação por redução dos movimentos fetais, revelou aumento do espaço intracraniano extracerebral e provável malformação cortical. RM fetal efetuada no dia seguinte revelou extenso hematoma subdural hemisférico bilateral, com sinais de atividade e significativo efeito de massa. Ecografia de controlo detetou ausência de batimentos cardíacos fetais e autópsia confirmou o diagnóstico. Tanto quanto nos foi possível averiguar, este é o mais extenso caso de HSD fetal relacionado com a toma de acenocoumarol descrito em RM fetal e um excelente exemplo da utilidade desta técnica no diagnóstico pré-natal de lesões hemorrágicas.

**Palavras-chave**

Ressonância magnética fetal; Hematoma subdural; Anticoagulação; Válvula mecânica; Acenocoumarol.

**Introduction**

Subdural hematoma (SDH) is a frequent finding in newborns, usually occurring during traumatic vaginal delivery. On the other hand, antenatal SDH is exceptional.<sup>1</sup> It may occur spontaneously or in association with various maternal or fetal conditions including trauma, coagulopathies, intrauterine infections and iatrogenic effect of maternal drug intake.<sup>2</sup> Vitamin K antagonists cross the placental barrier and are associated with coumarin embryopathy, characterized by nasal hypoplasia and/or stippled epiphyses, when exposure occurs in the first trimester, while exposure in the second or third trimesters is associated with central nervous system (CNS) malformations or hemorrhagic complications.<sup>3,4</sup>

We present a rare case of extensive, acenocoumarol-associated, subdural hematoma occurring in the third trimester, emphasizing the importance of anticoagulation as a cause of antenatal intracranial bleeding and the major role played by fetal magnetic resonance imaging (MRI) in diagnosing fetal hemorrhagic.

**Case Report**

A 24-year-old woman under life-long oral anticoagulation after mitral valve replacement at the age of 13, due to rheumatic valve disease, presented to her attending physician with a six weeks and four days pregnancy. She had 3 previous failed pregnancies: the first was complicated by warfarin embryopathy and medically interrupted at 24 weeks of gestation; the following two gestations resulted in spontaneous abortions at 9 and 16 weeks, without known cause and no clear fetal anomalies at pathological analysis. She also suffered deep vein thrombosis (DVT) of the left leg during the 2<sup>nd</sup> pregnancy (at 10 weeks of gestation), while under treatment with enoxaparin (60 mg twice daily) and mechanic valve thrombosis at the age of 16, with need for emergency prosthesis replacement.

Due to the high risk and history of thrombotic events it was decided to maintain therapy with acenocoumarol (4 mg daily) throughout the gestation. International Normalization Ratio (INR) values were measured every 15 days (kept between 2,3 and 3,2) and fetal ultrasound (US)

scans performed every 2-3 weeks. There was no evidence of intracranial abnormalities, fetal or maternal bleeding.

At 35 weeks of gestation, routine US scan showed enlargement of the extracerebral space with abnormal morphology of the cerebral convexities, suggesting a simplified gyral pattern. Fetal MRI, performed the following day, revealed extensive bilateral subdural collections, involving cerebral convexities and extending to the tentorium. They presented heterogeneous signal (Fig. 1) mainly hyperintense on T2 weighted images (WI) and “blooming” on gradient-echo T2\*WI (Fig. 2), but with areas of mixed low and high T2 signal (primarily on the right side), suggesting hemorrhagic collections with signs of active bleeding (Fig.1). The SDH had right side predominance and significant mass effect: generalized effacement of cerebral sulci, cisternal spaces and right lateral ventricle, midline shift to the left and cerebellar amygdalae herniation. It was not possible to identify any cortical malformations due to distortion of encephalic parenchyma.

Acenocoumarol was immediately discontinued and replaced with enoxaparin, but one day later US confirmed fetal death. Pathological study confirmed the presence of moderate intracranial SDH, with small subarachnoid hematic

component in the posterior fossa. Hemorrhagic foci of the thymus gland were also identified. No malformations of the CNS nor were associated skeletal anomalies identified.

## Discussion

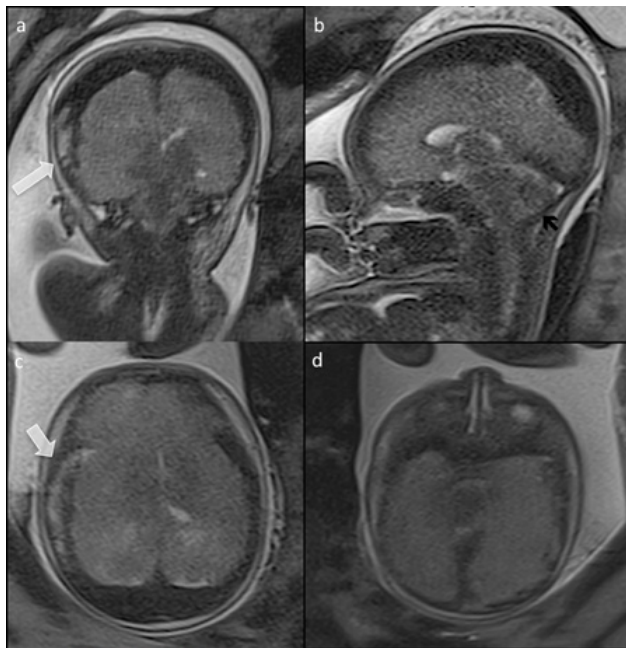
The fatal antenatal SDH presented was most presumed secondary to anticoagulant exposure, given the maternal history of acenocoumarol intake (INR at admission: 2,9), the lack of other predisposing factors, and the absence of abnormal findings in the previous US scans. The decision to maintain anticoagulation throughout pregnancy was based on maternal history of serious thrombotic events (DVT and valve thrombosis), one of which occurred during a previous gestation.

Anticoagulation during pregnancy is a known risk factor for both mother and fetus. Vitamin K antagonists cross the placenta and increase risk of spontaneous abortion, embryopathy and fetal hemorrhage,<sup>4</sup> and although heparin does not cross the placental barrier, it considerably increases the thrombotic risk for the mother.<sup>3</sup> The use of coumarins throughout pregnancy can be justified if the risk of maternal thrombotic events outweighs the risk of fetal complications, with a known incidence of hemorrhage of 2.5% (80% occurring at delivery) and the incidence of valve thrombosis approximately 4% (higher if heparin is used).<sup>3,5</sup>

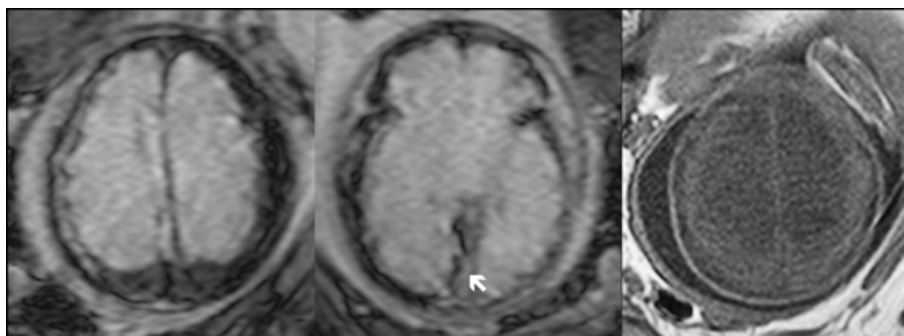
On US, diagnosis of SDH is often difficult and asymptomatic enlargement of the cranial dimensions may be the only finding. In our case US findings were nonspecific and a cortical malformation suspected, due to the loss of the normal external cerebral architecture. With the advent of ultrafast MRI techniques, it is now possible to obtain clear images of the fetus and this imaging method proved essential to our diagnosis as it provided a clear image of the location and extent of the hemorrhage and its secondary effects.

## Conclusion

Anticoagulant-associated fetal hemorrhage is a rare but severe event. Unfortunately, there is no alternative regimen that can effectively replace vitamin K antagonists in women with mechanical heart valves during late pregnancy. Although US studies are valuable for regular monitoring of fetal hemorrhagic complications, in suspicious cases MRI offers a more detailed assessment of fetal CNS and provides a better characterization of both hemorrhagic and malformative pathology.



**Figure 1** – Fetal MRI. 35-week-old fetus. Coronal (a), sagittal (b) and axial (c, d) T2WI. Subdural hematoma and loss of differentiation of cerebral parenchyma. The SDH is hypointense with area of mixed signal (white arrow) on the right, suggesting active bleeding. There is herniation of the amygdalae (black arrow)



**Figure 2** – Axial GET2\*WI (a,b) and T1WI (c). The subdural hematoma shows “blooming” on T2\* and extends into the tentorium on the right (white arrow) is slightly hyperintense on T1WI.

---

**Recebido / Received** 30/11/2016

**Aceite / Acceptance** 17/01/2017

#### **Divulgações Éticas / Ethical disclosures**

*Conflitos de interesse:* Os autores declaram não possuir conflitos de interesse.

*Conflicts of interest:* The authors have no conflicts of interest to declare.

*Suporte financeiro:* O presente trabalho não foi suportado por nenhum subsídio ou bolsa.

*Financing Support:* This work has not received any contribution, grant or scholarship.

*Confidencialidade dos dados:* Os autores declaram ter seguido os protocolos do seu centro de trabalho acerca da publicação dos dados de doentes.

*Confidentiality of data:* The authors declare that they have followed the protocols of their work center on the publication of data from patients.

*Proteção de pessoas e animais:* Os autores declaram que os procedimentos seguidos estavam de acordo com os regulamentos estabelecidos pelos responsáveis da Comissão de Investigação Clínica e Ética e de acordo com a Declaração de Helsínquia da Associação Médica Mundial

*Protection of human and animal subjects:* The authors declare that the procedures followed were in accordance with the regulations of the relevant clinical research ethics committee and with those of the Code of Ethics of the World Medical Association (Declaration of Helsinki).

#### **References**

1. Akman CI, Cracco J. Intrauterine subdural hemorrhage. *Dev Med & Child Neurol.* 2000;42:843-6.
2. Sherer DM, Anyaegbunam A, Onyeije C. Antepartum fetal intracranial hemorrhage, predisposing factors and prenatal sonography: a review. *Am J Perinatol.* 1998;15:431-41.
3. Chan WS, Anand S, Ginsberg JS. Anticoagulation of pregnant women with mechanical heart valves: a systematic review of the literature. *Arch Intern Med.* 2000;160:191-6.
4. Raghav S, Reutens D. Neurological sequelae of intrauterine warfarin exposure. *J Clin Neurosc.* 2007;14:99-103.
5. Stefanidis K, Papoutsis D, Daskalakis G, Loutradis D, Antsaklis A, Acenocoumarol and pregnancy outcome in a patient with mitral valve prosthesis: a case report. *Fetal Diagn Ther.* 2009;25:115-8.
6. Vitale N, De Feo M, Santo LS, Pollice A, Tadesco N, Cotrufo M. Dose-dependent fetal complications of warfarin in pregnant women with mechanical heart valves. *J Am Coll Cardiol.* 1999;33:1637-41.