



**UNIVERSIDADE ESTADUAL DE CAMPINAS
FACULDADE DE ODONTOLOGIA DE PIRACICABA**

JOÃO PAULO MENCK SANGIORGIO

**RETALHO POSICIONADO CORONARIAMENTE ASSOCIADO A MATRIZ
DE COLÁGENO XENÓGENA E/OU MATRIZ DERIVADA DO ESMALTE
PARA O TRATAMENTO DE RECESSÕES UNITÁRIAS:
ENSAIO CLÍNICO RANDOMIZADO**

**CORONALLY ADVANCED FLAP ASSOCIATED WITH XENOGENOUS
COLLAGEN MATRIX GRAFT AND/OR ENAMEL MATRIX DERIVATIVE
FOR TREATMENT OF LOCALIZED RECESSION-TYPE DEFECTS:
A RANDOMIZED CLINICAL TRIAL**

Piracicaba

2017

JOÃO PAULO MENCK SANGIROGIO

**RETALHO POSICIONADO CORONARIAMENTE ASSOCIADO A MATRIZ
DE COLÁGENO XENÓGENA E/OU MATRIZ DERIVADA DO ESMALTE
PARA O TRATAMENTO DE RECESSÕES UNITÁRIAS:
ENSAIO CLÍNICO RANDOMIZADO**

**CORONALLY ADVANCED FLAP ASSOCIATED WITH XENOGENOUS
COLLAGEN MATRIX GRAFT AND/OR ENAMEL MATRIX DERIVATIVE
FOR TREATMENT OF LOCALIZED RESSION-TYPE DEFECTS:
A RANDOMIZED CLINICAL TRIAL**

Tese apresentada à Faculdade de Odontologia de Piracicaba da Universidade Estadual de Campinas como parte dos requisitos exigidos para a obtenção do título de Doutor em Clínica Odontológica, na Área de Periodontia.

Thesis presented to the Piracicaba Dental School of the University of Campinas in partial fulfillment of the requirements for the degree of Doctor in Dental Clinics, in Periodontics area.

Orientador: Prof. Dr. Enilson Antônio Sallum

ESTE EXEMPLAR CORRESPONDE À VERSÃO
FINAL DA TESE DEFENDIDA PELO ALUNO
JOÃO PAULO MENCK SANGIORGIO E
ORIENTADA PELO PROF. DR. ENILSON
ANTONIO SALLUM

Piracicaba

2017

Agência(s) de fomento e nº(s) de processo(s): FAPESP, 2013/19473-6; CAPES
ORCID: <http://orcid.org/http://orcid.org/ht>

Ficha catalográfica
Universidade Estadual de Campinas
Biblioteca da Faculdade de Odontologia de Piracicaba
Marilene Girello - CRB 8/6159

Sa58r Sangiorgio, Joao Paulo Menck, 1987-
Retalho posicionado coronariamente associado a matriz de colágeno xenógena e/ou matriz derivada do esmalte para o tratamento de recessões unitárias : ensaio clínico randomizado / João Paulo Menck Sangiorgio. – Piracicaba, SP : [s.n.], 2017.

Orientador: Enilson Antonio Sallum.

Tese (doutorado) – Universidade Estadual de Campinas, Faculdade de Odontologia de Piracicaba.

1. Retração gengival. 2. Colágeno. 3. Proteínas do esmalte dentário. I. Sallum, Enilson Antonio, 1968-. II. Universidade Estadual de Campinas. Faculdade de Odontologia de Piracicaba. III. Título.

Informações para Biblioteca Digital

Título em outro idioma: Coronally advanced flap associated with xenogenous collagen matrix graft and/or enamel matrix derivative for treatment of localized recession-type defects : a randomized clinical trial

Palavras-chave em inglês:

Gingival recession

Collagen

Dental enamel proteins

Área de concentração: Periodontia

Titulação: Doutor em Clínica Odontológica

Banca examinadora:

Enilson Antonio Sallum [Orientador]

Wilson Trevisan Júnior

Fernanda Vieira Ribeiro

Márcio Zaffalon Casati

Karina Gonzales Silvério Ruiz

Data de defesa: 21-02-2017

Programa de Pós-Graduação: Clínica Odontológica



UNIVERSIDADE ESTADUAL DE CAMPINAS
Faculdade de Odontologia de Piracicaba



A Comissão Julgadora dos trabalhos de Defesa de Tese de Doutorado, em sessão pública realizada em 21 de Fevereiro de 2017, considerou o candidato JOÃO PAULO MENCK SANGIORGIO aprovado.

PROF. DR. ENILSON ANTONIO SALLUM

PROF. DR. WILSON TREVISAN JÚNIOR

PROF^a. DR^a. FERNANDA VIEIRA RIBEIRO

PROF. DR. MÁRCIO ZAFFALON CASATI

PROF^a. DR^a. KARINA GONZALES SILVÉRIO RUIZ

A Ata da defesa com as respectivas assinaturas dos membros encontra-se no processo de vida acadêmica do aluno.

DEDICATÓRIA

Ao Jean e à Sara Maria, meus pais, exemplos de coragem, honestidade, perseverança, temor e amor. Pelo investimento interminável em meu caráter, em minha fé e minha formação.

AGRADECIMENTOS

À **Deus**, presente em todos os momentos e em todos os caminhos. A certeza de que me conduz, mesmo quando não sei mais por onde andar.

À **Universidade Estadual de Campinas**, por meio do seu Magnífico Reitor, Prof. Dr. José Tadeu Jorge.

À **Faculdade de Odontologia de Piracicaba**, por meio do seu Diretor, Prof. Dr. Guilherme Elias Pessanha Henriques.

À **Prof^a. Dra. Cíntia Pereira Machado Tabchoury**, Coordenadora dos Cursos de Pós-Graduação, e à **Prof^a. Dra. Karina Gonzales Silvério Ruiz**, Coordenadora do Curso de Pós-Graduação em Clínica Odontológica.

Ao Prof. Dr. **Enilson Antônio Sallum**, pelo os exemplos de competência, profissionalismo e orientação que demonstrou para comigo durante esses últimos anos.

Aos professores **Prof. Dr. Antônio Wilson Sallum**, **Prof. Dr. Márcio Zaffalon Casati**, **Prof. Dr. Francisco Humberto Nociti Júnior**, **Prof. Dr. Renato Corrêa Viana Casarin**, **Prof^a. Dra. Karina Gonzales Silvério Ruiz**, essenciais à minha formação. Por tanto contribuírem para o meu crescimento profissional.

Ao **Prof. Dr. Mauro Pedrine Santamaria**, responsável pelo desenvolvimento deste trabalho na Universidade Estadual Paulista, campus de São José dos Campos.

Ao **Prof. Dr. Wilson Trevisan Jr.** Grande mestre. Grande amigo. Por todas as oportunidades que tanto contribuíram para minha formação.

Às valiosas **Regina Caetano**, **Mariana Fugolim e Eliete Marim** e a todos os funcionários da clínica de graduação e pós-graduação da Faculdade de Odontologia de Piracicaba, que sempre estiveram tão dispostos a nos ajudar e tornaram nossos dias um pouco mais simples. Obrigado por tudo.

Aos **voluntários** que participaram desta pesquisa, pela cooperação e dedicação.

Às amigas **Isabela Lima França Grohmann e Manuela Rocha Santos**, pela amizade, companheirismo, e pela imensurável ajuda durante todo o doutorado.

Aos amigos, colegas e ex-colegas de pós-graduação. Pela honra de terem compartilhado momentos de alegrias, sucessos e frustrações. Obrigado por tantos ensinamentos, pela convivência e pela amizade.

À minha esposa, **Jéssica Amaro de Souza Sangiorgio**, companheira *da sempre, per sempre*. Obrigado por todo amor, compreensão e paciência.

À CAPES (Coordenação de Aperfeiçoamento de Pessoal de Nível Superior) pela concessão da bolsa durante todo o período de realização deste doutorado.

À Fundação de Amparo à Pesquisa do Estado de São Paulo (FAPESP) pelo financiamento do projeto nº 19473-6/2013.

RESUMO

O objetivo deste ensaio clínico controlado, randomizado, duplo cego, foi comparar os resultados clínicos do tratamento de recessões gengivais utilizando retalho posicionado coronariamente (RPC) combinado com enxerto de matriz de colágeno de origem suína (MC) e/ou proteínas da matriz do esmalte (EMD). Foram selecionados 68 pacientes com recessões gengivais Classe I ou II de Miller ≥ 3 mm, em caninos ou pré-molares superiores.. Os defeitos foram aleatoriamente designados para o grupo RPC (n=17); RPC+MC (n=17); RPC+EMD (n=17) ou RPC+MC+EMD (n=17). Os parâmetros clínicos avaliados foram profundidade de sondagem, nível de inserção clínico, altura da recessão gengival, altura e espessura de tecido queratinizado e estética. As medidas clínicas foram tomadas imediatamente antes da cirurgia, 3 e 6 meses após as cirurgias. O recobrimento médio obtido foi de $68,04 \pm 24,11\%$ para RPC; $87,20 \pm 15,01\%$ para RPC+MC; $88,77 \pm 20,66\%$ para RPC+EMD e $91,59 \pm 11,08\%$ para RPC+MC+EMD após 6 meses, com resultados superiores para os biomateriais ($p < 0,05$). Recobrimento completo foi conseguido em 70,59% dos casos tratados com EMD, enquanto apenas 23,53% no RPC; 52,94% no MC e 51,47% para MC+EMD ($p < 0,05$). Ao final do estudo, o ganho na espessura de tecido queratinizado foi maior para os grupos com MC ($p < 0,05$). Todos tratamentos apresentaram melhora na avaliação estética dos profissionais ($p < 0,05$). Dentro dos limites do presente estudo pôde-se concluir que a associação de RPC com MC, EMD ou MC+EMD proporcionou resultados superiores em relação a redução da recessão quando comparados a RPC ($p < 0,05$), mas sem diferença entre os biomateriais. A utilização do EMD obteve maior porcentagem de recobrimento completo e o uso do MC permitiu maior ganho de espessura gengival quando comparado ao baseline.

Palavras-chave: Retração gengival/cirurgia. Colágeno/uso terapêutico. Proteínas do esmalte dentário/uso terapêutico.

ABSTRACT

The aim of this double blind, randomized, controlled clinical trial, was to evaluate the clinical outcomes after the treatment of gingival recession with the coronally advanced flap (CAF) combined to a porcine collagen matrix graft (CM) and/or enamel matrix derivative (EMD). Sixty eight patients with Miller Class I or II gingival recessions ≥ 3 mm in canines or superior premolars were selected. The defects were randomly assigned to the CAF group (n = 17); CAF + CM (n = 17); CAF + EMD (n = 17) or CAF + CM + EMD (n = 17). The clinical parameters evaluated were probing depth, clinical attachment level, gingival recession height, width and thickness of keratinized tissue and aesthetics. Clinical measurements were taken at *baseline*, 3 and 6 months after surgery. The mean percentage of root coverage was $68.04 \pm 24.11\%$ for CAF; $87.20 \pm 15.01\%$ for CAF + CM; $88.77 \pm 20.66\%$ for CAF + EMD and $91.59 \pm 11.08\%$ for CAF + CM + EMD after 6 months, with superior results for biomaterials ($p < 0.05$). Complete root coverage was achieved in 70.59% of the cases treated with EMD, and only in 23.53% for CAF; 52.94% for CAF+CM and 51.47% for CAF+CM + EMD ($p < 0.05$). At the end of the study, the gain in keratinized tissue thickness was higher for the CM groups ($p < 0.05$). All treatments presented a significant increase in professional aesthetic evaluation ($p < 0.05$). Within the limits of the present study it was concluded that the association of CAF with CM, EMD or CM + EMD provides superior results for recession reduction when compared to CAF alone ($p < 0.05$), but with no difference among biomaterials. The use of EMD obtained higher percentage of complete root coverage, and the use of CM obtained superior gain of gingival thickness when compared to baseline.

Keywords: Gingival retraction / surgery. Collagen / therapeutic use. Dental Enamel Proteins / therapeutic use.

SUMÁRIO

1	INTRODUÇÃO	11
2	ARTIGO:.....	13
	Xenogenous collagen matrix and/or enamel matrix derivative for treatment of localized gingival recessions - a randomized clinical trial. Part I: primary outcome.	13
3	CONCLUSÃO	38
	REFERÊNCIAS	39
	Anexos.....	42
	Anexo 1: Comprovante de submissão do artigo.....	42
	Anexo 2: Comitê de Ética	43

1 INTRODUÇÃO

Na busca de resultados mais previsíveis e eficazes, a odontologia tem buscado desenvolver diferentes tratamentos para atender às queixas de pacientes cada vez mais exigentes em relação a presença de recessões gengivais e suas consequências estéticas e funcionais, como hipersensibilidade radicular e lesões cervicais cariosas ou não cariosas (Cairo et al. 2016; Cairo et al. 2014).

Visando ao tratamento dessa condição, diversas técnicas já foram desenvolvidas para alcançar cobertura da raiz com maior previsibilidade e efetividade (Buti et al. 2013; Chambrone e Tatakis 2015). O retalho posicionado coronariamente apresenta bons resultados, apesar da grande variabilidade descrita na literatura (Cairo et al. 2008). Na tentativa de melhorar a previsibilidade, a associação do enxerto subepitelial de tecido conjuntivo (ESTC) tem sido considerado o padrão ouro para o recobrimento de recessões gengivais (Cairo et al. 2008; Buti et al. 2013; Chambrone e Tatakis 2015). No entanto, a utilização desse enxerto, promove aumento do tempo operatório, dor, e complicações pós-operatórias, como sangramentos ou hematomas (Zucchelli et al. 2010; Chambrone and Tatakis 2015).

A fim de evitar a morbidade associada aos procedimentos de enxerto de tecido autógeno, pesquisas tem buscado um substituto adequado, apresentados novas técnicas ou combinações de diferentes técnicas com o retalho posicionado coronalmente (RPC) (Allen and Miller 1989; De Sanctis and Zucchelli 2007), como regeneração tecidual guiada (RTC) (Harris 2002) , matriz acelular dérmica (MDA) (Côrtes et al. 2004; Moslemi et al. 2011) , matriz de colágeno (MC) (Jepsen et al. 2013; Moreira et al. 2016), proteínas da matriz do esmalte (EMD) (Koop et al. 2012; McGuire et al. 2012; McGuire et al. 2016) ou aplicação de plasma rico em plaquetas (Keceli et al. 2008) e ainda a combinações de diversos biomateriais associado ao RPC, como ETCS associado ao EMD (Berlucchi et al. 2002; Rasperini et al. 2011); RTC e enxerto alógeno de osso liofilizado desmineralizado (Kimble et al. 2004) ou EMD (Trabulsi et al. 2004); beta-tricálcio fosfato associado a fatores de crescimento derivado de plaquetas recombinante humano (Singh and Suresh 2012); MDA associada a EMD (Shin et al. 2007; Pourabbas et al. 2015) ou fibroblastos gengivais (Jhaveri et al. 2010).

Uma revisão com metanálise (Buti et al. 2013) foi conduzida com o objetivo de estabelecer um ranking de eficácia clínica no recobrimento de recessões gengivais utilizando técnicas associadas ao retalho posicionado coronalmente. A utilização do enxerto de tecido

subepitelial foi considerada o padrão ouro no recobrimento gengival, pela redução da recessão e ganho de inserção. A utilização do EMD permitiu alta taxa de recobrimento completo, enquanto a utilização de Matriz de colágeno foi considerada tão efetiva quanto o enxerto autógeno para aumento de tecido queratinizado.

O uso de MC é uma alternativa que surgiu recentemente e tem demonstrado resultados promissores, evitando a necessidade de um segundo sítio cirúrgico (Rotundo e Pini-Prato 2012; Molnár et al. 2013; Atieh et al. 2015; Moreira et al. 2016). A estrutura da MC consiste em duas camadas funcionais: uma camada celular oclusiva, com fibras colágenas arranjadas de forma compacta, e uma camada porosa. Esta última favorece a formação do coágulo sanguíneo e o crescimento dos tecidos adjacentes, resultando, clinicamente, em maior formação de tecido queratinizado (Lorenzo et al. 2012). Do ponto de vista histológico, a reparação ocorre pela completa incorporação da MC aos tecidos adjacentes, sendo observada a formação de maior quantidade de novo cemento e de nova inserção na parte mais apical do defeito quando comparado ao RPC somente (Vignoletti et al. 2011).

Já a utilização do EMD em procedimentos de recobrimento radicular tem demonstrado boas características clínicas, além de regeneração periodontal, como verificado em estudos com avaliação histológica em humanos com a formação de novo osso, cemento e ligamento periodontal (Sculean et al. 2008; McGuire et al. 2016). O EMD é composto de diferentes proteínas, 90% das quais são amelogeninas, que tem a capacidade de induzir os processos de regeneração dos tecidos periodontais de maneira semelhante ao desenvolvimento normal dos tecidos (Hammarström et al. 1997). Diversos estudos clínicos e em animais têm demonstrado a utilização das proteínas derivadas da matriz de esmalte em procedimentos periodontais regenerativos para a formação de um novo periodonto (Fujita et al. 2011; Hammarström et al. 1997; Sallum et al. 2004; Corrêa et al. 2012).

Apesar dos resultados alcançados por esses tratamentos, não foram identificados estudos clínicos controlados para avaliação do papel da MC associada ao EMD em procedimentos de recobrimento radicular. Assim, o objetivo deste estudo foi avaliar clinicamente os resultados obtidos no tratamento de recessões gengivais Classe I e II de Miller tratadas por meio de retalho posicionado coronariamente combinado com matriz de colágeno de origem suína e/ou proteínas da matriz do esmalte.

2 ARTIGO:

Xenogenous collagen matrix and/or enamel matrix derivative for treatment of localized gingival recessions - a randomized clinical trial. Part I: primary outcome.

Artigo submetido a revista Journal of Periodontology (anexo 1).

João Paulo Menck Sangiorgio*

Felipe Lucas da Silva Neves**

Manuela Rocha dos Santos†

Isabela Lima França-Grohmann*

Renato Corrêa Viana Casarin‡

Márcio Zaffalon Casati§

Mauro Pedrine Santamaria‡‡

Enilson Antonio Sallum§

Corresponding address/author: Dr. Enilson Antonio Sallum.

Avenida Limeira, 901 – Areião – Piracicaba – São Paulo – Brasil - Caixa postal 52

CEP: 13414-903 / Phone: +55 (19) 2106-5301 / E-mail: easallum@fop.unicamp.br

Word count (excluding the abstract, references, and figure legends): 3975

Figures: 2

Tables: 4

References: 33

Running title: Collagen Matrix and EMD for Gingival Recessions – Part I

Key findings: EMD and/or CM improve clinical results achieved with CAF in localized gingival recession therapy.

Abstract

Background: Considering xenogeneic collagen matrix (CM) and enamel matrix derivative (EMD) characteristics, it is suggested that their combination could promote superior clinical outcomes in root coverage procedures. Thus, the aim of this parallel, double-blinded, dual-centre, randomized clinical trial was to evaluate the clinical outcomes after treatment of localized gingival recession by coronally advanced flap (CAF) combined with CM and/or enamel matrix derivative (EMD).

Methods: Sixty-eight patients presenting one Miller Class I or II gingival recessions were randomly assigned to receive either CAF (n=17); CAF + CM (n=17); CAF+EMD (n=17) or CAF+CM+EMD (n=17). Recession height (GR), probing depth (PD), clinical attachment level (CAL), keratinized tissue width (KTW) and thickness (KTT), were measured at baseline, 3 and 6 months post-surgery.

Results: The obtained root coverage was $68.04 \pm 24.11\%$ for CAF; $87.20 \pm 15.01\%$ for CAF+CM; $88.77 \pm 20.66\%$ for CAF+EMD and $91.59 \pm 11.08\%$ for CAF+CM+EMD after 6 months, with the groups receiving biomaterials showing greater values ($p < 0.05$) Complete root coverage for CAF+EMD was 70.59%, significantly superior to CAF alone (23.53%); CAF+CM (52.94%) and CAF+CM+EMD (51.47%) ($p < 0.05$). Keratinized tissue thickness gain was significant only in CM treated groups ($p < 0.05$).

Conclusions: The 3 approaches are superior to CAF alone for root coverage. EMD provides highest levels of complete root coverage, however, the addition of CM increases gingival thickness. The combination approach does not seem justified.

Keywords: *Collagen; enamel matrix proteins; gingival recession; tissue regeneration; clinical trial*

Introduction

A recent systematic review concerning untreated recession defects in subjects with good oral hygiene demonstrated a high probability of recession progress after a long-term follow-up¹. For that reason, the increasing interest in periodontal plastic surgeries for root coverage is pushing the researchers forward in the effort to design and test different surgical treatments that guarantee good clinical outcomes and response to a high aesthetic demands with minimal invasiveness².

The combination of subepithelial connective tissue graft (SCTG) with coronally advanced flap (CAF) has been demonstrated to have the highest probability to achieve complete root coverage (CRC) and best aesthetic outcomes at professional and patient level for localized gingival recessions by several randomized clinical trials and systematic reviews³⁻⁵. However, the wound at the donor site for harvesting the SCTG is frequently associated with discomfort, swelling and occasionally pain^{4,6,7}.

Consequently, alternatives to SCTG have been pursued. The use of xenogeneic collagen matrix (CM) has been suggested as an effective treatment option to achieve root coverage and some increase in soft tissue thickness with a less invasive, time consuming, and unlimited supply⁸⁻¹⁰. Thus, it may be considered a feasible substitute to the SCTG procedure. Furthermore, the use of enamel matrix derivative proteins (EMD) in root coverage procedures has shown excellent clinical features as the improvement of the probability to achieve complete root coverage in localized Miller class I and II gingival recessions when compared to the CAF alone^{11,12}. Also, periodontal regeneration, as seen in histological studies in animals and humans with the formation of new bone, cementum, and periodontal ligament are associated with EMD use^{13,14}.

Based on these biomaterials characteristics, it could be hypothesized that the association of CM and EMD would increase the predictability of the treatment of gingival recession defects. However, within the author's knowledge, there is no available study that compared, at the same trial, the isolated and combined use of these 2 biomaterials (CM/EMD). Therefore, it is the goal of this randomized clinical trial to evaluate the clinical outcomes after the treatment of gingival recession with the coronally advanced flap combined to a porcine collagen matrix graft and/or enamel matrix derivative.

Material and methods

Experimental design

This is a parallel, double-blinded, dual-centre, randomized clinical trial registered on U.S. National Institutes of Health Clinical Trials Registry - (NCT02456337). Four different surgical approaches were compared for the treatment of single Miller class I and II gingival recessions: CAF alone (CAF); CAF plus CM (CAF+CM)^{§§}; CAF plus EMD (CAF+EMD)^{||} and CAF plus CM and EMD (CAF+CM+EMD).

All patients signed an informed consent after receiving a detailed explanation concerning the nature, risks, and benefits of this clinical investigation. The study protocol has been approved by the Institutional Review Board of the Piracicaba Dental School, State University of Campinas (CEP-UNICAMP 067/2013).

Participants

In the period of October 2013–April 2016, 68 patients were screened among those referred for periodontal treatment at the Periodontology Clinic of the Piracicaba Dental School, State University of Campinas (FOP-UNICAMP) and the Periodontology Clinic of UNESP - State University of São Paulo (São José dos Campos, Brazil).

Eligibility criteria

Patients older than 18 years old with the presence of Miller class I or II gingival recession (>3mm) in the maxillary canines or premolars with an identifiable cemento-enamel junction (CEJ) and tooth vitality; absence of active periodontal disease; full-mouth bleeding and plaque score \leq 20% and signed informed consent form.

Exclusion Criteria

Patients taking any kind of medication that could interfere with the periodontal tissue health or healing; presence of systemic problems; smoker, pregnancy or current intention to become pregnant, as well as lactating women; patients with previous periodontal plastic surgery procedures on the selected site; extruded or malpositioned teeth.

Preparation period

After the initial examination, all patients received oral hygiene instructions to modify traumatic tooth brushing habits and to inform about the etiology and treatment of gingival recessions. A supragingival scaling session and dental prophylaxis was performed 2 weeks before the scheduled surgical procedure. The plastic surgery procedures were performed when adequate plaque control was reached.

Investigator training

All investigators were required to attend three training and calibration meetings with the purposes of reviewing the study objectives and protocols, the standardization of case selection, clinical measurements, surgical procedures, explanations and communication procedures.

Clinical Assessments

At baseline, after 3 and 6 months, the following clinical parameters were evaluated: full-mouth visible plaque index (FMPI); full-mouth sulcus bleeding index (FMBI); probing depth

(PD): measured in millimeters with a periodontal probe^{††}; clinical attachment level (CAL): at the mid-buccal aspect of the tooth, the distance between the cemento-enamel junction (CEJ) and the lowest level of PD; (GR): the distance from the GM to the CEJ at the mid-buccal aspect of the tooth. GR measurements were done through the use of a digital caliper accurate to 0.01 mm[¶]. Keratinized tissue width (KTW) was measured from the GM to the mucogingival junction (MGJ) and evidenced with iodine solution stain^{***}; keratinized tissue thickness (KTT) was measured at the mid-point of KTW.

Calibration of the examiners

All clinical measurements were performed by two blinded and calibrated periodontists (FLSN and JPMS, one in each center). Calibration was done by double measurements of GR in 30 recession defects. Intra-class correlation was used to determine the intra-examiner and inter-examiner reproducibility of the measurements. FLSN reached IC = 0.84 intra-examiner agreement values. JPMS intra-examiner agreement was IC = 0.88. Inter-examiner agreement was IC = 0.86 for all measurements.

Aesthetic Evaluation

Two professional aesthetic evaluation were performed, using the visual analog scale (VAS) and the root coverage aesthetic score (RES)¹⁵. Pictures of the baseline and 6 months aspects were evaluated by four different independent periodontists, unaware of the treatment performed in each site. Patient-centered outcomes were also evaluated in the trial, and will be presented elsewhere (Part II).

Randomization, allocation concealment and blinding

The randomization of the patients was performed through a computer-generated randomization table, organized by an external individual (ILSG), not involved in the recruitment, treatment, or evaluation of the patients. Following this sequence, opaque, sealed

envelopes were prepared, containing the randomization treatment code for each patient. The treatment was only revealed to the surgeon once the flap was completed. Additionally, neither the patients nor the investigators who performed the clinical assessments knew which treatment each patient received.

Treatment

Two experienced and standardized surgeons (EAS and MPS) performed the surgical procedures, one in each center (EAS at UNICAMP, MPS at UNESP). A trapezoid-shaped flap (CAF) with a split–full–split approach was elevated¹⁶. After, the papillae have been deepithelialized, the debridement of the exposed root surface was performed by manual instrumentation. At this moment, the designated treatment was revealed to the surgeon. The EMD was applied to the selected sites and left on a dried root surface for at least 2min. When CM was used, the matrix of the desired defect dimensions was trimmed and placed over the defect and sutured independently of the flap, with the porous surface in contact with the bone and the tooth. Finally, interrupted sutures were performed to position the flap coronal to the CEJ using Vicryl 5/0[#]. One hour before surgery, anti-inflammatory medication was administered^{##}. For pain control, postoperative analgesics were prescribed four times a day for 3 days^{¶¶}.

In addition, patients were instructed to chlorhexidine (0.12 %) rinse twice a day for 1 min and discontinue tooth brushing of the sites. Sutures were removed after 15 days and patients were instructed to resume tooth brushing with caution, using a soft toothbrush. All patients were enrolled in a periodontal maintenance program (professional plaque control and oral hygiene instruction) monthly during the 6 months.

Statistical analysis

Sample size calculation for this superiority trial was performed considering root coverage as the primary outcome. The study was powered to detect a significant difference in root recession reduction among four groups (F test – ANOVA for repeated measurements: $\alpha = 0.05$, power = 80%, effect size = 0.443), based on data from previous studies to calculate the effect size^{8,17,18}. A total sample of 60 patients was required in the present trial. No subjects were lost to follow-up during the 6 months. After the completion of the study, considering the SD of each group, the power values were confirmed to be >80% to detect a difference in recession reduction (Rec Red) between the four groups.

Descriptive statistical analysis was expressed by mean \pm standard deviation (SD), percentages and confidence intervals (CI 95%). To verify the hypothesis of association between the group distributions, the Fisher exact test was performed for the proportions of gender, operated teeth and complete coverage. McNemar test was used to compare correlated samples for complete coverage. The treatments were compared by means of analysis of variance. Initially, the diagnosis was made to analyze the normality of the residue by the Shapiro-Wilk test. In the presence of normal distribution, the analysis of variance was performed for the parameters Age, FMPI and FMBI. When one effect was observed, the effect of the factor was analyzed, comparing the means by Tukey test. In cases where it was not possible to obtain normality of the residue, the analysis was performed using non-parametric statistics through the Kruskal-Wallis test for the remaining parameters. For analysis of only two factors it was used Mann-Whitney U. A significance level of 5% was adopted for all tests ($\alpha < 0.05$). No center-effect on the treatment outcomes could be statistically demonstrated.

Results

A flow diagram of participants in the study is enclosed (Fig. 1). Table 1 shows the characteristics of the included subjects at baseline. This study included 68 patients (mean age: 37.53), enrolled and treated between October 2013 and April 2016. 61% were female, and 51%

of the teeth were premolars. Baseline patient- and clinical-related characteristics did not present any significant difference among groups ($p > 0.05$). FMPI and FMBI were maintained below 20% during the study period. The sites included in the study did not show bleeding on probing or visible plaque during the entire study period. All clinical parameters at baseline, 90 days and 6 months are shown in Table 2. No significant adverse events were observed.

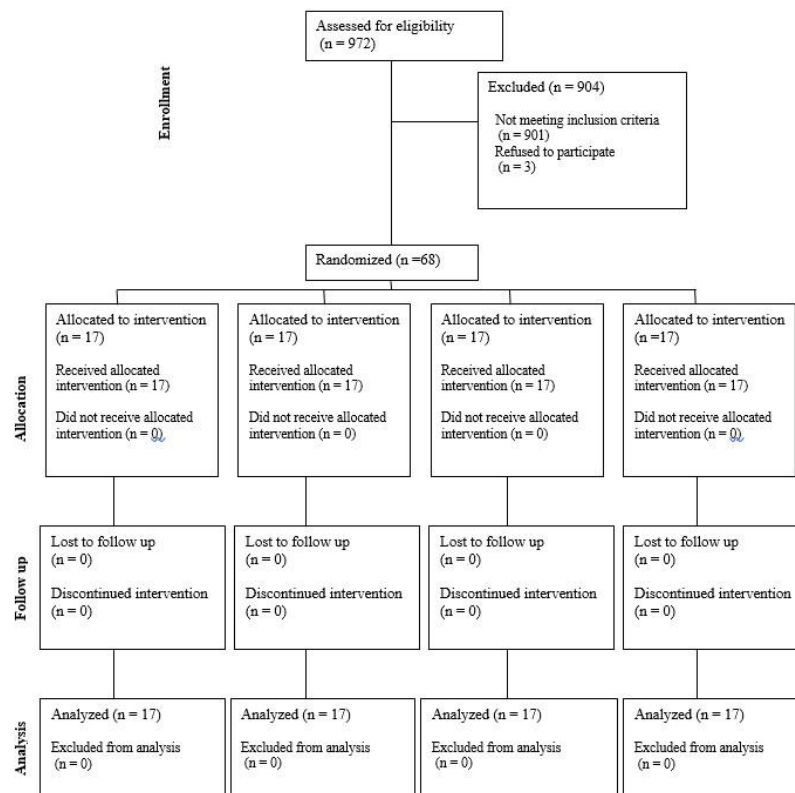


Figure 1. Flowchart of the RCT according to CONSORT.

Table 1. Patients characteristics at the baseline (n=68)

Characteristic	CAF	CAF+CM	CAF+EMD	CAF+CM+EMD	p
Age mean± SD	38,12 ± 12,95	39,47 ± 10,94	39,29 ± 10,23	33,24 ± 10,41	0,331
Gender Female	11 (64,71%)	10 (58,82%)	10 (58,82%)	11 (64,71%)	0,969
Male	6 (35,29%)	7 (41,18%)	7 (41,18%)	6 (35,29%)	
Teeth Canine	6 (35,29%)	9 (52,94%)	7 (41,18%)	11 (64,71%)	0,324
Premolar	11 (64,71%)	8 (47,06%)	10 (58,82%)	6 (35,29%)	
FMPI mean± SD	14,61 ± 5,26	13,67 ± 2,69	14,48 ± 2,13	11,91 ± 2,92	0,099
95% CI	(11,91 - 17,31)	(12,29 - 15,06)	(13,38 - 15,57)	(10,41 - 13,42)	
FMBI mean± SD	10,35 ± 3,63	13,16 ± 5,42	12,43 ± 6,13	9,85 ± 2,36	0,120
95% CI	(8,48 - 12,21)	(10,37 - 15,95)	(9,27 - 15,58)	(8,64 - 11,07)	

p values testing differences between treatment groups were calculated using ANOVA/Tukey for Age, FMPI and FMBI. P values for Gender and Teeth were obtained by Fisher Exact Test. ($\alpha < 0.05$)

CAF coronally advanced flap, CM porcine collagen matrix, EMD Enamel matrix derivative, SD standard deviation, FMPI full-mouth plaque index, FMBI full-mouth bleeding index

Pocket depth

PD was practically unaffected in all groups throughout the study without any statistically significant difference over time and among the groups.

Clinical attachment level

In the CAF group, CAL changed from $4,72 \pm 0,86$ mm at baseline to $2,54 \pm 1,21$ mm at 6 months, corresponding to a gain of $2,18 \pm 1,11$ mm. CM group changed from $4,56 \pm 0,68$ mm to $1,69 \pm 0,47$ mm (Cal gain of $2,87 \pm 0,75$). For the EMD treated group, CAL changed from $4,51 \pm 0,59$ mm to $1,81 \pm 0,82$ mm, corresponding to a gain of $2,70 \pm 0,84$ mm. In the EMD+CM group, a CAL gain of $2,91 \pm 0,87$ mm was observed, after changing from $4,66 \pm 0,53$ mm at baseline to $1,75 \pm 0,67$ mm at 6 months. The changes from baseline to 90 days and 6 months were significant ($p < 0.001$) in all groups, although there was no significant difference among them.

Table 2. Clinical results in mm (n=68)

Parameters		CAF mean± SD (95% CI)	CAF+CM mean± SD (95% CI)	CAF+EMD mean± SD (95% CI)	CAF+CM+EMD mean± SD (95% CI)	p
PD	Baseline	$1,50 \pm 0,75$ (1,11 - 1,89)	$1,44 \pm 0,56$ (1,16 - 1,73)	$1,47 \pm 0,48$ (1,22 - 1,72)	$1,50 \pm 0,50$ (1,24 - 1,76)	0,968
	90d	$1,50 \pm 0,56$ (1,21 - 1,79)	$1,44 \pm 0,66$ (1,1 - 1,78)	$1,53 \pm 0,6$ (1,22 - 1,84)	$1,53 \pm 0,5$ (1,27 - 1,8)	0,913
	180d	$1,47 \pm 0,54$ (1,19 - 1,75)	$1,26 \pm 0,44$ (1,04 - 1,49)	$1,44 \pm 0,50$ (1,19 - 1,7)	$1,47 \pm 0,48$ (1,22 - 1,72)	0,552
	90d-baseline	$0,00 \pm 0,68$ (-0,35 - 0,35)	$0,00 \pm 0,64$ (-0,33 - 0,33)	$0,06 \pm 0,73$ (-0,31 - 0,43)	$-0,06 \pm 0,58$ (-0,36 - 0,24)	0,93
	180d-baseline	$-0,03 \pm 0,74$ (-0,41 - 0,35)	$-0,18 \pm 0,50$ (-0,43 - 0,08)	$-0,03 \pm 0,67$ (-0,38 - 0,32)	$-0,03 \pm 0,60$ (-0,34 - 0,28)	0,820
	180d-90d	$-0,03 \pm 0,37$ (-0,22 - 0,16)	$-0,18 \pm 0,43$ (-0,40 - 0,05)	$-0,09 \pm 0,54$ (-0,36 - 0,19)	$0,03 \pm 0,45$ (-0,20 - 0,26)	0,639
	CAL	Baseline	$4,72 \pm 0,86$ (4,28 - 5,16)	$4,56 \pm 0,68$ (4,22 - 4,91)	$4,51 \pm 0,59$ (4,20 - 4,81)	$4,66 \pm 0,53$ (4,39 - 4,93)
90d		$2,40 \pm 1,11$ (1,83 - 2,96)	$1,83 \pm 0,79$ (1,43 - 2,24)	$1,84 \pm 0,86$ (1,40 - 2,28)	$1,79 \pm 0,72$ (1,41 - 2,16)	0,302
180d		$2,54 \pm 1,21$ (1,92 - 3,16)	$1,69 \pm 0,47$ (1,45 - 1,93)	$1,81 \pm 0,82$ (1,39 - 2,23)	$1,75 \pm 0,67$ (1,40 - 2,10)	0,079
90d-baseline		$-2,32 \pm 0,93^*$ (-2,8 - -1,85)	$-2,73 \pm 0,92^*$ (-3,21 - -2,25)	$-2,66 \pm 0,86^*$ (-3,11 - -2,22)	$-2,88 \pm 0,81^*$ (-3,29 - -2,46)	0,360
180d-baseline		$-2,18 \pm 1,11^*$ (-2,75 - -1,61)	$-2,87 \pm 0,75^*$ (-3,26 - -2,48)	$-2,70 \pm 0,84^*$ (-3,13 - -2,27)	$-2,91 \pm 0,87^*$ (-3,36 - -2,46)	0,214

	180d-90d	0,15 ± 0,43 (-0,07 - 0,37)	-0,14 ± 0,56 (-0,43 - 0,15)	-0,03 ± 0,53 (-0,30 - 0,24)	-0,04 ± 0,48 (-0,28 - 0,21)	0,099
GR	Baseline	3,22 ± 0,45 (2,99 - 3,45)	3,12 ± 0,40 (2,92 - 3,33)	3,04 ± 0,31 (2,88 - 3,2)	3,16 ± 0,33 (2,99 - 3,33)	0,427
	90d	0,88 ± 0,77a (0,49 - 1,28)	0,38 ± 0,51b (0,12 - 0,64)	0,31 ± 0,57b (0,02 - 0,61)	0,33 ± 0,41b (0,12 - 0,55)	0,044
	180d	1,06 ± 0,86a (0,62 - 1,49)	0,41 ± 0,49b (0,16 - 0,67)	0,37 ± 0,66b (0,03 - 0,71)	0,26 ± 0,34b (0,08 - 0,43)	0,008
	90d-baseline	-2,34 ± 0,65* (-2,67 - -2,00)	-2,74 ± 0,44* (-2,97 - -2,51)	-2,72 ± 0,51* (-2,99 - -2,46)	-2,83 ± 0,64* (-3,16 - -2,50)	0,101
	180d-baseline	-2,16 ± 0,75*a (-2,55 - -1,78)	-2,71 ± 0,51*b (-2,97 - -2,45)	-2,67 ± 0,57*b (-2,96 - -2,37)	-2,91 ± 0,53*b (-3,18 - -2,63)	0,020
	180d-90d	0,17 ± 0,19*a (0,08 - 0,27)	0,03 ± 0,33b (-0,14 - 0,2)	0,05 ± 0,12b (-0,01 - 0,12)	-0,08 ± 0,24b (-0,2 - 0,05)	0,001
KTW	Baseline	2,86 ± 1,30 (2,19 - 3,53)	2,58 ± 1,47 (1,83 - 3,34)	2,59 ± 1,43 (1,85 - 3,32)	2,32 ± 1,07 (1,77 - 2,87)	0,747
	90d	3,07 ± 1,25 (2,42 - 3,71)	2,67 ± 1,20 (2,06 - 3,29)	2,66 ± 0,98 (2,15 - 3,16)	2,61 ± 0,72 (2,24 - 2,98)	0,735
	180d	3,16 ± 1,26 (2,51 - 3,81)	2,93 ± 1,18 (2,33 - 3,54)	2,95 ± 1,07 (2,40 - 3,5)	2,65 ± 0,70 (2,30 - 3,01)	0,664
	90d-baseline	0,21 ± 1,35 (-0,49 - 0,90)	0,09 ± 1,11 (-0,48 - 0,66)	0,07 ± 0,94 (-0,41 - 0,55)	0,29 ± 0,82 (-0,13 - 0,71)	0,879
	180d-baseline	0,30 ± 1,4 (-0,42 - 1,02)	0,35 ± 1,04 (-0,19 - 0,89)	0,36 ± 0,9 (-0,1 - 0,82)	0,34 ± 0,86 (-0,11 - 0,78)	0,996
	180d-90d	0,09 ± 0,28 (-0,05 - 0,24)	0,26 ± 0,68 (-0,09 - 0,61)	0,29 ± 0,52 (0,03 - 0,56)	0,05 ± 0,47 (-0,19 - 0,29)	0,143
KTT	Baseline	0,94 ± 0,30 (0,78 - 1,1)	0,84 ± 0,26 (0,71 - 0,97)	0,88 ± 0,26 (0,75 - 1,02)	0,92 ± 0,19 (0,82 - 1,02)	0,596
	90d	1,16 ± 0,39 (0,96 - 1,35)	1,17 ± 0,42 (0,96 - 1,39)	0,99 ± 0,18 (0,9 - 1,09)	1,20 ± 0,27 (1,06 - 1,34)	0,236
	180d	1,07 ± 0,35 (0,89 - 1,25)	1,20 ± 0,40 (0,99 - 1,40)	1,00 ± 0,21 (0,89 - 1,11)	1,22 ± 0,26 (1,08 - 1,35)	0,092
	90d-baseline	0,22 ± 0,33* (0,05 - 0,39)	0,33 ± 0,51* (0,07 - 0,59)	0,11 ± 0,25 (-0,02 - 0,24)	0,28 ± 0,33* (0,11 - 0,45)	0,633
	180d-baseline	0,13 ± 0,32 (-0,04 - 0,29)	0,36 ± 0,47* (0,11 - 0,60)	0,12 ± 0,27 (-0,02 - 0,26)	0,30 ± 0,31* (0,14 - 0,46)	0,139
	180d-90d	-0,09 ± 0,34 (-0,26 - 0,09)	0,02 ± 0,12 (-0,04 - 0,09)	0,01 ± 0,10 (-0,05 - 0,06)	0,02 ± 0,04 (0,00 - 0,04)	0,520

P value obtained using Kruskal–Wallis H test. Different letters indicate significant differences between groups by Mann–Whitney U test ($p < 0.05$). Asterisk indicates differences within groups over time by Wilcoxon signed-rank test ($\alpha < 0.05$). CAF coronally advanced flap, CM porcine collagen matrix, EMD Enamel matrix derivative, SD standard deviation, CI confidence interval, PD probing depth, CAL clinical attachment level, GR gingival recession depth, KTW keratinized tissue width, KTT keratinized tissue thickness.

Gingival recession

At CAF treated sites, GR decreased from $3,22 \pm 0,45$ mm at baseline to $1,06 \pm 0,86$ mm at 6 months post-operative corresponding to a mean root coverage (MRC) of $68,04 \pm 24,11$ % (GR reduction of $2,16 \pm 0,75$ mm). At CM treated sites, GR changed from $3,12 \pm 0,40$ mm to $0,41 \pm 0,49$ mm, corresponding to a MRC of $87,2 \pm 15,01$ %. At EMD treated sites, GR at

baseline was $3,04 \pm 0,31$ mm and decreased to $0,37 \pm 0,66$ mm at 6 months, showing a MRC of $88,77 \pm 20,66$ %. When CM and EMD were combined for the treatment of gingival recessions, the GR decreased from $3,13 \pm 0,37$ mm to $0,26 \pm 0,34$ mm, corresponding to a MRC of $91,59 \pm 11,08$ % (GR gain of $2,91 \pm 0,53$ mm) at 6 months.

From 90 days to 6 months, MRC decreased significantly from 73,46% to 68,04% ($p < 0,05$) in the CAF group (GR increased $0,17 \pm 0,19$ mm). Whereas, in CM and EMD groups slightly decreased from 88,6 % and 90,38 % to 87,2 % and 88,77 % respectively. In the CM+EMD group, MRC increased from 88,82 % to 91,59 %.

CRC achieved in the EMD group was 70,59 % (12/17), significantly superior to CAF, 23,53 % (4/17); CM, 52,94 % (9/17), and CM+EMD group, 58,82 % (10/17) after 6 months (Table 3). Reduction of the recession was significant for all groups from baseline to 90 days and 6 months, however CAF reduction was statistically smaller than all the others ($p < 0,05$).

Keratinized Tissue

For KTW, CAF group changed from $2,86 \pm 1,30$ mm at baseline to $3,16 \pm 1,26$ mm at 6 months (KTW gain of $0,30 \pm 1,40$ mm). In the CM group, KTW changed from $2,58 \pm 1,47$ mm to $2,93 \pm 1,18$ mm, corresponding to a gain of $0,35 \pm 1,04$ mm. For the EMD group, the change was from $2,59 \pm 1,43$ mm to $2,95 \pm 1,07$ mm (a gain of $0,36 \pm 0,90$ mm). In the CM +EMD group, the tissue width changed from $2,32 \pm 1,07$ mm at baseline to $2,65 \pm 0,70$ mm at 6 months (a gain of $0,34 \pm 0,86$ mm). The changes from baseline to 90 days and 6 months were not statistically significant ($p > 0,05$).

Table 3. Percentage of root coverage (n=68)

	CAF mean± SD (95% CI)	CAF+CM mean± SD (95% CI)	CAF+EMD mean± SD (95% CI)	CAF+CM+EMD mean± SD (95% CI)	P
Average % root coverage					
90d	$73,46 \pm 21a$ (62,66 - 84,26)	$88,6 \pm 15,04b$ (80,87 - 96,34)	$90,38 \pm 17,97b$ (81,14 - 99,62)	$88,82 \pm 14,23b$ (81,51 - 96,14)	0,018

180d	68,04 ± 24,11a (55,64 - 80,44)	87,2 ± 15,01b (79,48 - 94,91)	88,77 ± 20,66b (78,15 - 99,39)	91,59 ± 11,08b (85,9 - 97,29)	0,001
P between time	0,002	0,579	0,08	0,19	
Patients with 100% coverage					
90d	5 (29,41 %)a	10 (58,82 %)a	12 (70,59 %)b	9 (52,94 %)a	0,105
180d	4 (23,53 %)a	9 (52,94 %)a	12 (70,59 %)b	10 (58,82 %)b	0,042
P between time	0,977				

P values are obtained using Kruskal–Wallis H test for intergroup comparisons and Wilcoxon signed-rank test for intragroup average percentage of root coverage. Patients with 100% coverage - Fisher Exact Test for intergroup comparisons and McNemar test comparing correlated samples. ($\alpha < 0.05$) CAF coronally advanced flap, CM porcine collagen matrix, EMD Enamel matrix derivative, SD standard deviation, CI confidence interval

For KTT, CAF group changed from $0,94 \pm 0,30$ mm at baseline to $1,07 \pm 0,35$ mm at 6 months, corresponding to a gain of $0,13 \pm 0,32$ mm. In the CM group, KTT changed from $0,84 \pm 0,26$ mm to $1,20 \pm 0,40$ mm, a thickness gain of $0,36 \pm 0,47$ mm. For the EMD group, $0,88 \pm 0,26$ mm at baseline to $1,00 \pm 0,21$ mm (a gain of $0,12 \pm 0,27$ mm). In the CM +EMD group, the tissue thickness changed from $0,92 \pm 0,19$ mm at baseline to $1,22 \pm 0,26$ mm at 6 months, corresponding to $0,30 \pm 0,31$ mm of gain. The changes from baseline to 90 days were significant to CAF, CM and CM+EMD ($p < 0.05$), however, at 6 months only CM and CM+EMD significantly increased the KTT ($P < 0.05$).

Table 4. Professional esthetic evaluation (n=68)

	CAF mean± SD (95% CI)	CAF+CM mean± SD (95% CI)	CAF+EMD mean± SD (95% CI)	CAF+CM+EMD mean± SD (95% CI)	p
RES	7,71 ± 2,02 (6,67 - 8,75)	8,29 ± 2,54 (6,99 - 9,6)	7,82 ± 3 (6,28 - 9,37)	8,47 ± 1,59 (7,66 - 9,29)	0,645
VAS	8,29 ± 1,36 (7,6 - 8,99)	8,65 ± 1,58 (7,84 - 9,46)	9,00 ± 1,22 (8,37 - 9,63)	8,82 ± 1,01 (8,3 - 9,35)	0,427

P values are obtained using Kruskal–Wallis H test for intergroup comparisons ($\alpha < 0.05$) CAF coronally advanced flap, CM porcine collagen matrix, EMD Enamel matrix derivative, SD standard deviation, CI confidence interval, RES Root Coverage Esthetic Score, QCE Qualitative Cosmetic Evaluation

Esthetic evaluation

For the professional aesthetic evaluation, the outcomes were estimated using RES and VAS. These objective measurements showed no statistically significant difference ($p > 0,05$) among the groups (Table 4).

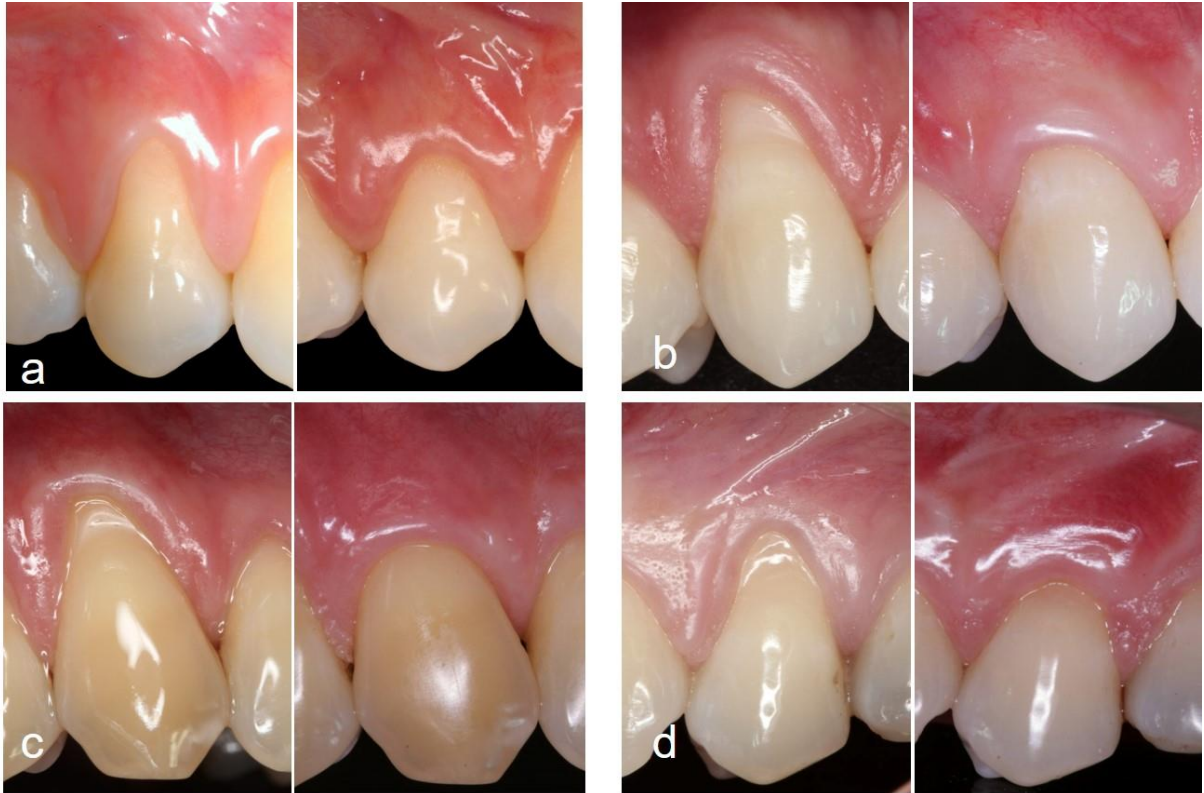


Figure 2. Baseline and final aspect at 6-months for (a) CAF; (b) CM; (c) EMD and (d) CM+EMD groups.

Discussion

As alternatives to the use of autogenous grafts, several biomaterials have been studied for the treatment of localized gingival recessions¹⁹. All tested approaches achieved a considerable percentage of root coverage ($68,04 \pm 24,11\%$ for CAF, $87,2 \pm 15,01\%$ for CAF+CM, $88,77 \pm 20,66\%$ for CAF+EMD and $91,59 \pm 11,08\%$ for CAF+CM+EMD). This difference was significant (CAF versus other groups), however the groups receiving biomaterials did not present difference among them. Hence, the hypothesis of an enhanced outcome by the combined use of the CM+EMD could not be confirmed.

In order to evaluate the additional benefit of CM in the CAF procedure for root coverage, Jepsen et al. (2013) reported a MRC of 75.3% for CAF+CM and 72,66% for CAF defects¹⁰. Moreira et al. (2016) showed 77.2% for CAF +CM group and 72.1 % for CAF group⁸. None of

these previous RCTs found significant difference between groups, what is not in accordance with the present study, where CM group was better than CAF alone for root coverage, after 6 months. When CM was compared to the gold-standard treatment (SCTG), McGuire & Scheyer (2010) showed that the results in terms of aesthetic outcomes and patient satisfaction were good in both groups, the MRC was significantly superior for the CAF + SCTG procedure (99.3% versus 88.5% for CM)⁹. Cardaropoli et al. (2012) presented a MRC of 94.3% for CM group and 96.9% for SCTG group²⁰. This percentages for CM groups were comparable to the one achieved in the present study.

Some studies have evaluated the outcomes of EMD associated to CAF procedures. The improvements observed in this study for EMD groups are consistent with the results obtained by Spahr et al. (2005) (84% for EMD group and 67% for CAF group)¹⁷; Del Pizzo et al. (2005) (90.6% for EMD and 86.7% for CAF group) and Cordaro et al. (2012) (82.8% for EMD and 80.7% for CAF) after 24-month follow-up^{21,22}. However, Spahr et al. (2005) was able to achieve a significant difference regarding the stability of EMD, whereas 47% of gingival recessions treated with CAF alone deteriorated after two years, compared with 22% of root coverage relapse in the test group¹⁷. As observed in this study, from 90 to 180 days, the CAF group was less stable than the others, demonstrating a significant difference in gingival recession. This deterioration is less frequently when SCTG-based procedures or soft tissue graft substitutes are used⁴.

When EMD was compared to SCTG for MRC, Alkan & Parlar (2011) achieved 92% for EMD and 89% for SCTG and Moses et al. (2006) obtained 73.2% for EMD and 86.8% for SCTG, comparable to the %RC obtained in this study^{23,24}. The influence of EMD when associated with SCTG was reported also. Rasperini et al. (2011) described root coverage rates of 90% for SCTG plus EMD and 80% for STCG groups after 1 year²⁵. In contrast, Roman et al. (2013) observed 82.3% for SCTG plus EMD and 89.8% for SCTG alone¹⁸. For these studies,

the adjunctive use of EMD with SCTG didn't show any significant additional benefit. Actually, although the use of EMD produced a significant improvement of CAF alone, the multiple combinations, using more than a single graft/biomaterial under the flap, may present comparable or less benefits than simpler procedures¹⁹. To the best of our knowledge, this is the first RCT that compared the isolated and combined use of EMD and CM at the same trial.

Complete root coverage is the ultimate goal in the treatment of localized gingival recessions and has been considered as an ideal outcome after root coverage procedures¹⁵. Data in the present trial revealed that CRC was achieved in 70.59% and 58.82% of the patients treated with CAF plus EMD or CAF+CM+EMD, respectively; and was statistically different from CAF (23.53%), but with no difference from CAF+CM (52.94%). Thus, the use of EMD enhanced the clinical outcome for complete root coverage compared to CAF alone. Clearly, before a more definitive conclusion can be made, the stability of the results must be evaluated over longer periods of time, at least 2 years of follow-up.

Del Pizzo et al. (2005) obtained no significant differences between EMD and control groups, though CRC was achieved in 73.3% for CAF plus EMD group and in 60.0% for CAF group²¹. When compared to SCTG, McGuire et al. (2012) obtained CRC in 89.5% for EMD and in 79% for SCTG²⁷. Rasperini et al. (2011) achieved 61.5% for SCTG+EMD and 46.7 for SCTG alone²⁵. For CM, the percentage of sites showing CRC described by Cardaropoli et al. (2012) was 72 % for CM and 81% for SCTG²⁰. On the other hand, data reported by Jepsen et al. (2013) showed 31 % for CAF and 36% for CAF + CM¹⁰. Moreira et al. (2016) found 35% for CAF and 40% for CM group⁸. In a recent systematic review¹¹, Cairo et al. (2008) described that no treatment, except for CAF plus EMD, achieved a comparable SCTG efficacy for complete root coverage.

The rationale for using EMD in root coverage procedures, in addition to its clinical characteristics, is the possibility to regenerate the lost periodontal tissues, as demonstrated in

several studies with histological evaluation in animals and humans, with the formation of new bone, cementum and periodontal ligament, rather than periodontal repair^{13,14,28,29}. Recently, a study with human histologic examination evaluated the difference in regeneration capacity between EMD and SCTG. The sites treated with EMD exhibited varying degrees of periodontal regeneration whereas none of the teeth treated with SCTG showed regeneration, despite similar clinical outcomes¹³.

The present study, in alignment to Aroca et al. (2010), Henriques et al. (2010) and Moreira et al. (2016) didn't demonstrate additional keratinized tissue width (KTW) gain^{8,30,31}. After one year, increased KTW have been reported for CM associated to CAF procedure. McGuire & Scheyer (2010) and Cardaropoli et al. (2012), reported a gain of 1.34 mm and 1.23 mm, respectively when CM was used^{9,20}. Jepsen et al. (2013) observed that the CM treated group mean width after 6 months was 0.37 mm greater than the observed with CAF¹⁰. When EMD was used, Del Pizzo et al. (2005) observed an increase over time of 1.00mm, whereas the control group increased 0.47mm²¹. Cordaro et al. (2012) found a gain of 0.31mm and 0.28mm for CAF and CAF+EMD, respectively²². Still, none of the treatments evaluated in this RCT significantly change the KTW. The possible reason is that, MGJ identification procedure might be different among studies. In this study, it was performed after iodine solution stain, which may be different from the functional method³².

The CM use resulted in significantly gain in gingival thickness of keratinized tissue, when compared to baseline values while CAF and EMD groups did not show significant KTT change after 6 months. Moreira et al. (2016) reported a gain of 0.14 for CAF and 0.40 for CM after 6 months⁸. Jepsen et al. (2013) observed a gain of 0.59 and 0.34 mm for CM and CAF alone, respectively¹⁰. Ahmedbeyli et al. (2014) showed that increasing KTT ("biotype modification") might be an important outcome, once a thin gingival biotype may be related to the risk for gingival recession³³. Chambrone & Tatakis (2015) recently reviewed root coverage

procedure outcomes and reported that increase in KTT can prevent gingival recession recurrence at long-term⁴. However, it is also interesting to note that this observed increase might be considered clinically modest.

In terms of esthetic outcome after the surgeries, the visual analog scale (VAS) and the root coverage aesthetic score (RES)¹⁵ were applied to sets of clinical pictures (baseline/6 months) by four independent periodontists. This assessment confirmed no differences in aesthetics appearance among all treatment groups and an improved professional perception of aesthetics after the procedures.

Conclusions

It can be concluded that, the associations of CAF+CM, CAF+EMD and CAF+CM+EMD resulted in superior clinical outcomes regarding root coverage in comparison to CAF alone. Nevertheless, CAF+EMD and CAF+CM+EMD obtained highest levels of complete root coverage. The use of CM is associated with a slight (but significant) increase in gingival thickness that was not observed for CAF+EMD or CAF alone. The combined approach does not seem justified in terms of root coverage.

Footnotes

* MS, PhD student - Division of Periodontics - Piracicaba Dental School, State University of Campinas

** MS, PhD student - Division of Periodontics - State University of São Paulo Campus São José dos Campos, Brazil

† DDS, MS student - Division of Periodontics - Piracicaba Dental School, State University of Campinas

‡ PhD, Assistant professor - Division of Periodontics - Piracicaba Dental School, State University of Campinas

‡‡ PhD, Assistant professor - Division of Periodontics - State University of São Paulo Campus São José dos Campos, Brazil

§ PhD, Full professor - Division of Periodontics - Piracicaba Dental School, State University of Campinas

§§ Mucograft®; Geistlich Pharma AG, Wolhusen, Switzerland

|| Emdogain®, Institut Straumann AG, Basel, Switzerland

†† Hu-Friedy, Jacarepaguá, Rio de Janeiro, Brazil.

¶ Absolute, Mitutoyo Sul Americana, Suzano, São Paulo, Brazil.

*** Shiller's, Proderma Farmácia de Manipulação, Piracicaba, São Paulo, Brazil.

Johnson & Johnson, Skillman, NJ, USA.

Dexamethasone 4 mg, Ache Pharmaceutical Laboratories SA, Guarulhos, SP

¶¶ Dipyron 500 mg, Ache Pharmaceutical Laboratories SA, Guarulhos, SP ## Perio-Bond®, Dentsply, Petrópolis, Rio de Janeiro, Brazil.

Acknowledgments

The authors appreciate the financial support provided by the Research Funding Agency from São Paulo State (FAPESP), São Paulo, SP, Brazil - Grant 2013/19473-6. The authors report no conflicts of interest related to this study.

References

1. Chambrone L, Tatakis DN. Long-term Outcomes of Untreated Buccal Gingival Recessions. A Systematic Review and Meta-Analysis. *Journal of Periodontology*. 2016;87(7):1-17. doi:10.1902/jop.2016.150625.
2. Azaripour A, Kissinger M, Farina VSL, et al. Root coverage with connective tissue graft associated with coronally advanced flap or tunnel technique. A randomized, double blind, mono-center clinical trial. *Journal of Clinical Periodontology*. 2016;1142-1150. doi:10.1111/jcpe.12627.
3. Cairo F, Pagliaro U, Buti J, et al. Root coverage procedures improve patient aesthetics. A systematic review and Bayesian network meta-analysis. *Journal of Clinical Periodontology*. 2016;965-975. doi:10.1111/jcpe.12603.
4. Chambrone L, Tatakis DN. Periodontal Soft Tissue Root Coverage Procedures: A Systematic Review From the AAP Regeneration Workshop. *Journal of Periodontology*. 2015;86(2-s):S8-S51. doi:10.1902/jop.2015.130674.
5. Buti J, Baccini M, Nieri M, La Marca M, Pini-Prato GP. Bayesian network meta-analysis of root coverage procedures: Ranking efficacy and identification of best treatment. *Journal of Clinical Periodontology*. 2013;40:372-386. doi:10.1111/jcpe.12028.
6. Chambrone L, Sukekava F, Araújo MG, Pustiglioni FE, Chambrone LA, Lima L a. Root-coverage procedures for the treatment of localized recession-type defects: a Cochrane systematic review. *The Journal of periodontology*. 2010;81(4):452-478. doi:10.1902/jop.2010.090540.
7. Gobbato L, Nart J, Bressan E, Mazzocco F, Paniz G, Lops D. Patient morbidity and

- root coverage outcomes after the application of a subepithelial connective tissue graft in combination with a coronally advanced flap or via a tunneling technique: a randomized controlled clinical trial. *Clinical oral investigations*. 2016;20(8):2191-2202. doi:10.1007/s00784-016-1721-7.
8. Moreira ARO, Santamaria MP, Silvério KG, et al. Coronally advanced flap with or without porcine collagen matrix for root coverage: a randomized clinical trial. *Clinical Oral Investigations*. 2016:1-11. doi:10.1007/s00784-016-1757-8.
 9. McGuire MK, Scheyer ET. Xenogeneic collagen matrix with coronally advanced flap compared to connective tissue with coronally advanced flap for the treatment of dehiscence-type recession defects. *The Journal of periodontology*. 2010;81(8):1108-1117. doi:10.1902/jop.2010.090698.
 10. Jepsen K, Jepsen S, Zucchelli G, et al. Treatment of gingival recession defects with a coronally advanced flap and a xenogeneic collagen matrix: A multicenter randomized clinical trial. *Journal of Clinical Periodontology*. 2013;40(1):82-89. doi:10.1111/jcpe.12019.
 11. Cairo F, Pagliaro U, Nieri M. Treatment of gingival recession with coronally advanced flap procedures: a systematic review. *Journal of clinical periodontology*. 2008;35(8 Suppl):136-162. doi:10.1111/j.1600-051X.2008.01267.x.
 12. Koop R, Merheb J, Quirynen M. Periodontal Regeneration With Enamel Matrix Derivative in Reconstructive Periodontal Therapy: A Systematic Review. *Journal of Periodontology*. 2012;83(June):707-720. doi:10.1902/jop.2011.110266.
 13. McGuire MK, Scheyer ET, Schupbach P. A Prospective, Cased-Controlled Study Evaluating the use of Enamel Matrix Derivative on Human Buccal Recession Defects: A Human Histologic Examination. *Journal of Periodontology*. 2016:1-34.

doi:10.1902/jop.2016.150459.

14. Sallum E a., Pimentel SP, Saldanha JB, et al. Enamel Matrix Derivative and Guided Tissue Regeneration in the Treatment of Dehiscence-Type Defects: A Histomorphometric Study in Dogs. *Journal of Periodontology*. 2004;75(October):1357-1363. doi:10.1902/jop.2004.75.10.1357.
15. Cairo F, Nieri M, Cattabriga M, et al. Root coverage esthetic score after treatment of gingival recession: an interrater agreement multicenter study. *The Journal of periodontology*. 2010;81(12):1752-1758. doi:10.1902/jop.2010.100278.
16. De Sanctis M, Zucchelli G. Coronally advanced flap: A modified surgical approach for isolated recession-type defects: Three-year results. *Journal of Clinical Periodontology*. 2007;34:262-268. doi:10.1111/j.1600-051X.2006.01039.x.
17. Spahr A, Haegewald S, Tsoulfidou F, et al. Coverage of Miller class I and II recession defects using enamel matrix proteins versus coronally advanced flap technique: a 2-year report. *The Journal of periodontology*. 2005;76(November):1871-1880. doi:10.1902/jop.2005.76.11.1871.
18. Roman a., Soancă a., Kasaj a., Stratul SI. Subepithelial connective tissue graft with or without enamel matrix derivative for the treatment of Miller class I and II gingival recessions: A controlled randomized clinical trial. *Journal of Periodontal Research*. 2013;48:563-572. doi:10.1111/jre.12039.
19. Cairo F, Nieri M, Pagliaro U. Efficacy of periodontal plastic surgery procedures in the treatment of localized facial gingival recessions. A systematic review. *Journal of clinical periodontology*. 2014;41 Suppl 1:S44-62. doi:10.1111/jcpe.12182.
20. Cardaropoli D, Tamagnone L, Roffredo A, Gaveglione L. Treatment of Gingival

- Recession Defects Using Coronally Advanced Flap With a Porcine Collagen Matrix Compared to Coronally Advanced Flap With Connective Tissue Graft: A Randomized Controlled Clinical Trial. *Journal of Periodontology*. 2012;83(March):321-328. doi:10.1902/jop.2011.110215.
21. Del Pizzo M, Zucchelli G, Modica F, Villa R, Debernardi C. Coronally advanced flap with or without enamel matrix derivative for root coverage: A 2-year study. *Journal of Clinical Periodontology*. 2005;32(11):1181-1187. doi:10.1111/j.1600-051X.2005.00831.x.
 22. Cordaro L, di Torresanto VM, Torsello F. Split-mouth comparison of a coronally advanced flap with or without enamel matrix derivative for coverage of multiple gingival recession defects: 6- and 24-month follow-up. *The International journal of periodontics & restorative dentistry*. 2012;32:e10-20. <http://www.ncbi.nlm.nih.gov/pubmed/22254230>.
 23. Alkan E a., Parlar a. EMD or subepithelial connective tissue graft for the treatment of single gingival recessions: A pilot study. *Journal of Periodontal Research*. 2011;46(1):637-642. doi:10.1111/j.1600-0765.2011.01381.x.
 24. Moses O, Artzi Z, Sculean A, et al. Comparative study of two root coverage procedures: a 24-month follow-up multicenter study. *Journal of periodontology*. 2006;77(2):195-202. doi:10.1902/jop.2006.050008.
 25. Rasperini G, Rocuzzo M, Francetti L, Acunzo R, Consonni D, Silvestri M. Subepithelial connective tissue graft for treatment of gingival recessions with and without enamel matrix derivative: a multicenter, randomized controlled clinical trial. *The International journal of periodontics & restorative dentistry*. 2011;31(2):133-139.
 26. McGuire M, Scheyer E, Nunn ME. Evaluation of Human Recession Defects Treated

- With Coronally Advanced Flaps and Either Enamel Matrix Derivative or Connective Tissue: Comparison of Clinical Parameters at 10 Years. *J Periodontol*. 2012;83(November):1353-1362.
27. McGuire MK, Scheyer ET, Nunn M. Evaluation of human recession defects treated with coronally advanced flaps and either enamel matrix derivative or connective tissue: comparison of clinical parameters at 10 years. *Journal of periodontology*. 2012;83(11):1353-1362. doi:10.1902/jop.2012.110373.
28. Sculean A, Windisch P, Szendrői-Kiss D, et al. Clinical and histologic evaluation of an enamel matrix derivative combined with a biphasic calcium phosphate for the treatment of human intrabony periodontal defects. *The Journal of periodontology*. 2008;79(October):1991-1999. doi:10.1902/jop.2008.080009.
29. Corrêa MG, Gomes Campos ML, Marques MR, Casati MZ, Nociti FH, Sallum E a. Histometric Analysis of the Effect of Enamel Matrix Derivative on the Healing of Periodontal Defects in Diabetic Rats. *Journal of periodontology*. 2012;1:1-18. doi:10.1902/jop.2012.120354.
30. Henriques PSG, Pelegrine AA, Nogueira AA, Borghi MM. Application of subepithelial connective tissue graft with or without enamel matrix derivative for root coverage: a split-mouth randomized study. *Journal of oral science*. 2010;52(3):463-471.
31. Aroca S, Keglevich T, Nikolidakis D, et al. Treatment of class III multiple gingival recessions: a randomized-clinical trial. *Journal of clinical periodontology*. 2010;37(1):88-97. doi:10.1111/j.1600-051X.2009.01492.x.
32. Bernimoulin JP, Son S, Regolati B. Biometric comparison of three methods for determining the mucogingival junction. *Helvetica odontologica acta*. 1971;15(2):118-120.

33. Ahmedbeyli C, Ipci SD, Cakar G, Kuru BE, Yilmaz S. Clinical evaluation of coronally advanced flap with or without acellular dermal matrix graft on complete defect coverage for the treatment of multiple gingival recessions with thin tissue biotype. *Journal of clinical periodontology*. 2014;41(3):303-310. doi:10.1111/jcpe.12211.

3 CONCLUSÃO

Diante dos resultados apresentados, pode-se concluir que o retalho posicionado coronariamente associado à matriz de colágeno xenógena, proteínas da matriz do esmalte ou a associação destes; apresentaram melhores resultados clínicos em relação a redução da recessão gengival quando comparados ao retalho posicionado coronariamente sem biomateriais. Além disso, a utilização de apenas proteínas derivadas da matriz do esmalte alcançou maior porcentagem de sítios com recobrimento completo quando comparados aos outros tratamentos. A utilização da matriz de colágeno xenógena foi associada a um ganho significativo de espessura gengival. A associação dos biomateriais não promoveu benefícios adicionais para o tratamento das recessões gengivais.

REFERÊNCIAS

- Allen EP, Miller PDJ. Coronal positioning of existing gingiva: short term results in the treatment of shallow marginal tissue recession. *Journal of periodontology*. UNITED STATES; 1989 Jun;60(6):316–9.
- Atieh MA, Alsabeeha N, Tawse-Smith A, Payne AGT. Xenogeneic collagen matrix for periodontal plastic surgery procedures: A systematic review and meta-analysis. *Journal of Periodontal Research*. 2015;438–52.
- Berlucchi I, Francetti L, Del Fabbro M, Testori T, Weinstein RL. Enamel matrix proteins (Emdogain) in combination with coronally advanced flap or subepithelial connective tissue graft in the treatment of shallow gingival recessions. *The International journal of periodontics & restorative dentistry*. United States; 2002 Dec;22(6):583–93.
- Buti J, Baccini M, Nieri M, La Marca M, Pini-Prato GP. Bayesian network meta-analysis of root coverage procedures: Ranking efficacy and identification of best treatment. *Journal of Clinical Periodontology*. 2013;40:372–86.
- Cairo F, Nieri M, Pagliaro U. Efficacy of periodontal plastic surgery procedures in the treatment of localized facial gingival recessions. A systematic review. *Journal of clinical periodontology* [Internet]. 2014;41 Suppl 1:S44-62. Available from: <http://www.ncbi.nlm.nih.gov/pubmed/24641000>
- Cairo F, Pagliaro U, Buti J, Baccini M, Graziani F, Tonelli P, et al. Root coverage procedures improve patient aesthetics. A systematic review and Bayesian network meta-analysis. *Journal of Clinical Periodontology* [Internet]. 2016;965–75. Available from: <http://doi.wiley.com/10.1111/jcpe.12603>
- Cairo F, Pagliaro U, Nieri M. Treatment of gingival recession with coronally advanced flap procedures: a systematic review. *Journal of clinical periodontology*. Denmark; 2008 Sep;35(8 Suppl):136–62.
- Chambrone L, Tatakis DN. Periodontal Soft Tissue Root Coverage Procedures: A Systematic Review From the AAP Regeneration Workshop. *Journal of Periodontology* [Internet]. 2015;86(2–s):S8–51. Available from: <http://www.joponline.org/doi/10.1902/jop.2015.130674>
- Corrêa MG, Gomes Campos ML, Marques MR, Casati MZ, Nociti FH, Sallum E a. Histometric Analysis of the Effect of Enamel Matrix Derivative on the Healing of Periodontal Defects in Diabetic Rats. *Journal of periodontology* [Internet]. 2012;1:1–18. Available from: <http://www.ncbi.nlm.nih.gov/pubmed/23121457>
- Côrtes ADQ, Martins AG, Nociti FH, Sallum AW, Casati MZ, Sallum EA. Coronally positioned flap with or without acellular dermal matrix graft in the treatment of Class I gingival recessions: a randomized controlled clinical study. *Journal of periodontology* [Internet]. 2004;75(8):1137–44. Available from: <http://www.ncbi.nlm.nih.gov/pubmed/15455743>
- Fujita T, Yamamoto S, Ota M, Shibukawa Y, Yamada S. Coverage of gingival recession defects using guided tissue regeneration with and without adjunctive enamel matrix derivative in a dog model. *The International journal of periodontics & restorative dentistry*. 2011;31:247–53.
- Hammarström L, Heijl L, Gestrelus S. Periodontal regeneration in a buccal dehiscence model

in monkeys after application of enamel matrix proteins. *Journal of clinical periodontology*. 1997;24:669–77.

Harris RJ. GTR for root coverage: a long-term follow-up. *The International journal of periodontics & restorative dentistry*. *Int J Periodontics Restorative Dent*; 2002. p. 55–61.

Jepsen K, Jepsen S, Zucchelli G, Stefanini M, De Sanctis M, Baldini N, et al. Treatment of gingival recession defects with a coronally advanced flap and a xenogeneic collagen matrix: A multicenter randomized clinical trial. *Journal of Clinical Periodontology*. 2013;40(1):82–9.

Jhaveri HM, Chavan MS, Tomar GB, Deshmukh VL, Wani MR, Miller PD. Acellular dermal matrix seeded with autologous gingival fibroblasts for the treatment of gingival recession: a proof-of-concept study. *The Journal of periodontology*. 2010;81(4):616–25.

Keceli HG, Sengun D, Berberoglu A, Karabulut E. Use of platelet gel with connective tissue grafts for root coverage: a randomized-controlled trial. *Journal of clinical periodontology*. Denmark; 2008 Mar;35(3):255–62.

Kimble KM, Eber RM, Soehren S, Shyr Y, Wang H-L. Treatment of gingival recession using a collagen membrane with or without the use of demineralized freeze-dried bone allograft for space maintenance. *The Journal of periodontology*. 2004;75(2):210–20.

Koop R, Merheb J, Quirynen M. Periodontal Regeneration With Enamel Matrix Derivative in Reconstructive Periodontal Therapy: A Systematic Review. *Journal of Periodontology*. United States; 2012 Jun;83(June):707–20.

Lorenzo R, García V, Orsini M, Martin C, Sanz M. Clinical efficacy of a xenogeneic collagen matrix in augmenting keratinized mucosa around implants: A randomized controlled prospective clinical trial. *Clinical Oral Implants Research*. 2012;23:316–24.

McGuire M, Scheyer E, Nunn ME. Evaluation of Human Recession Defects Treated With Coronally Advanced Flaps and Either Enamel Matrix Derivative or Connective Tissue: Comparison of Clinical Parameters at 10 Years. *J Periodontol*. 2012;83(November):1353–62.

McGuire MK, Scheyer ET, Schupbach P. A Prospective, Cased-Controlled Study Evaluating the use of Enamel Matrix Derivative on Human Buccal Recession Defects: A Human Histologic Examination. *Journal of Periodontology* [Internet]. 2016;1–34. Available from: <http://www.joponline.org/doi/10.1902/jop.2016.150459>

Molnár B, Aroca S, Keglevich T, Gera I, Windisch P, Stavropoulos A, et al. Treatment of multiple adjacent Miller Class I and II gingival recessions with collagen matrix and the modified coronally advanced tunnel technique. *Quintessence international* (Berlin, Germany : 1985) [Internet]. 2013;44:17–24. Available from: <http://www.ncbi.nlm.nih.gov/pubmed/23627374>

Moreira ARO, Santamaria MP, Silvério KG, Casati MZ, Nociti Junior FH, Sculean A, et al. Coronally advanced flap with or without porcine collagen matrix for root coverage: a randomized clinical trial. *Clinical Oral Investigations* [Internet]. 2016;1–11. Available from: <http://link.springer.com/10.1007/s00784-016-1757-8>

Moslemi N, Mousavi Jazi M, Haghghati F, Morovati SP, Jamali R. Acellular dermal matrix allograft versus subepithelial connective tissue graft in treatment of gingival recessions: A 5-year randomized clinical study. *Journal of Clinical Periodontology*. 2011;38:1122–9.

Pourabbas R, Chitsazi MT, Kosarieh E, Olyaei P. Coronally advanced flap in combination with acellular dermal matrix with or without enamel matrix derivatives for root coverage.

Indian journal of dental research : official publication of Indian Society for Dental Research. 2015;20(3):320–5.

Rasperini G, Rocuzzo M, Francetti L, Acunzo R, Consonni D, Silvestri M. Subepithelial connective tissue graft for treatment of gingival recessions with and without enamel matrix derivative: a multicenter, randomized controlled clinical trial. *The International journal of periodontics & restorative dentistry*. 2011;31(2):133–9.

Rotundo R, Pini-Prato G. Use of a new collagen matrix (mucograft) for the treatment of multiple gingival recessions: case reports. *The International journal of periodontics & restorative dentistry* [Internet]. 2012;32:413–9. Available from: <http://www.ncbi.nlm.nih.gov/pubmed/22577647>

Sallum E a., Pimentel SP, Saldanha JB, Nogueira-Filho GR, Casati MZ, Nociti FH, et al. Enamel Matrix Derivative and Guided Tissue Regeneration in the Treatment of Dehiscence-Type Defects: A Histomorphometric Study in Dogs. *Journal of Periodontology*. 2004;75(October):1357–63.

De Sanctis M, Zucchelli G. Coronally advanced flap: A modified surgical approach for isolated recession-type defects: Three-year results. *Journal of Clinical Periodontology*. 2007;34:262–8.

Sculean A, Windisch P, Szendrői-Kiss D, Horváth A, Rosta P, Becker J, et al. Clinical and histologic evaluation of an enamel matrix derivative combined with a biphasic calcium phosphate for the treatment of human intrabony periodontal defects. *The Journal of periodontology*. 2008;79(October):1991–9.

Shin SH, Cueva M a., Kerns DG, Hallmon WW, Rivera-Hidalgo F, Nunn ME. A Comparative Study of Root Coverage Using Acellular Dermal Matrix With and Without Enamel Matrix Derivative. *Journal of Periodontology*. 2007;78(March):411–21.

Singh P, Suresh DK. Clinical evaluation of GEM 21S(®) and a collagen membrane with a coronally advanced flap as a root coverage procedure in the treatment of gingival recession defects: A comparative study. *Journal of Indian Society of Periodontology* [Internet]. 2012;16(4):577–83. Available from: <http://www.pubmedcentral.nih.gov/articlerender.fcgi?artid=3590730&tool=pmcentrez&rendertype=abstract>

Trabulsi M, Oh T-J, Eber R, Weber D, Wang H-L. Effect of enamel matrix derivative on collagen guided tissue regeneration-based root coverage procedure. *The Journal of periodontology*. 2004;75(11):1446–57.

Vignoletti F, Nuñez J, Discepoli N, De Sanctis F, Caffesse R, Muñoz F, et al. Clinical and histological healing of a new collagen matrix in combination with the coronally advanced flap for the treatment of Miller class-I recession defects: An experimental study in the minipig. *Journal of Clinical Periodontology*. 2011;38:847–55.

Zucchelli G, Mele M, Stefanini M, Mazzotti C, Marzadori M, Montebugnoli L, et al. Patient morbidity and root coverage outcome after subepithelial connective tissue and de-epithelialized grafts: A comparative randomized-controlled clinical trial. *Journal of Clinical Periodontology*. 2010;37(8):728–38.

Anexos

Anexo 1: Comprovante de submissão do artigo

Journal of Periodontology - JOP-17-0126 Has Been Submitted

1 mensagem

Journal of Periodontology <onbehalfof+julie+perio.org@manuscriptcentral.com>

20 de fevereiro de 2017 10:24

Responder a: julie@perio.org

Para: joao.sangiorgio@gmail.com

20-Feb-2017

Dear Dr. Sangiorgio:

Thank you for submitting your manuscript, "XENOGENOUS COLLAGEN MATRIX AND/OR ENAMEL MATRIX DERIVATIVE FOR TREATMENT OF LOCALIZED GINGIVAL RECESSIONS - A RANDOMIZED CLINICAL TRIAL. PART I: PRIMARY OUTCOMES." (JOP-17-0126), to the Journal of Periodontology. Your manuscript will be forwarded to Dr. Komman or an Associate Editor prior to peer review.

As a reminder, the Journal of Periodontology requires all authors to complete a conflict of interest and financial disclosure form via the submission site. You will receive a separate e-mail with information regarding the form.

You may track the status of your submission on the web at <https://mc.manuscriptcentral.com/jperio>. To access the system, you will need to login with your User ID and password. The manuscript status can be tracked in your Author Center.

If you have any questions, or if I can provide further information, please do not hesitate to contact me at julie@perio.org. It will be most helpful if you would include both your manuscript title and reference number in any correspondence.

Sincerely,

Julie Daw
Managing Editor
Journal of Periodontology
E-mail: julie@perio.org
<https://mc.manuscriptcentral.com/jperio>



COMITÊ DE ÉTICA EM PESQUISA
FACULDADE DE ODONTOLOGIA DE PIRACICABA
UNIVERSIDADE ESTADUAL DE CAMPINAS



CERTIFICADO

O Comitê de Ética em Pesquisa da FOP-UNICAMP certifica que o projeto de pesquisa **"Enxerto de matriz de colágeno xenôgena associado ou não à proteína derivada da matriz do esmalte no tratamento de recessão gengival classe I e II de Miller: estudo clínico controlado randomizado"**, protocolo nº 067/2013, dos pesquisadores João Paulo Menck Sangiorgio e Enilson Antonio Sallum, satisfaz as exigências do Conselho Nacional de Saúde - Ministério da Saúde para as pesquisas em seres humanos e foi aprovado por este comitê em 23/09/2013.

The Ethics Committee in Research of the Piracicaba Dental School - University of Campinas, certify that the project **"Xenogenous collagen matrix graft associated or not with enamel matrix derivative proteins in the treatment of gingival recession class I and II of Miller: randomized controlled clinical study"**, register number 067/2013, of João Paulo Menck Sangiorgio and Enilson Antonio Sallum, comply with the recommendations of the National Health Council - Ministry of Health of Brazil for research in human subjects and therefore was approved by this committee on Sep 23, 2013.

Prof. Dr. Felipe Bevilacqua Prado
 Secretário
 CEP/FOP/UNICAMP

Prof. Dra. Livia Maria Andaló Tenuta
 Coordenadora
 CEP/FOP/UNICAMP

Nota: O título do protocolo aparece como fornecido pelos pesquisadores, sem qualquer edição.
 Notice: The title of the project appears as provided by the authors, without editing.