

DOI: <http://dx.doi.org/10.5281/zenodo.2541075>

# Therapeutic Effect of Fractionated by Ultrafiltration Red Beetroot (*Beta vulgaris* L.) Juice in Rats with Food-Induced Fatty Liver

D. Babarykin<sup>1\*</sup>, G. Smirnova<sup>1,2</sup>, J. Markovs<sup>3</sup>, S. Vasiljeva<sup>2</sup>, N. Basova<sup>2</sup>, R. Simanis<sup>4</sup>, L. Viksna<sup>4</sup><sup>1</sup> Institute of Innovative Biomedical Technology Ltd., Riga, Latvia<sup>2</sup> Institute of Biology of the University of Latvia, Salaspils, Latvia<sup>3</sup> Department of Anatomy and Histology, Faculty of Medicine, University of Latvia, Riga<sup>4</sup> Riga Stradins University, Riga, Latvia\* Correspondence: [dmitry.b@parks.lv](mailto:dmitry.b@parks.lv)**Received:** 07 November 2018; **Revised submission:** 26 December 2018; **Accepted:** 15 January 2019Copyright: © The Author(s) 2019. Licensee Joanna Bródka, Poland. This article is an open access article distributed under the terms and conditions of the Creative Commons Attribution (CC BY) license (<http://creativecommons.org/licenses/by/4.0/>)

**ABSTRACT:** The prevalence of non-alcoholic fatty liver disease (NAFLD), being a component of metabolic syndrome, has increased (15-27%) in the industrialized world. The deep mechanism of this pathology is not clear, but it is multifactorial. There is a huge amount of food supplements and medicines with hepatoprotective effect on the market, but the NAFLD problem is far from being resolved. Hepatoprotective products have to provide wide spectra of biological effects, including antioxidant, hypolipidemic, anti-inflammatory action. It is peculiar to natural compounds, including red beetroot juice, which is well known to most of the population. This is important in view of the high prevalence of NAFLD. The aim of this study is to evaluate the curative effect of fractionated by ultrafiltration red beetroot juice in rats with food-induced liver steatosis.

**Keywords:** Non-alcoholic liver steatosis; Hepatoprotection; Hypolipidemic effect; Red beetroot juice; Ultrafiltration; Rat.

## 1. INTRODUCTION

Non-alcoholic fatty liver disease (NAFLD) is defined as the presence of hepatic macro-vesicular fat accumulation after exclusion of other causes of liver steatosis. NAFLD encompasses a broad clinical spectrum ranging from fatty liver to fibrosis, cirrhosis and hepato-cellular carcinoma. Ongoing persistence of obesity with an increasing rate of diabetes will increase the prevalence of NAFLD. There has been a general increase in the prevalence of NAFLD, with Asia leading the rise, yet the United States is following closely behind with a rising prevalence from 15% in 2005 to 25% within 5 years [1]. NAFLD (a civilization disease!) has a prevalence of 25-30% in unselected populations and has become the main reason for referrals to hepatology services [2].

NAFLD is commonly associated with metabolic syndrome, obesity, diabetes and hyperlipidemia. Nearly 80% of patients with metabolic syndrome have NAFLD [3]. Epigenetics, an inheritable phenomenon that affects gene expression without altering at the DNA sequence [4], dietary factors and especially high

fructose consumption play a role in NAFLD development [5].

NAFLD in children also is becoming a major health concern. The prevalence of NAFLD in children is 8% in the general population and 34% in the context of obesity [6]. A “multiple-hit” pathogenetic model has been suggested to explain the progressive liver damage. In addition to the accumulation of fat in the liver, insulin resistance and oxidative stress due to a genetic/epigenetic background, unfavorable lifestyles, gut microbiota, and perturbances of trace element homeostasis have been shown to be critical for disease progression. Currently there are no approved agents available for the treatment of NAFLD. Effective pharmacological treatments are still under development [7]

It is logical that for a solution of a global problem such as NAFLD, attempts are made to use natural compounds: specific activity has been studied for *Schisandra sinensis* [8], Chinese traditional medicine herbal formulations [9] as well as carotenoids [10], curcumin derivatives [11] as well as omega-3 fatty acids, flavonoids, isothiocyanates and many other phytochemicals [12].

It is known that red beetroot juice provides a hepatoprotective effect. First of all, it was demonstrated on toxic hepatitis experimental models. Long term feeding with beetroot juice showed the protective effect of *Beta vulgaris* against oxidative liver damage, induced by hepatocarcinogenic N-nitrosodiethylamine (NDEA) in rats. [13]. It was reported, that beetroot could be used for the treatment and prevention of alcoholic liver disease [14], one of the pathogenesis mechanisms of which is fat accumulation in liver cells.

To check how red beetroot juice impacts cell fat metabolism, we used rat bone marrow stromal mesenchymal multipotent cells (BMSMMC), i.e. stem cell cultures [15], as a model. It is known that BMSMMC differentiate into a variety of cell types, including osteoblasts (bone cells), chondrocytes (cartilage cells) and adipocytes (fat cells). The direction of BMSMMC differentiation may be modulated by adding to the cultivation medium, including phytochemicals [16]. Native and fractionated by ultrafiltration red beetroot juice cut-off-points 100 KDa) were tested regarding the *in vitro* differentiation of the cells mentioned. It was found, unlike native red beetroot juice, the fractionated one significantly suppressed stem cell adipogenic and stimulated osteogenic differentiation [15].

Fractionated red beetroot juice (FRBJ) chemical composition is as follows (in 100 ml): betacyanins 70 mg, vulgaxantin-I 40 mg, betain 350 mg, sucrose 5.6 g, lysozyme 1.2 mg, phenolic compounds total 145 GAE (in gallic acid equivalent) [17].

The above mentioned fact about the FRBJ effect on stem cell differentiation *in vitro* led us to evaluate the therapeutic effect of FRBJ on laboratory animals with food-induced fatty liver. Note that we were not in a position to induce liver steatosis neither with a high-fat diet nor with hepatotoxic chemicals, but with excessive feeding, which is more analogous to the lifestyle of target group patients. On the other hand, we proceeded from the fact that red beetroot contains some potent antioxidants as well as other substances and has antianemic, anticarcinogenic, antipyretic, detoxicant, vasoactive, lipotropic and antibacterial properties. Additionally, the NAFLD problem is global in nature, it affects people of all ages; it means the product for prevention and treatment of this pathology has to be safe and widely available. The objective of our study was to evaluate the long term curative effect via oral ingestion of fractionated by ultrafiltration red beetroot juice in rats with experimental food-induced fatty liver.

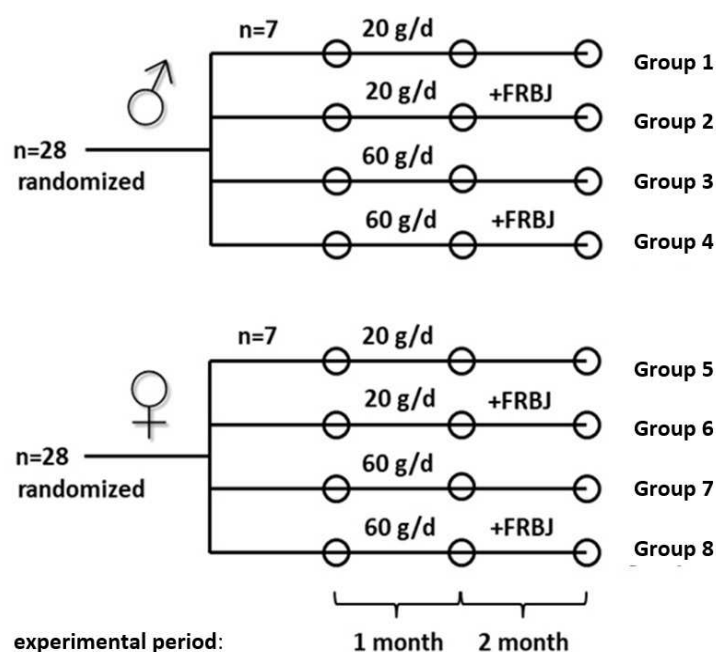
## 2. MATERIALS AND METHODS

### 2.1. Animals

Randomized Wistar rats were used: both sexes, 5 weeks old with body mass 182-189 g. Before experiments rats were acclimatized and housed in a standard rodent cage at a temperature of 21-23°C and a dark-light cycle 12 h/12 h. The experiment was approved by the local Animal Ethics Committee Service (Riga, Latvia, authorization reference number 13, December 22, 2008).

## 2.2. Study design

Rats were divided randomly into 8 groups of 7 heads each (Fig. 1). For 30 days the rats were fed standard diet (protein 20%, total fat 4,8 %, carbohydrate 59,4%, fibre 13%, energy value 14,0 MJ/kg). For the next 30 days the rats consumed a diet in doses 20 g/day (Groups 1, 2, 5, 6) or 60 g/day (Groups 3, 4, 7, 8) to induce animal obesity. Drinking water was provided *ad libitum*. From the 31<sup>st</sup> to 60<sup>th</sup> day the rats of Groups 1, 3, 5, 7 continued receive the standard diet only, and the rats of Groups 2, 4, 6, 8 obtained additionally *per os* 1 ml of fractionated red beetroot juice (FRBJ), prepared as it was described [17]. At the end of experiment, on the 60<sup>th</sup> day, the animals were weighted, blood samples were taken for biochemical analyses. Rats were euthanized by the method of cervical dislocation [18]. Retroperitoneal, paraepididymic, abdominal, as well as inguinal fat, was collected and weighed after rat mortification.



**Figure 1.** Experimental design. Groups 1, 2, 5, 6 consumed diet 20 g daily (intact rats), Groups 3, 4, 7, 8 consumed diet 60 g daily (obese rats). FRBJ – fractionated red beetroot juice, given *per os* 1 ml to each animal.

## 2.3. Blood analysis

At the end of experiment heparinized venous blood from each rat was analyzed for biochemical parameters (blood serum, glucose, triglycerides, albumin, total cholesterol as well as HDL-C and LDL-C, alanine aminotransferase (ALT) and aspartate aminotransferase (AST) performed on a ILAB 300+ analyzer (Instrumentation Laboratory, USA).

## 2.4. Histological study

Liver specimens were fixed in 10% formaldehyde, dehydrated in ascending grades of ethanol and embedded in paraffin, sections stained with hematoxyllin (Bio Optica) and eosin (Dia-Path) and PAS-reaction for glycogen and then examined under light microscopy. Histological analysis was performed by a blinded observer. Steatosis was defined as mild (5%-33% of hepatocytes affected), moderate (33%-66%) and severe (>66%).

## 2.5. Statistical analysis

All statistics were performed using the software Statistica 7. Results of body weight and visceral fat

mass of rats and biochemical parameters are presented as means± SE. Multiple group comparison was done using *one-way ANOVA* and *Post-hoc* Tukey HSD test.

### 3. RESULTS

In two months body mass of control rats was 265±5 g (female) and 324±6 g (male) (Table 1). FRBJ ingestion by intact rats (Groups 2 and 6) induced blood glucose concentration, visceral fat mass and body weight increase, but did not impair the blood lipid level. Due to the high energy value of FRBJ, the body weight in male rats (Group 2) increased.

**Table 1.** Impact of fractionated red beetroot juice (FRBJ) on body weight and visceral fat mass of intact rats and animals with experimental obesity at the end of experiment.

Animals	Male				Female			
	Group	Body weight, g	**Body weight gain, g	Visceral fat mass, g	Group	Body weight, g	**Body weight gain, g	Visceral fat mass, g
Intact rats	1	324±6 <sup>a*</sup>	61±3 <sup>a</sup>	11.9±0.2 <sup>a</sup>	5	265±5 <sup>a</sup>	29±2 <sup>a</sup>	10.1±0.1 <sup>a</sup>
Intact rats + FRBJ	2	345±8 <sup>b</sup>	72±4 <sup>b</sup>	12.9±0.5 <sup>b</sup>	6	265±7 <sup>a</sup>	33±3 <sup>a</sup>	11.0±0.2 <sup>a</sup>
Obese rats	3	406±10 <sup>c</sup>	104±2 <sup>c</sup>	14.3±0.4 <sup>c</sup>	7	286±4 <sup>b</sup>	48±2 <sup>b</sup>	15.9±0.1 <sup>b</sup>
Obese rats+ FRBJ	4	436±8 <sup>d</sup>	64±2 <sup>a</sup>	12.1±0.4 <sup>a,b</sup>	8	264±8 <sup>a</sup>	18±3 <sup>c</sup>	10.9±0.2 <sup>a</sup>

\*Statistically different or similar within column according to *Post-hoc* Tukey HSD test (p< 0.05)  
\*\* Body weight gain for the period of 31 – 60 days of the experiment.

**Table 2.** Effect of fractionated red beetroot juice (FRBJ) on blood biochemical indices in intact rats and animals with experimental obesity.

Group	Albumin g/l	ALT IU/l	AST IU/l	Glucose mmol/l	Total cholesterol mmol/l	HDL-C mmol/l	LDL-C mmol/l	Triglycerides mmol/l
Male								
1 (intact)	44± 2 <sup>a</sup>	59 ± 7 <sup>a</sup>	146± 7 <sup>a</sup>	4.5 ±0.3 <sup>a</sup>	2.0 ± 0.2 <sup>a</sup>	1.4± 0.1 <sup>a</sup>	1.0± 0.2 <sup>a</sup>	0.9± 0.2 <sup>a</sup>
2 (intact+FRBJ)	42 ±1 <sup>a</sup>	55± 6 <sup>a</sup>	159± 7 <sup>a</sup>	5.2± 0.4 <sup>a,b</sup>	1.9 ± 0.2 <sup>a</sup>	1.3± 0.2 <sup>a</sup>	1.1± 0.2 <sup>a</sup>	1.0± 0.2 <sup>a</sup>
3 (obese)	41±2 <sup>a</sup>	61± 7 <sup>a</sup>	144± 5 <sup>b</sup>	6.0±0.6 <sup>b</sup>	1.8 ± 0.2 <sup>a</sup>	1.1±0.1 <sup>b</sup>	1.4± 0.2 <sup>a</sup>	1.6±0.1 <sup>b</sup>
4 (obese+FRBJ)	43±3 <sup>a</sup>	58± 5 <sup>b</sup>	132± 6 <sup>b</sup>	6.0±0.7 <sup>b</sup>	1.5 ± 0.1 <sup>b</sup>	1.1±0.2 <sup>a</sup>	1.2±0.2 <sup>a</sup>	1.4±0.2 <sup>ab</sup>
Female								
5 (intact)	44 ±1 <sup>a</sup>	53± 4	139± 6 <sup>a</sup>	5.4±1.3 <sup>a</sup>	1.7± 0.0 <sup>a</sup>	1.1 ±0.1 <sup>a</sup>	0.9± 0.1 <sup>a</sup>	1.0 ±0.2 <sup>a</sup>
6 (intact+FRBJ)	45± 2 <sup>a</sup>	44± 4	123± 5 <sup>b</sup>	6.2± 0.8 <sup>a</sup>	1.9±0.2 <sup>a</sup>	1.1± 0.2 <sup>ab</sup>	1.3± 0.4 <sup>a</sup>	1.0± 0.4 <sup>ab</sup>
7 (obese)	45±1 <sup>a</sup>	41± 7	145± 3 <sup>a</sup>	7.5±0.9 <sup>a</sup>	1.5± 0.3 <sup>a</sup>	1.2± 0.2 <sup>ab</sup>	1.0± 0.2 <sup>a</sup>	1.6± 0.3 <sup>b</sup>
8 (obese+FRBJ)	45±1 <sup>a</sup>	42± 9	106± 6 <sup>a</sup>	7.4±0.6 <sup>a</sup>	1.6±0.1 <sup>a</sup>	1.4± 0.1 <sup>b</sup>	0.7± 0.1 <sup>a</sup>	0.6± 0.2 <sup>a</sup>

\*Statistically different or similar within column according to *Post-hos* Tukey HSD test (p< 0.05)

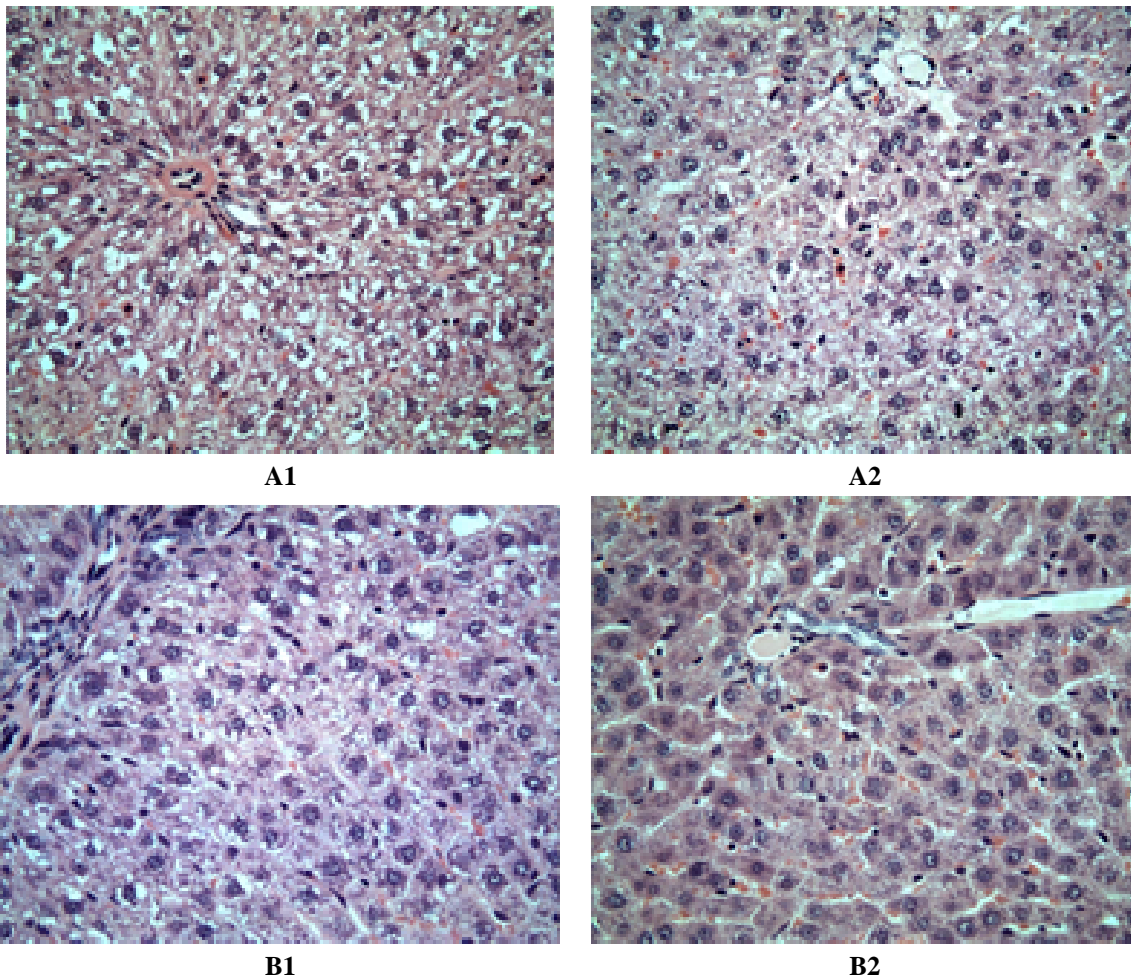
Feed overconsumption caused body weight increase: at the end of the experiment, the body weight of animals in Groups 3 and 7 exceeded the control level (Groups 1 and 5) by 25% and 8% respectively. After FRBJ administration, obese rats demonstrated weight gain retardation, as well as visceral fat mass drop, especially in female rats. This effect was not correlated with the quantity of consumed feed: male rats feed consumption with and without FRBJ were 22.4 vs. 22.5 g/day and female – 23.0 vs. 22.6 g/day.

FRBJ ingestion by obese animals caused their blood triglyceride concentration to fall dramatically, by

60% (females), the proportion of cholesterol fractions HDL-C/LDL-C changed from 1.20 to 2.12, although the total cholesterol level did not change (Table 2). This fact is the basis for the speculation that using FRBJ diminishes the risk of atherosclerosis.

Histological analysis of the liver samples for Groups 1 and 5 (standard diet fed) showed normal hepatic architecture without any evidence of hepatic steatosis. At the same time, FRBJ supplementation to the standard diet (Groups 2 and 6) caused the appearance of empty vacuoles within the hepatocyte cytoplasm, but the number of these cells did not exceed 2%. In contrast, livers from the animals of Group 3 (male obese rats) had macro- and micro-vesicular steatosis. These changes were most marked in the portal and midzone hepatocytes.

These animals also showed minimal to no periportal inflammation and fibrosis. Steatosis for Group 7 (female obese rats) was most prominent within periportal hepatocytes and less prominent in the midzone hepatocytes. In Groups 3 and 7 liver specimen steatosis was classified as moderate to severe (Fig. 2, A1, B1). FRBJ ingestion significantly eliminated hepatic steatosis in female obese rats (Group 8) and, to a lesser extent, in male obese rats (Group 4) (Fig. 2, B2, A2). Hepatocytes with variably sized cytoplasmic vacuoles were rarely encountered in livers from the former experimental group. The majority of Group 7 specimens had no portal inflammation.



**Figure 2.** Photomicrograph (H&E.X20) of liver of male (A) and female (B) obese rats. A1: liver of obese rats is with marked periportal steatosis (Group3). A2: many hepatocytes in rats, given fractionated red beetroot juice (FRBJ), contain moderate sized cytoplasmic vacuoles (Group 4). B1: moderate micro-vesicular steatosis in obese rats (Group 7). B2: only few and small cytoplasmic lipid droplets are in rats, given fractionated red beetroot juice (FRBJ) (Group 8).

#### 4. DISCUSSION

The experiments on the rats showed that FRBJ brakes obese body weight gain, visceral fat mass and improves the blood cholesterol fraction HDL-C/LDL-C proportion as well. NAFLD is associated with the components of metabolic syndrome and, especially, visceral obesity which seems to be an important etiological factor [19]. During one month of FRBJ use, it diminished blood triglyceride concentration and caused histo-morphologically proven liver release of fat excess.

What could be the explanation of red beetroot lipotropic and hepatoprotective effects? In the opinion of Hashem et al. [20] this phenomenon is associated with the action of two novel flavonoids, isolated from *Beta vulgaris* leaves, that showed hepato-protective effects in rats on high-fat-diets, provided a positive effect on the blood lipid profile, liver function enzymes and the histopathological picture.

It seems FRBJ specific activity is related to not one but several substances. Here it is appropriate to mention data that in the rats with high-fat induced non-alcoholic fatty liver disease, the polysaccharide fraction isolated from chicory (*Chicorium intybus*) significantly ameliorated symptoms of NAFLD [21]. One of the components in our tested red beetroot juice fraction with a curative effect may be betaine. FRBJ contains betaine by 17% more than does native red beetroot juice [17]. Betaine provides a hepato-protective effect in mice on a high-fat diet. This effect is related to betaine's capability to impact insulin functions via intracellular insulin-depending signal transduction as well as reduce liver and other organs and tissue cells insulin resistance [22].

Another explanation of FRBJ specific effects may be as follows: some substances or their composition may be activated after some inhibitors are removed during juice processing by ultrafiltration. Attention is drawn to the fact that FRBJ also increased body weight gain in intact male rats (Group 2). This anabolic effect (visceral fat mass was not changed (Table 2) is likely a result of a testosterone-mediated increase in muscle mass. Betaine has been shown to increase muscle mass and reduce fat mass or both in poultry and pigs [23]. Testosterone is a key regulator of protein synthesis [24]. Furthermore, obesity decreases testosterone production [25].

The results of our histo-morphological liver study show that the severity of NAFLD in males was higher than in females. From the other side the data indicated more pronounced therapeutic effect of FRBJ on lipid metabolism in rat obese females than males. This coincides with the data about the prevalence of hepatic steatosis being significantly higher in boys (41.1%) than in girls (17.2%). The authors suggest significant association of NAFLD with markers of visceral obesity and insulin resistance in both genders and gender-specific associations with parameters of body fat distribution and sex steroids [26].

In the present study, FRBJ supplementation during 30 days decreased weight gain in obese rats, at least partly, due to the ability of betaine to decrease fat mass [27]. FRBJ ingestion probably also induces other mechanisms responsible for fat synthesis and accumulation in tissues.

A two-hit hypothesis has been proposed to understand the pathogenesis of NAFLD: the first hit includes excess fat accumulation in the liver, and the second hit consists of oxidative stress and lipid peroxidation with increased generation of inflammatory cytokines [28]. Perhaps, at least partially, the hepato-protective FRBJ effect is related to the *Beta vulgaris* anti-inflammatory effect [29]. In our study, the maximal protective effect was found in animal Group 8 (Fig. 5) with histo-morphologically proven minimal portal inflammation.

It is known that one of the liver steatosis pathogenetic factors is oxidative stress and antioxidants provide hepato-protective action. FRBJ contains the pigment betalain which consists of two main components: violet/red and yellow pigments – betacyanins and betaxantins, whose antioxidant effect exceeds their anthocyanin activity [30]. *Beta vulgaris* red pigment [31], as well as the yellow one [32], has the capacity to neutralize free radicals. An interesting conclusion was made by Rahimi et al. [33]: betalains from red beetroot, as well as from fruit of the *Opuntia* genus of cacti, provide an anti-dyslipidemic effect.



Nevertheless, it must be recognized that the hypolipidemic activity mechanism of red beetroot products remains unclear. To explain them via an antioxidative *Beta vulgaris* effect only is not possible.

Beetroot product (crisps) diminish total serum cholesterol and triacylglycerol level in rats on a dyslipidemic diet, and modify *caecum* activity, altering intensification of *caecum* fermentation [34]. Intestinal host – microbiome interactions play diverse roles in the pathogenesis and progression of NAFLD [35]. One of the FRBJ hepato-protection mechanisms may be related to the products antibacterial effect on gut microbiota, first of all due to lysozyme, whose concentration in FRBJ is by 19% *higher*, than in native red beetroot juice. Excessive intestinal microflora may be a cause of abnormal fat accumulation in tissues [36].

It is an important fact that in our study specific efficacy of FRBJ has been shown in laboratory animals fed with standard, but not high-fat feed. Our NAFLD experimental model was closer to the essence of human pathology. In total, FRBJ supplementation leads to a marked biochemical and histological improvement in decreasing of excessive hepatic fat accumulation and lipid metabolism in obese rats.

## 5. CONCLUSION

A hepato-protective and a hypo-lipidemic effect of FRBJ is probably the result of the complex activity of betalains, betaine as well as other identified and not identified compounds, where not only chemical class of the substances matters, but also its proportion as well as the absence of some inhibitors removed by ultrafiltration.

We suppose FRBJ will be good base for safe and effective medicines, dietary supplements and functional food for prevention and treatment of metabolic syndrome, dyslipidemia, adiposity, liver steatosis and other pathology.

**Author Contributions:** BD designed research, analyzed the data and wrote manuscript, VS and BN performed experiments and biochemical analysis, SG provided red beetroot juice fractionation, statistical analysis and drafting of the manuscript, MJ made liver histomorphological study and critical revision of the manuscript for important intellectual content, SR and VL studied blood biochemical indices dynamics, interpretation of the data. All authors read and approved the final manuscript.

**Funding:** The Project is executed in accordance with the contract 1.2.1.1/16/A/004 between "Competence Centre for Food in Latvia" Ltd. and the Central Finance and Contracting Agency, with support from the European Regional Development Fund.

**Conflict of Interest:** The authors declare no competing interest concerning any commercial associations or patent licenses.

## REFERENCES

1. Perumpail BJ, Khan MA, Yoo ER, Cholankeril G, Kim D, Ahmed A. Clinical epidemiology and disease burden of nonalcoholic fatty liver disease. *World J Gastroenterol.* 2017; 23(47): 8263-8276.
2. Tsochatzis EA, Newsome PN. Non-alcoholic fatty liver disease and the interface between primary and secondary care. *Lancet Gastroenterol Hepatol.* 2018; 3: 509-517.
3. Antunes C, Bhimji SS. Fatty liver. StatPearls Publishing; 2018. Retrieved from: <https://www.ncbi.nlm.nih.gov/books/NBK441992>
4. Lee J, Kim Y, Friso S, Choi SW. Epigenetics in non-alcoholic fatty liver disease. *Mol Aspects Med.* 2017; 54: 78-88.
5. Alwahsh SM, Gebhardt R. Dietary fructose as a risk factor for non-alcoholic fatty liver disease (NAFLD). *Arch Toxicol.* 2017; 91: 1545-1563.

6. Dhaliwal J, Chavhan GB, Lurz E, Shalabi A, Yuen N, Williams B, et al. Hepatic steatosis is highly prevalent across the pediatric age spectrum, including in pre-school age children. *Aliment Pharmacol Ther.* 2018; 48: 556-563.
7. Clemente MG, Mandato C, Poeta M, Vajro P. Pediatric non-alcoholic fatty liver disease: Recent solutions, unresolved issues, and future research directions. *World J Gastroenterol.* 2016; 22: 8078-8093.
8. Park HJ, Lee SJ, Song Y, Jang SH, Ko YG, Kang SN, et al. *Schisandra chinensis* prevents alcohol-induced fatty liver disease in rats. *J Med Food.* 2014; 17: 103-110.
9. Liu J, Zhang H, Ji B, Cai S, Wang R, Zhou F, et al. A diet formula of Puerariae radix, *Lycium barbarum*, *Crataegus pinnatifida*, and Polygonati rhizoma alleviates insulin resistance and hepatic steatosis in CD-1 mice and HepG2 cells. *Food Func.* 2014; 5: 1038-1049.
10. Yilmaz B, Sahin, K, Bilen H, Bahcecioglu IH, Bilir B, Ashraf S, et al. Carotenoids and non-alcoholic fatty liver disease. *Hepatobiliary Surg Nutr.* 2015; 4: 161-171.
11. Kim SB, Kang OH, Lee YS, Han SH, Ahn YS, Cha SW, et al. Hepatoprotective effect and synergism of bisdemethoxy curcumin against MCD diet-Induced nonalcoholic fatty liver disease in mice. *PLoS One.* 2016; 11(2): e0147745.
12. Pan MH, Lai CS, Tsai M, Ho CT. Chemoprevention of nonalcoholic fatty liver disease by dietary natural compounds. *Mol Nutr Food Res.* 2014; 58: 147-171.
13. Krajka-Kuźniak V, Szaefer H, Ignatowicz E, Adamska T, Baer-Dubowska W. Beetroot juice protects against N-nitrosodiethylamine-induced liver injury in rats. *Food Chem Toxicol.* 2012; 50: 2027-2033.
14. Firdous H, Hussain T, Singh M, Rizvi SMD, Moin A, Kamal MA. Preclinical hepatoprotective effect of herbalism against ethanol induced hepatotoxicity: a review. *Curr Drug Metab.* 2018; 19(12): 1002-1011.
15. Babarykin D, Krumina G, Paegle I, Suhorukov O, Nikulshin S, Krumina Z, et al. Inhibition the adipogenic differentiation of bone marrow stromal mesenchymal cells (BMSMC) by Chenopodiaceae family cultivated plant juice. In: 5th Int. Conf. Mesenchymal and Non-Hematopoietic Stem Cells (MSCs). Austin, Tx, USA. Abstracts, 12-14 Nov. 2009: 11.
16. Kornicka K, Kocherova I, Marycz K. The effects of chosen plant extracts and compounds on mesenchymal stem cells-a bridge between molecular nutrition and regenerative medicine - concise review. *Phytother Res.* 2017; 31: 947-958.
17. Babarikyn D, Krumina Z, Krasovska Ž, Krumina G, Aniščenko A, Babarikyna A, et al. Kompozīcija aknu taukainās steatozes noveršanai [in Latvian]. 2012 Patents LV 14588 B.
18. Close B, Banister K, Baumans V, Bernoth EM, Bromage N, Bunyan J, et al. Recommendation for euthanasia of experimental animals. Part 1. *DGXT European Commission Lab Anim.* 1996; 30(4): 293-316.
19. Yousef MH, Juboor AA, Albarrak AA, Ibdah JA, Tahan V. Fatty liver without a large “belly”: Magnified review of non-alcoholic fatty liver disease in non-obese patients. *World J Gastrointest Pathophysiol.* 2017; 8: 100.
20. Hashem AN, Soliman MS, Hamed MA, Swilam NF, Lindequist U, Nawwar MA. *Beta vulgaris* subspecies *ciela* var. *flavescens* (Swiss chard): flavonoids, hepatoprotective and hypolipidemic activities. *Pharmazie.* 2016; 71(4): 227-232.
21. Wu Y, Zhou F, Jiang H, Wang Z, Hua C, Zhang Y. Chicory (*Cichorium intybus* L.) polysaccharides attenuate high-fat diet induced non-alcoholic fatty liver disease via AMPK activation. *Int J Biol Macromol.* 2018; 118(PtA): 886-895.
22. Kathirvel E, Morgan K, Nandgiri G, Sandoval BC, Caudill MA, Bottiglieri T, et al. Betaine improves nonalcoholic fatty liver and associated hepatic insulin resistance: a potential mechanism for hepatoprotection by betaine. *Am J Physiol Liver Physiol.* 2010; 299: G1068-G1077.



23. Matthews JO, Southern LL, Highbie AD, Persica MA, Bidner TD. Effects of betaine on growth, carcass characteristics, pork quality, and plasma metabolites of finishing pigs. *J Anim Sci.* 2001; 79: 722-728.
24. Papadopoulos V, Kamtchouing P, Drosdowsky MA, Carreau S. Effects of the transmethylation inhibitor S-adenosyl-homocysteine and of the methyl donor S-adenosyl-methionine on rat leydig cell function in vitro. *J Steroid Biochem.* 1987; 26(1): 93-98.
25. Wang X, Magkos F, Mittendorfer B. Sex differences in lipid and lipoprotein metabolism: it's not just about sex hormones. *J Clin Endocrinol Metab.* 2011; 96(4): 885-893.
26. Denzer C, Thiere D, Muche R, Koenig W, Mayer H, Kratzer W, et al. Gender-specific prevalences of fatty liver in obese children and adolescents: roles of body fat distribution, sex steroids, and insulin resistance. *J Clin Endocrinol Metab.* 2009; 94(10): 3872-3881.
27. Cholewa JM, Wyszczelska-Rokiel M, Glowacki R, Jakubowski H, Matthews T, Wood R, et al. Effects of betaine on body composition, performance, and homocysteine thiolactone. *J Int Soc Sports Nutr.* 2013; 10(1): 39.
28. Ganji SH, Kukes GD, Lambrecht N, Kashyap ML, Kamanna VS. Therapeutic role of niacin in the prevention and regression of hepatic steatosis in rat model of nonalcoholic fatty liver disease. *Am J Physiol Liver Physiol.* 2014; 306(4): G320-G327.
29. Clifford T, Howatson G, West DJ, Stevenson EJ. The potential benefits of red beetroot supplementation in health and disease. *Nutrients.* 2015; 7(4): 2801-2822.
30. Gliszczynska-Świgło A, Szymusiak H, Malinowska P. Betanin, the main pigment of red beet: molecular origin of its exceptionally high free radical-scavenging activity. *Food Addit Contam.* 2006; 23(11): 1079-1087.
31. Georgiev VG, Weber J, Kneschke EM, Denev PN, Bley T, Pavlov AI. Antioxidant activity and phenolic content of betalain extracts from intact plants and hairy root cultures of the red beetroot *Beta vulgaris* cv. Detroit Dark Red. *Plant Foods Hum Nutr.* 2010; 65(2): 105-111.
32. Lee CH, Wettasinghe M, Bolling BW, Ji LL, Parkin KL. Betalains, phase II enzyme-inducing components from red beetroot (*Beta vulgaris* L.) extracts. *Nutr Cancer.* 2005; 53(1): 91-103.
33. Rahimi P, Abedimanesh S, Mesbah Namin SA, Ostadrahimi A. Betalains, the nature-inspired pigments, in health and diseases. *Crit Rev Food Sci Nutr.* 2018; 1-30: doi: 10.1080/10408398.2018.1479830
34. Wroblewska M, Juskiwicz J, Wiczkowski W. Physiological properties of beetroot crisps applied in standard and dyslipidaemic diets of rats. *Lipids Health Dis.* 2011; 10: 178.
35. Bashiardes S, Shapiro H, Rozin S, Shibolet O, Elinav E. Non-alcoholic fatty liver and the gut microbiota. *Mol Metab.* 2016; 5(9): 782-794.
36. Manco M, Putignani L, Bottazzo GF. Gut microbiota, lipopolysaccharides, and innate immunity in the pathogenesis of obesity and cardiovascular risk. *Endocr Rev.* 2010; 31(6): 817-844.