

Testis Structure and Function in a Nongenetic Hyperadipose Rat Model at Prepubertal and Adult Ages

L. R. França, M. O. Suescun, J. R. Miranda, A. Giovambattista, M. Perello, E. Spinedi, and R. S. Calandra

Department of Morphology (L.R.F., J.R.M.), Laboratory of Cellular Biology, Institute of Biological Sciences/Federal University of Minas Gerais, Belo Horizonte-MG 31270-901, Brazil; Laboratory of Reproductive Endocrinology (M.O.S.) and Neuroendocrine Unit (A.G., M.P., E.S.), Instituto Multidisciplinario de Biología Celular, and School of Exact Sciences (M.O.S., A.G., R.S.C.), Universidad Nacional de La Plata, La Plata 1900, Argentina; and Instituto de Biología y Medicina Experimental (R.S.C.), Buenos Aires 1428, Argentina

There are few data for hormonal levels and testis structure and function during postnatal development in rats neonatally treated with monosodium L-glutamate (MSG). In our study, newborn male pups were ip injected with MSG (4 mg/g body weight) every 2 d up to 10 d of age and investigated at prepubertal and adult ages. Plasma levels of leptin, LH, FSH, prolactin, testosterone (T), corticosterone, and free T₄ (FT₄) were measured. MSG rats displayed elevated circulating levels of corticosterone and hyperadiposity/hyperleptinemia, regardless of the age examined; conversely, circulating prolactin levels were not affected. Moreover, prepubertal MSG rats revealed a significant ($P < 0.05$) reduction in testis weight and the number of Sertoli (SC) and Leydig cells per testis. Leptin plasma levels were severalfold higher (2.41 vs. 8.07; $P < 0.05$) in prepubertal MSG rats, and these animals displayed plasma

LH, FSH, T, and FT₄ levels significantly decreased ($P < 0.05$). Taken together, these data indicate that testis development, as well as SC and Leydig cell proliferation, were disturbed in prepubertal MSG rats. Adult MSG rats also displayed significantly higher leptin plasma levels (7.26 vs. 27.04; $P < 0.05$) and lower ($P < 0.05$) LH and FSH plasma levels. However, T and FT₄ plasma levels were normal, and no apparent alterations were observed in testis structure of MSG rats. Only the number of SCs per testis was significantly ($P < 0.05$) reduced in the adult MSG rats. In conclusion, although early installed hyperadipose/hyperleptinemia phenotype was probably responsible for the reproductive axis damages in MSG animals, it remains to be investigated whether this condition is the main factor for hypothalamus-pituitary-gonadal axis dysfunction in MSG rats. (*Endocrinology* 147: 1556–1563, 2006)

THE ADIPOSE TISSUE-derived peptide, leptin, has been shown to be important for the regulation of food intake, energy metabolism, and reproductive function (1–4), regardless of the sex of individuals. This peptide is the *ob* gene product controlled by TNF α and is composed of 145 amino acid residues and molecular mass of approximately 16 kDa (5). Several reports described leptin as being involved in normal sexual maturation and reproductive process (1, 6). In addition, it has been shown that leptin is a metabolic key regulator of reproductive function and that this peptide is a signal between the nutritional status and reproduction (4).

The leptin receptor is expressed, at least, in six isoforms (a–f) arising from mRNA splice variants (7). The biologically active variant of the leptin receptor (Ob-Rb) is localized in the arcuate (ARC) and ventromedial nuclei of the hypothalamus. Also, the expression and localization of leptin receptor have been shown in gonadotrope (8), Leydig (9), and male germ (10) cells. In the testis, it was showed that leptin crosses the murine blood-testis barrier by a nonsaturable process (11). However, other authors found Ob-R in this organ and that the Ob-Rb isoform is the predominant variant expressed (12).

Also, it has been shown that Ob-Rf is a soluble isoform that serves as a circulating leptin-binding protein (13), and a saturable transport system for leptin was shown at the central nervous system level (14).

It has been proposed that a specific and narrow range of leptin concentration is necessary to maintain a normal reproductive function; and levels below or above these thresholds are critical for the influence of this peptide on the hypothalamus-pituitary-gonadal (HPG) axis function (3, 4). Also, although male mice deficient in leptin (*ob/ob*) are infertile, this condition could be reverted by leptin administration (15).

The neonatal administration of monosodium L-glutamate (MSG) in rodents damages the ARC, thus resulting in a syndrome characterized by stunted growth, hyperadiposity, and hypogonadism during adulthood (16, 17). However, to our knowledge there are only few data in the literature regarding the plasma levels of the several hormones secreted by gonadotropes in MSG-damaged prepubertal and adult rats (18). Also, no data related to changes in the structure and function of the male reproductive tract during postnatal development have been reported in MSG-lesioned rats. A recent study from our laboratories has shown that the endogenous hyperleptinemia, caused by MSG treatment, is able to modify testicular steroidogenic activity and the expression of Leydig cell leptin receptor in adult rats (19). Thus, although the neurotoxic effects of MSG are relatively well studied, to our knowledge, the present work is the first study perform-

First Published Online December 8, 2005

Abbreviations: ARC, Arcuate nucleus; FT₄, free T₄; HPG, hypothalamus-pituitary-gonadal; MSG, monosodium L-glutamate; Ob-Rb, biologically active variant of leptin receptor; T, testosterone.

Endocrinology is published monthly by The Endocrine Society (<http://www.endo-society.org>), the foremost professional society serving the endocrine community.

ing a more detailed investigation on the impact of neonatal MSG treatment on HPG axis development, namely when evaluation is performed from parameters related to testis structure and activity, in association with several markers of reproductive function.

Materials and Methods

Animals, treatment, and tissue preparation

Adult male (350–450 g) and female (240–280 g) Sprague Dawley rats were allowed to mate in colony cages in a light (12-h light cycle, lights on at 0700 h)- and temperature (20–22 C)-controlled room and were fed standard food pellets and water *ad libitum*. Pregnant female rats were placed in clear individual plastic cages.

Male pups, 2 d after birth, were injected ip with 4 mg/g body weight MSG (Merck, Darmstadt, Germany) dissolved in 0.9% NaCl or the same volume of 10% NaCl (control) every 2 d up to 10 d of age (19). These rats were weaned at 21 d of age, and male rats were then killed at the age of 1 or 4 months ($n = 9$ –10 rats/group per age). All procedures performed followed approved National Institutes of Health Guidelines for Care and Use of Experimental Animals.

Blood samples were collected by cardiac puncture before perfusion and plasma samples were kept frozen (–20 C) until measurement of different hormones [leptin, FSH, LH, prolactin, corticosterone, testosterone (T), and free T_4 (FT_4)]. Testis tissue processing was performed according to Russell *et al.* (20). In brief, 15 min before the initiation of perfusion for tissue fixation, rats were injected ip with heparin at a dose of 130 IU/kg body weight. Anesthetized (ketamine-xylazine) rats were perfused through the left ventricle with 0.9% NaCl (~5 min) to clear blood vessels. After clearance of vessels, a two-way valve apparatus was used to introduce 4% glutaraldehyde in phosphate buffer 0.05 M (pH 7.4) without removal of the needle. Animals were perfused for 25–30 min, whereupon testes, epididymides, seminal vesicle plus coagulating gland and adrenal glands were removed and weighed. To perform light microscopic investigations, testis fragments were routinely processed and embedded in plastic (glycol methacrylate). Subsequently sections of 4 μ m in thickness were obtained and stained with toluidine blue. Immediately after the animals were killed, total fat (the sum of omental, epididymal and retroperitoneal) pads, from rats of both groups/ages were dissected and weighed.

Hormonal measurements

Plasma leptin concentrations were determined by a specific RIA previously developed and validated for rat leptin in our laboratory (21). Briefly, synthetic murine leptin (PrePro Tech, Inc., Rocky Hill, NJ) was used for both labeled peptide and standards as well as for the development of antileptin serum. Leptin was labeled with 125 I-Na (specific activity 15 Ci/mmol; Amersham Pharmacia Biotech, Little Chalfont, UK) by the chloramine-T method and purified by elution after loading the radioiodination mixture from a Sephacryl S-300 (Sigma Chemical Co., St. Louis, MO) (1.5 \times 60 cm) column equilibrated with sodium phosphate (0.05 M)-BSA (2 g/liter)-sodium azide (10 mg/liter) solution (pH 7.4). The antileptin serum was developed by rabbit immunization with murine leptin (PrePro Tech) coupled to BSA. The detection range of the standard curve was 0.4–50 ng/ml. Unknowns or standards (200 μ l) were incubated overnight at room temperature in the presence of 50 μ l of antileptin rabbit serum (final dilution 1:15,000) and 50 μ l (~30,000 cpm) of tracer. Separation of bound and free fractions was achieved by addition, first, of 200 μ l normal saline solution containing antirabbit γ -globulin and then 500 μ l polyethylene glycol 6000 (10% wt/vol, in normal saline) solution and then incubated for 30 min at 4 C until centrifuged (40 min at 4 C, 4000 rpm). Supernatants were aspirated and bound radioactivity was counted. The assay displayed 2% and zero cross-reactivity with human leptin and mouse/rat anterior pituitary (LH, FSH, GH, prolactin) hormones, respectively. The within-assay and interassay coefficients of variation were 5–8 and 10–13%, respectively.

Serum levels of LH, FSH, and prolactin were determined by double-antibody RIAs, as previously described (22). Results are expressed in terms of the reference preparations (rat LH-RP3, FSH-RP-2, and PRL-RP-3), supplied by the National Institute of Diabetes and Digestive and

Kidney Diseases (Bethesda, MD). Sensitivity for the assays were: LH, 0.024 ng/tube; FSH, 0.10 ng/tube; and prolactin, 0.05 ng/tube. The within-assay and interassay coefficients of variation were less than 8 and 13%, respectively, regardless of the assay. T levels in plasma was measured by RIA using testosterone [$1,2$ - 3 H (N), 60 Ci/mmol] from NEN Life Science Products (Boston, MA) and a specific antibody from Immunotech Diagnostic (Montréal, Canada), as previously described and validated (23). The sensitivity of the testosterone assay was 12.5 pg/ml. The within-assay and interassay coefficients of variation were less than 12%. Plasma concentrations of corticosterone were evaluated by a specific RIA earlier reported (21); the standard curve ranged between 1 and 250 μ g/dl, and intra- and interassay coefficients of variation were 5 and 9%, respectively. FT_4 levels in serum were also assayed by RIA using a kit from Diagnostic Product Corp. (Los Angeles, CA) and validated in our laboratory for rat plasma samples. The within-assay and interassay coefficients of variation were 4.5 and 8%, respectively.

Testis histology and morphometry

Qualitative histological analysis of the testis was performed carefully to verify the most advanced germ cell type present in the seminiferous epithelium of each 30-d-old animal, according to the criteria described by Russell *et al.* (20) to characterize rat germ cell association through the acrosomic system method. Apoptotic germ cells were characterized as cells with dark nucleus and cytoplasm and shrunk plasma membrane; this germ cells apoptotic characteristics are easily recognizable in testis tissue fixed with glutaraldehyde and embedded in plastic resin, and this methodological approach is fully validated in the literature (20, 24).

The tubular diameter was measured at $\times 200$ magnification using an ocular micrometer calibrated with a stage micrometer. At least 30 tubular profiles that were round or nearly round were chosen randomly and measured for each animal. The volume densities of various testicular tissue components were determined by light microscopy using a 441-intersection grid placed in the ocular of the light microscope. Fifteen fields chosen randomly (6615 points) were scored for each animal at $\times 400$ magnification. Artifacts were rarely seen and were not considered in the total number of points used to obtain volume densities. Points were classified as one of the following: seminiferous tubule, comprising tunica propria, epithelium, and lumen; apoptotic germ cells; Leydig cell; blood and lymphatic vessels; and connective tissue. The volume of each component of the testis was determined as the product of the volume density and testis volume. Because the testis density is nearly 1.0 (~1.03–4), for subsequent morphometric calculations the testis weight was considered equal to testis volume (25). To obtain a more precise measure of testis volume the testis capsule (~3.4% at 30 d of age and ~6.5% at 120 d of age) was excluded from the testis weight. The total length of seminiferous tubule (meters) was obtained by dividing seminiferous tubule volume by the squared radius (R^2) of the tubule times the π value.

Cells count and number

Sertoli cell nucleoli were counted in 10 round or nearly round seminiferous tubule cross-sections, chosen at random, for each animal. These counts were corrected for section thickness and nucleoli diameter according to Abercrombie (26), as modified by Amann (27). For this purpose, 10 nucleoli diameters were measured for each animal. The total number of Sertoli cells was determined from the corrected counts of Sertoli cell nucleoli per seminiferous tubule cross-sections and the total length of seminiferous tubules according to Hochereau-de Reviers and Lincoln (28). The daily sperm production per testis and per gram of testis (spermatogenic efficiency) was obtained according to the formula developed by França (29) as follows: daily sperm production = total number of Sertoli cells per testis \times the ratio of round spermatids to Sertoli cells at stage VII \times stage VII relative frequency (percent)/stage VII duration (days).

Individual volume of the Leydig cell was obtained from nucleus volume and the proportion between nucleus and cytoplasm. The Leydig cell nucleus volume was obtained from the knowledge of the mean nuclear diameter. For this purpose, 30 nuclei showing evident nucleolus were measured at $\times 1000$ for each animal. Leydig cell nuclear volume was expressed in cubic micrometer and obtained by the formula, $4/3\pi R^3$, where R = nuclear diameter/2. To calculate the proportion between nucleus and cytoplasm, a 441-point square lattice was placed

TABLE 1. Biometric and morphometric data in 30-d-old control and MSG-treated rats (n = 9–10 rats per group; mean ± SEM)

Parameter	Control	MSG
Body weight (g)	114 ± 5	92 ± 3 ^a
Total fat mass (g/100 g body weight)	0.51 ± 0.06	1.41 ± 0.10 ^a
Testis weight (mg) ^b	400 ± 30	230 ± 20 ^a
Testis net weight (mg) ^c	386 ± 29	222 ± 29 ^a
Gonadosomatic index (%)	0.71 ± 0.03	0.50 ± 0.04 ^a
Epididymis weight (mg) ^b	46.8 ± 3.5	32.3 ± 1.9 ^a
Adrenal gland weight (mg) ^b	14.3 ± 0.7	11.2 ± 0.5 ^a
Total length of seminiferous tubule per testis (m)	11.0 ± 0.5	7.4 ± 0.5 ^a
Seminiferous tubules volume density (%)	90 ± 0.9	88.1 ± 0.6
Seminiferous tubules volume (μl)	352 ± 20	194 ± 16 ^a
Tubular lumen volume density (%)	3.4 ± 0.4	2.5 ± 0.2 ^a
Tubular lumen volume (μl)	14 ± 2	6 ± 1 ^a
Germ cell apoptosis volume density (%)	0.0	0.5 ± 0.1 ^a
Seminiferous tubule diameter (μm)	202 ± 3	182 ± 5 ^a
Leydig cell		
Volume density (%)	3.2 ± 0.3	3.3 ± 0.2
Volume in the testis parenchyma (μl)	13.0 ± 1.8	7.2 ± 0.6 ^a
Nuclear diameter (μm)	7.2 ± 0.1	6.8 ± 0.06 ^a
Individual volume (μm ³)	819 ± 34	761 ± 25
Cytoplasm volume (μm ³)	622 ± 25	599 ± 22
Nucleus volume (μm ³)	197 ± 10	163 ± 4 ^a

^a Statistically significant ($P < 0.05$ or less).

^b Right organ plus left organ weight divided by two.

^c Testis weight minus tunica albuginea weight.

over the sectioned material at ×400 magnification. One thousand points over Leydig cells were counted for each animal. The number of Leydig cell per testis was estimated from the Leydig cell individual volume and the volume occupied by Leydig cell in the testis parenchyma.

Statistical analysis

Data of plasma hormone levels (mean ± SEM) were analyzed by ANOVA (age × treatment), followed by Fisher's test for comparison of different mean values (30). Morphometric data are presented as the

mean ± SEM, and to analyze these data, Student's *t* test was performed using the program STATISTICA for windows (StatSoft, Inc., Tulsa, OK). Values for volume densities were subjected to arcsine transformation before analyses. Significant differences were considered when $P < 0.05$.

Results

Effects of neonatal MSG treatment on testis morphology and several endocrine activities in the 30-d-old male rat

The results of biometric and morphometric parameters found for control and MSG-treated rats are shown in Table 1 and Fig. 1 and those of circulating hormone levels in Table 2. As shown in Table 1, MSG animals showed a significant reduction ($P < 0.05$ or less) in body weight and gonadosomatic index (testis mass divided by body weight), and weights of testis, epididymis, and adrenal glands. Similarly, these animals showed reduced ($P < 0.05$ or less) seminiferous tubule diameter, seminiferous tubule volume, total length of seminiferous tubules, percentage of seminiferous tubule lumen and seminiferous tubule lumen volume, Leydig cell nuclear volume, and total number of Sertoli and Leydig cells per testis (Fig. 1).

Qualitative analysis of the seminiferous tubules showed that the pace of germ cells development was slightly delayed in treated rats. In this regard, as shown in Fig. 2, the most advanced germ cells in control rats was elongated sperma-

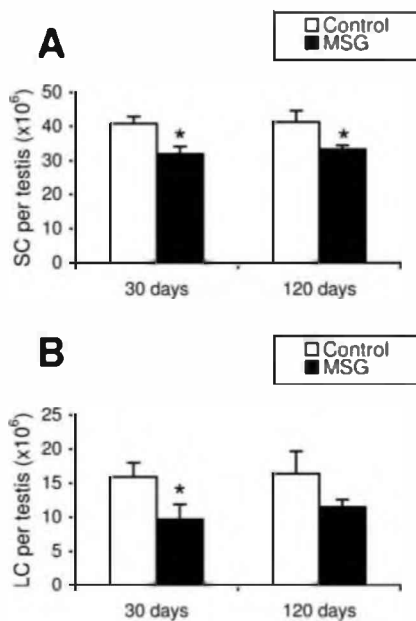


FIG. 1. Total number of Sertoli (SC) and Leydig cells (LC) per testis in 30-d-old and adult Sprague Dawley rats. Observe that at prepubertal age both Sertoli (A) and Leydig cells (B) number per testis are significantly lower ($P < 0.05$) in MSG-treated animals. The numbers found for SC and LC for control and MSG-treated rats did not change at both ages investigated; however, only the results observed for SC showed significant difference (*, $P < 0.05$) for adult rats.

TABLE 2. Hormone plasma levels in 30-d-old control and MSG-treated rats (n = 9–10 rats per group; mean ± SEM)

Parameter	Control	MSG
Leptin (ng/ml)	2.41 ± 0.34	8.07 ± 2.19 ^a
Prolactin (ng/ml)	6.79 ± 2.48	2.64 ± 0.58
FSH (ng/ml)	6.96 ± 0.19	3.10 ± 0.29 ^a
LH (ng/ml)	0.31 ± 0.07	0.15 ± 0.02 ^a
FT ₄ (ng/dl)	1.16 ± 0.05	0.76 ± 0.006 ^a
Testosterone (ng/ml)	3.32 ± 0.47	2.63 ± 0.16 ^a
Corticosterone (μg/dl)	1.84 ± 0.51	4.54 ± 0.97 ^a

^a Statistically significant ($P < 0.05$ or less).

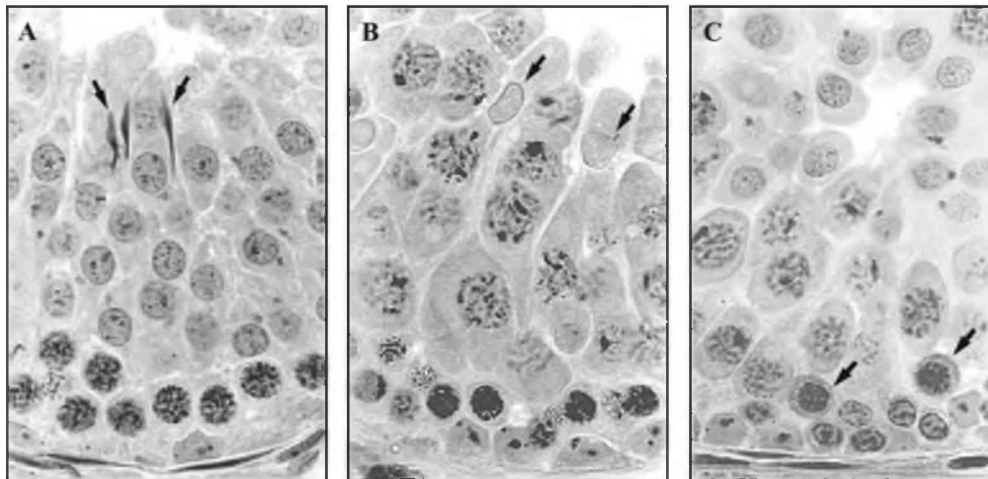


FIG. 2. Seminiferous tubules cross-section in 30-d-old Sprague Dawley rats. Observe that in control rats (A), the most advanced germ cells are elongated spermatids at step 16 (arrows) present in stages II–III. In hyperleptinemic rats (B), the most advanced germ cells are elongating spermatids at step 9 (arrows) present in stages IX–X. Apoptotic pachytene primary spermatocytes (arrows) were frequently observed in hyperleptinemic animals (C). Toluidine blue staining, $\times 800$.

tidal at step 16, whereas in hyperleptinemic rats these cells were at step 9. In contrast with the control group, in which apoptotic germ cells were rarely seen, the percentage of the seminiferous epithelium occupied by these cells was 0.5% in treated rats (Fig. 2). However, Leydig cell morphology investigated by light microscopy was apparently normal in both groups analyzed (Fig. 3). Sertoli cells looked slightly less mature and had significantly reduced nucleoli diameter (1.95 *vs.* 1.86; $P < 0.04$) in MSG-treated rats.

Total fat mass was significantly higher ($P < 0.05$) in MSG than control rats (Table 1). Although the values found for prolactin circulating levels in MSG rats represented only approximately 40% of the levels observed in controls, this difference was, however, not significant ($P = 0.09$). Regarding several circulating hormones investigated (Table 2), whereas leptin and corticosterone levels were 3.5- and 2.5-

fold higher, respectively ($P < 0.05$), in MSG than control rats; conversely, LH, FSH, T, and FT_1 levels were significantly lower ($P < 0.05$) in MSG than control animals.

Testis structure and function and other phenotypic characteristics of the adult MSG rat

Several phenotypic characteristics of adult, MSG, and control, rats are shown in Table 3 and Fig. 1. As described in general for young animals, hyperleptinemic ($P < 0.05$ *vs.* control values) rats presented a significant reduction ($P < 0.05$) in body weight and the weights of the epididymis, seminal vesicle plus coagulating gland, and adrenal glands. Careful histological analyses showed that apparently no alteration was observed in seminiferous tubules and intertubular compartments of the testis (Fig. 4). However, similar to 1-month-old rats, detailed stereological investigation demonstrated that the number of Sertoli cells per testis was approximately 20% lower ($P < 0.05$) in hyperleptinemic animals (Fig. 1). Although not significant, a clear trend toward diminution was observed for testis weight, Leydig cell individual volume, Leydig cells per testis (Fig. 1), and daily sperm production per testis in MSG rats. However, very similar results were found for most testis parameters evaluated in MSG and control rats, such as seminiferous epithelium height, lumen volume, germ cells number per tubular cross-section, and Sertoli cell efficiency measured as the number of round spermatids per Sertoli cell.

Similar to what was found in young rats, values for total fat mass and leptin and corticosterone plasma levels were significantly ($P < 0.05$) higher in MSG than control animals. Conversely, circulating LH and FSH levels were significantly ($P < 0.05$) reduced by MSG treatment when compared with, day-matched, control values. On the other hand, rats exposed to MSG displayed plasma prolactin, T, and FT_4 levels within the control range (Table 4).

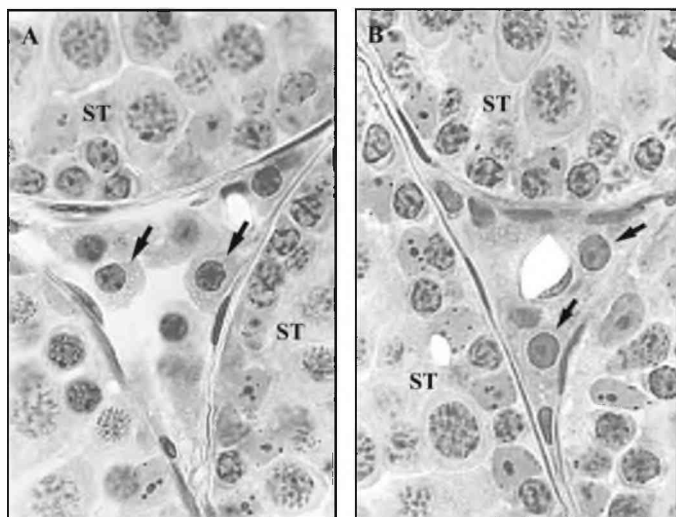


FIG. 3. Seminiferous tubule (ST) cross-sections and intertubular compartment in control (A) and 30-d-old hyperleptinemic rats (B). The morphology of Leydig cells (arrows) in both groups is, apparently, similar. Toluidine blue staining, $\times 800$.

TABLE 3. Biometric morphometric data in 120-d-old control and MSG-treated rats (n = 9 rats per group; mean ± SEM)

Parameter	Control	MSG
Body weight (g)	298 ± 12	267 ± 7 ^a
Total fat mass (g/100 g body weight)	2.62 ± 0.24	5.88 ± 0.41 ^a
Testis weight (mg) ^b	1307 ± 59	1209 ± 61
Testis net weight (mg) ^c	1222 ± 55	1130 ± 57
Gonadosomatic index (%)	0.87 ± 0.02	0.90 ± 0.05
Adrenal gland weight (mg) ^b	29.3 ± 1.8	23.9 ± 0.8 ^a
Epididymis weight (mg) ^b	443 ± 32	361 ± 25 ^a
Seminal vesicle + coagulating gland weight (mg) ^b	331 ± 29	205 ± 37 ^a
Total length of seminiferous tubule per testis (m)	15.5 ± 0.8	14.3 ± 0.8
Seminiferous tubule volume density (%)	90.0 ± 1.2	92.4 ± 0.5
Seminiferous tubule volume (ml)	1.09 ± 0.04	1.03 ± 0.05
Tubular lumen volume density (%)	8.0 ± 1.0	8.0 ± 1.1
Tubular lumen volume (ml)	0.10 ± 0.02	0.09 ± 0.01
Seminiferous tubule diameter (μm)	299 ± 4	310 ± 7
Sertoli cell efficiency	11.1 ± 0.8	12.0 ± 0.5
Leydig cell		
Volume density (%)	1.4 ± 0.2	1.0 ± 0.2
Volume in the testis parenchyma (μl)	17.0 ± 3	11 ± 2
Nuclear diameter (μm)	8.2 ± 0.3	7.7 ± 0.2
Individual volume (μm ³)	1207 ± 107	966 ± 66
Cytoplasm volume (μm ³)	914 ± 84	724 ± 53
Nucleus volume (μm ³)	293 ± 24	242 ± 13
Daily sperm production per testis (×10 ⁶)	34.2 ± 1.8	30.0 ± 2.1

^a Statistically significant ($P < 0.05$ or less).

^b Right organ plus left organ weight divided by two.

^c Testis weight minus tunica albuginea weight.

Discussion

To our knowledge, the present work is the first study investigating the male reproductive tract structure and function over development in hypothalamo-damaged rats due to neonatal MSG treatment. The increased circulating levels of leptin and corticosterone and the hyperadiposity developed by MSG-treated rats confirm the effectiveness of the treatment with this neurotoxin (31). Also, other hormonal alterations characterized the prepubertal MSG male rat, such as decreased gonadotropins, androgen, and thyroid hormone levels (16, 17). Although still controversial (32, 33), we found no significant changes in circulating prolactin levels, a hormone directly implicated in testis development (34). Moreover, in MSG rats, a clear hyperprolactinemia has been found in female but not male rats, thus suggesting a clear sexual dimorphism of the neurotoxic effect on dopaminergic-lactotrope function (35). Our results clearly indicate that neonatal MSG treatment-induced alteration in several HPG axis parameters examined at age 30 d; however, at adulthood, some of them resulted normalized.

As in most mammalian species, the normal rat postnatal testis development can be divided in two, distinct and inversely correlated, phases (36, 37). In the first, which lasts up to approximately 2 wk after birth, extensive spermatogonial and Sertoli cell proliferation can be observed, in turn promoting the growth in length of seminiferous cords, whereas during the second phase, that takes place from approximately 2 to 7–8 wk after birth, a noticeable increase in the numbers of germ cells and adult-type Leydig cells take place (36–38), and a dramatic growth in testis size, Sertoli cell fluid secretion, and tubular diameter can also be observed. These two phases are regulated by specific and different hormones and growth factors (36, 38). For instance, FSH and thyroid hormones are considered the main regulators of Sertoli cell

proliferation and differentiation (36, 39, 40), respectively. On the other hand, several hormones and growth factors, such as thyroid hormones, LH, steroids, anti-Mullerian hormone, platelet-derived growth factor-A, TGF α/β , IGF-I, and cytokines secreted by macrophages, are responsible for the regulation of Leydig cell proliferation and differentiation (38). In general, the factors related to proliferation and differentiation of germ cells are secreted by Sertoli cells, mainly under the influence of androgens and FSH (41, 42). Also, complex interaction between the seminiferous and interstitial compartments of the testis takes place during testis development, allowing the testis to fulfill both its endocrine and exocrine functions (36, 37, 43, 44).

Several of the above-mentioned factors were significantly reduced in MSG-treated rats investigated at 30 d of age, and, at least in part, these alterations might explain the results found in the present work, mainly for testis structure and function. Unpublished data, from ongoing experiments being developed in our laboratories, indicate that at 2 wk after birth, MSG-treated rats are already hyperleptinemic. At this stage of development, the levels of FSH, LH, and thyroid hormones, but not prolactin, are already decreased in these rats; thus, we could expect lower proliferation rate of Sertoli and Leydig cells as well as reduced functional activity of these cell populations. It should be mentioned that although not measured by us, it is possible that the conversion of T into estradiol (adipose aromatase activity) could be playing a role on delayed Leydig cell development and function in MSG rats (45). In this regard, the results found for the more immature status of Sertoli cells and significantly reduced Leydig cell nuclear volume and testosterone secretion, observed in 30-d-old MSG rats, would confirm this assumption. These results probably reflect the significantly lower seminiferous tubule volume and tubular lumen volume observed in pre-

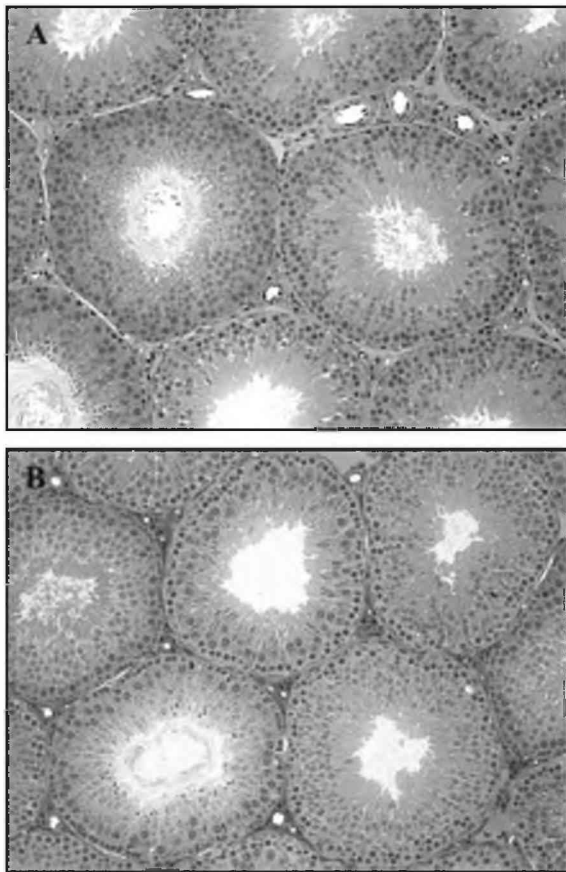


FIG. 4. Panoramic view of the testis structure in control (A) and hyperleptinemic adult rats (B). Observe that the testis structure is apparently normal in treated animals. Toluidine blue staining, $\times 100$.

pubertal MSG-treated rats. Also, because thyroid hormone receptors are present in Sertoli and germ cells (46, 47), particularly from intermediate spermatogonia to midcycle pachytene, being responsible for their differentiation, the findings related to increased apoptotic germ cells and the less mature Sertoli cells status in prepubertal treated rats might be correlated with lower free thyroxin levels. Combined to lower FT₄ levels, the results found for the more immature status of Sertoli cells suggest that the proliferative activity of this cell was slightly extended (40). In this regard, we could expect a much lower testis size and number of Sertoli cells per testis due to MSG treatment and the associated diminished FSH plasma levels. Corroborating this hypothesis, ongoing studies in our laboratory (48) show that in postnatal hypothyroidic condition (due to postnatal propylthiouracil

TABLE 4. Hormone plasma levels in 120-d-old control and MSG-treated rats (n = 9 rats per group; mean \pm SEM)

Parameter	Control	MSG
Leptin (ng/ml)	7.26 \pm 1.61	27.04 \pm 5.9 ^a
Prolactin (ng/ml)	7.16 \pm 2.77	5.28 \pm 2.81
FSH (ng/ml)	4.92 \pm 0.40	3.13 \pm 0.28 ^a
LH (ng/ml)	0.38 \pm 0.07	0.19 \pm 0.02 ^a
FT ₄ (ng/dl)	1.20 \pm 0.09	1.11 \pm 0.01
Testosterone (ng/ml)	4.58 \pm 0.58	4.77 \pm 0.78
Corticosterone (μ g/dl)	4.67 \pm 0.95	8.81 \pm 1.24 ^a

^a Statistically significant ($P < 0.05$ or less).

treatment that also decreases FSH plasma levels) daily FSH injections, during 3 wk after birth, has an additive effect on Sertoli cells number per testis.

Because leptin receptors are found in both tubular and intertubular compartments of the testis (10, 49), we cannot exclude a direct effect of hyperleptinemia on Sertoli, Leydig, and germ cell functions and development. Dihydrotestosterone, originated by 5 α -reductase-mediated T metabolism, is important for epididymal function (50, 51). In this regard, the significantly reduced epididymis weight observed in MSG-treated rats might be correlated with lower T levels found in these animals. The diminution observed in the weight of the adrenal glands tallies with previous published data (52), suggesting that changes in adrenal cortex size/morphology are symptomatic of trophic stimulation. As expected, FSH and LH plasma levels were altered in adult MSG rats, indicating a permanent ARC lesion in these animals (53). Our data, in agreement with previous observations, indicate that thyroid hormone (54) and testosterone (19) plasma levels were similar in 120-d-old control and MSG male rats.

It is worth mentioning that data obtained in the present investigation for structural and functional parameters in control adult rats, including data for Leydig cells, are in the range of data presented for rats in the literature [see review in Russell and França (55) and Refs. 56 and 57]. Except for the number of Sertoli cells per testis, the values obtained for the parameters related to seminiferous tubules were similar in control and MSG-treated adult rats. These findings indicate that alterations due to MSG treatment and hyperleptinemia, related to Sertoli cell function and the spermatogenic process, can be reversed at the adult age. Nevertheless, because usually the Sertoli cell proliferative activity does not extend beyond 2–3 wk after birth (36, 39), the final number of these cells per testis remained low after 30 d of age in MSG rats.

Because the Sertoli cell can support a limited and species-specific number of germ cells, it is already well known in the literature that the number of Sertoli cells, established during the prepubertal period, determines the final testis size and the magnitude of sperm production in sexually mature animals (58–61). In this regard, based on the number of Sertoli cells per testis, one could expect a low daily sperm production per testis (spermatogenic efficiency) in adult MSG rats. However, usually experimental conditions in which the number of Sertoli cells per testis is decreased or increased would lead, respectively, to high (França, L. R., and J. R. Miranda, unpublished data) or low (45, 62) number of germ cells per each Sertoli cell (named Sertoli cell efficiency). In fact, although not significantly different, compared with controls, Sertoli efficiency in MSG rats is almost 10% higher, and this result probably explains why the values found for spermatogenic efficiency are similar in both groups. Paradoxically, different from data found in the present study, in the condition of reduced Sertoli cells number per testis, one should expect higher FSH levels (59). Although not fully understood, the disturbed HPG axis due to MSG treatment would probably shadows the scenario and the real significance of reduced FSH plasma levels observed in the present model, we also cannot exclude that the evaluation of inhibin B levels in MSG rats could provide additional information regarding Sertoli cell function.

Although several parameters related to Leydig cell function, such as Leydig cell individual volume and the volume occupied by this cell in the intertubular compartment, showed a clear trend toward diminution in hyperleptinemic adult rats, T plasma levels remained normal. The decreased weights of sexual accessory organs observed in hyperleptinemic adult rats, even in the presence of normal T levels, probably resulted from decreased Leydig cell steroidogenic activity during the critical period of organ development. Also, because these organs are androgen dependent (50, 51, 63), disturbance in the conversion of T in dihydrotestosterone, as well as a direct effect of leptin on the testis of the MSG rat, cannot be excluded.

Recent studies developed by our research group showed that MSG-treated rats displayed an *in vitro* Leydig cell dysfunction when exposed to graded concentrations of human chorionic gonadotropin (19). It was also suggested in this study that, in normal rat testes, leptin may represent an additional inhibitory factor of rat testicular steroidogenesis (P450 side-chain cleavage enzyme, steroidogenic acute regulatory protein, and 17 β -hydroxysteroid dehydrogenase). Besides that, neurotoxin-elicited chronic hyperleptinemia could be responsible for down-regulation of testicular mRNA Ob-Rb expression at adult age (19). However, because MSG animals early develop hyperadiposity/hyperleptinemia, probably as a consequence of enhanced corticoadrenal activity (64), a clearly recognized adipocytostimulating signal, it remains to be determined whether the hypothalamic lesion itself or in association with changes in adrenal-adipocyte cross-talk is a determinant factor for impaired fertility of the MSG male rat (65). In fact, it should be considered that corticoadrenal hyperactivity could be directly involved in reducing hypothalamic (LHRH)-gonadotropin (LH) (66) axis activity, thus resulting in an inappropriate sexual maturation (67) of the MSG male rat. It remains to be determined whether the correction of hypercorticotestosterone, in MSG rats and, because it occurred for the hyperadipose phenotype (64), could avoid impaired male reproductive function. Recent unpublished data from our laboratory indicate that the reduction of circulating glucocorticoid and leptin levels, due to bilateral adrenal enucleation for 21 d in adult MSG rats, restored the inhibitory effect of exogenous leptin on human chorionic gonadotropin-stimulated T production by isolated Leydig cells. Moreover, to better understand the fine mechanisms related to our findings on impaired reproductivity characterizing MSG rats, studies in chronic hyperleptinemic rats, due to daily exogenous leptin administration over development, are currently running.

In conclusion, our results indicate that MSG animals display the following HPG axis-altered characteristics: 1) disturbed Sertoli and Leydig cell proliferation over testis development; 2) diminished Sertoli cell number, the only tubular element already compromised before puberty; and 3) decreased weights of sexual accessory organs, at both ages investigated, which probably resulted from lower Leydig cell steroidogenic activity during the critical period of organ development. It remains to be determined whether long-term hyperleptinemia is a main factor for disrupted HPG axis development in the MSG male rat.

Acknowledgments

The authors thank Dr. V. Lux (Instituto de Biologia y Medicina Experimental) for the measurement of circulating prolactin levels. Technical help from Rubens Miranda and Adriano Moreira is highly appreciated.

Received May 31, 2005. Accepted November 30, 2005.

Address all correspondence and requests for reprints to: Dr. Luiz Renato de França, Laboratory of Cellular Biology, Department of Morphology, Institute of Biological Sciences/Federal University of Minas Gerais, Belo Horizonte-MG, Brazil. E-mail: lrfraça@icb.ufmg.br.

This work was supported by grants from Conselho Nacional de Desenvolvimento Científico e Tecnológico (CNPq), Brazil; CNPq/Programa Sul-Americano de Apoio às Atividades de Cooperação em Ciência e Tecnologia-Consejo Nacional de Investigaciones Científicas y Técnicas; Fondo Nacional de Ciencia y Tecnología; and Beca Carrillo-Oñativia-MS, Argentina.

The authors have no conflict of interest.

References

- Barash IA, Cheung CC, Weigle DS, Ren H, Kabigting EB, Kuijper JL, Clifton DK, Steiner RA 1996 Leptin is a metabolic signal to the reproductive system. *Endocrinology* 137:3144–3147
- Magni P, Motta M, Martini L 2000 Leptin: a possible link between food intake, energy expenditure, and reproductive function. *Regul Pept* 92:51–56
- Caprio M, Fabbri E, Isidori AM, Aversa A, Fabbri A 2001 Leptin in reproduction. *Trends Endocrinol Metab* 12:65–72
- Smith GD, Jackson LM, Foster DL 2002 Leptin regulation of reproductive function and fertility. *Theriogenology* 57:73–86
- McGregor GP, Desaga JF, Ehlenz K, Fischer A, Heese F, Hegele A, Lammer C, Peiser C, Lang RE 1996 Radioimmunochemical measurement of leptin in plasma of obese and diabetic human subjects. *Endocrinology* 137:1501–1504
- García-Mayor RV, Andrade MA, Rios M, Lage M, Dieguez C, Casanueva FF 1997 Serum leptin levels in normal children: relationship to age, gender, body mass index, pituitary-gonadal hormones, and pubertal stage. *J Clin Endocrinol Metab* 82:2849–2855
- Tartaglia LA, Dembski M, Weng X, Deng N, Culpepper J, Devos R, Richards GJ, Campfield LA, Clark FT, Deeds J 1995 Identification and expression cloning of a leptin receptor, OB-R. *Cell* 83:1263–1271
- Sone M, Nagata H, Takekoshi S, Osamura RY 2001 Expression and localization of leptin receptor in the normal rat pituitary gland. *Cell Tissue Res* 305:351–356
- Caprio M, Isidori AM, Carta AR, Moretti C, Dufau ML, Fabbri A 1999 Expression of functional leptin receptors in rodent Leydig cells. *Endocrinology* 140:4939–4947
- El-Hefnawy T, Ioffe S, Dym M 2000 Expression of the leptin receptor during germ cell development in the mouse testis. *Endocrinology* 141:2624–2630
- Banks WA, McLay RN, Kastin AJ, Sarmiento U, Scully S 1999 Passage of leptin across the blood-testis barrier. *Am J Physiol* 276:E1099–1104
- Tena-Sempere M, Pinilla L, Zhang FP, Gonzalez LC, Huhtaniemi I, Casanueva FF, Dieguez C, Aguilar E 2001 Developmental and hormonal regulation of leptin receptor (Ob-R) messenger ribonucleic acid expression in rat testis. *Biol Reprod* 64:634–643
- Lahlou N, Clement K, Carel JC, Vaisse C, Lotton C, Le Bihan Y, Basdevant A, Lebouc Y, Froguel P, Roger M, Guy-Grand B 2000 Soluble leptin receptor in serum of subjects with complete resistance to leptin: relation to fat mass. *Diabetes* 49:1347–1352
- Bjorbaek C, Kahn BB 2004 Leptin signaling in the central nervous system and the periphery. *Recent Prog Horm Res* 59:305–331
- Mounzih K, Lu R, Chehab FF 1997 Leptin treatment rescues the sterility of genetically obese ob/ob males. *Endocrinology* 138:1190–1193
- Redding TW, Schally AV, Arimura A, Wakabayashi I 1971 Effect of monosodium glutamate on some endocrine functions. *Neuroendocrinology* 8:245–255
- Spinedi E, Johnston C, Negro-Vilar A 1984 Increased responsiveness of the hypothalamic-pituitary axis after neurotoxin-induced hypothalamic denervation. *Endocrinology* 115:267–272
- Rush ME 1986 Follicle-stimulating hormone secretion in monosodium glutamate-lesioned rats: response to unilateral gonadectomy or porcine follicular fluid (inhibin). *Life Sci* 38:1941–1949
- Giovambattista A, Suescun MO, Nessler CC, Franca LR, Spinedi E, Calandra RS 2003 Modulatory effects of leptin on Leydig cell function of normal and hyperleptinemic rats. *Neuroendocrinology* 78:270–279
- Russell LD, Ettlin RA, Sinha Hikim AP, Clegg ED 1990 *Histological and histopathological evaluation of the testis*. 1st ed. Clearwater, FL: Cache River Press
- Giovambattista A, Chisari AN, Gaillard RC, Spinedi E 2000 Food intake-induced leptin secretion modulates hypothalamo-pituitary-adrenal axis re-

- sponse and hypothalamic Ob-Rb expression to insulin administration. *Neuroendocrinology* 72:341–349
22. **Suescun MO, Calandra RS, Lustig L** 1994 Alterations of testicular function after induced autoimmune orchitis in rats. *J Androl* 15:442–448
 23. **Suescun MO, Gonzalez SI, Chiauzzi VA, Calandra RS** 1985 Effects of induced hypoprolactinemia on testicular function during gonadal maturation in the rat. *J Androl* 6:77–82
 24. **Russell LD, Corbin TJ, Borg KE, França LR, Grasso P, Bartke A** 1993 Recombinant human follicle-stimulating hormone is capable of exerting a biological effect in the adult hypophysectomized rat by reducing the numbers of degenerating germ cells. *Endocrinology* 133:2062–2070
 25. **França LR, Godinho CL** 2003 Testis morphometry, seminiferous epithelium cycle length, and daily sperm production in domestic cats (*Felis catus*). *Biol Reprod* 68:1554–1561
 26. **Abercrombie M** 1946 Estimation of nuclear populations from microtome sections. *Anat Rec* 94:238–248
 27. **Amann RP** 1962 Reproductive capacity of dairy bulls: III. The effect of ejaculation frequency, unilateral vasectomy, and age on spermatogenesis. *Am J Anat* 110:49–67
 28. **Hochereau-de Reviers MT, Lincoln GA** 1978 Seasonal variation in the histology of the testis of the red deer, *Cervus elaphus*. *J Reprod Fertil* 54:209–213
 29. **França LR**, Daily sperm production in Piau boars estimated from Sertoli cell population and Sertoli cell index. Proc 12th International Congress on Animal Reproduction (ICAR), The Hague, The Netherlands, 1992, pp 1716–1718
 30. **Zar J** 1974 Biostatistical analysis. Englewood Cliffs, NJ: Prentice-Hall
 31. **Perello M, Gaillard RC, Chisari A, Spinedi E** 2003 Adrenal enucleation in MSG-damaged hyperleptinemic male rats transiently restores adrenal sensitivity to leptin. *Neuroendocrinology* 78:176–184
 32. **Heiman ML, Ben-Jonathan N** 1983 Increase in pituitary dopaminergic receptors after monosodium glutamate treatment. *Am J Physiol* 245:E261–E265
 33. **Bodnar I, Gooz P, Okamura H, Toth BE, Vecsernye M, Halasz B, Nagy GM** 2001 Effect of neonatal treatment with monosodium glutamate on dopaminergic and L-DOPA-ergic neurons of the medial basal hypothalamus and on prolactin and MSH secretion of rats. *Brain Res Bull* 55:767–774
 34. **Perez-Villamil B, Bordiu E, Puente-Cueva M** 1992 Involvement of physiological prolactin levels in growth and prolactin receptor content of prostate glands and testes in developing male rats. *J Endocrinol* 132:449–459
 35. **Bakke JL, Lawrence N, Bennett J, Robinson S, Bowers CY** 1978 Late endocrine effects of administering monosodium glutamate to neonatal rats. *Neuroendocrinology* 26:220–228
 36. **Orth JM** 1993 Cell biology of testicular development in fetus and neonate. In: Desjardins C, Ewing LL, eds. Cell and molecular biology of the testis. New York: Oxford University Press; 3–42
 37. **França LR, Silva Jr VA, Chiarini-Garcia H, Garcia SK, Debeljuk L** 2000 Cell proliferation and hormonal changes during postnatal development of the testis in the pig. *Biol Reprod* 63:1629–1636
 38. **Mendis-Handagama SM, Ariyaratne HB** 2001 Differentiation of the adult Leydig cell population in the postnatal testis. *Biol Reprod* 65:660–671
 39. **Sharpe RM, McKinnell C, Kivlin C, Fisher JS** 2003 Proliferation and functional maturation of Sertoli cells, and their relevance to disorders of testis function in adulthood. *Reproduction* 125:769–784
 40. **Cooke P, Holsberger DR, França LR** 2005 Thyroid hormone regulation of Sertoli cell development. In: Skinner MK, Griswold MD, eds. The Sertoli cell biology. San Diego: Elsevier Science; 217–226
 41. **Sharpe RM** 1994 Regulation of spermatogenesis. In: Knobil E, Neill JD, eds. The physiology of reproduction. 2nd ed. New York: Raven Press; 1363–1434
 42. **Griswold MD** 1998 The central role of Sertoli cells in spermatogenesis. *Semin Cell Dev Biol* 9:411–416
 43. **Benahmed M, Tabone E, Grenot C, Sanchez P, Chauvin MA, Morera AM** 1986 Paracrine control of Leydig cell activity by FSH dependent proteins from Sertoli cells: an *in vitro* study. *J Steroid Biochem* 24:311–315
 44. **Schlatt S, Meinhardt A, Nieschlag E** 1997 Paracrine regulation of cellular interactions in the testis: factors in search of a function. *Eur J Endocrinol* 137:107–117
 45. **Vermeulen A, Kaufman JM, Goemaere S, van Pottelberg I** 2002 Estradiol in elderly men. *Aging Male* 5:98–102
 46. **Jannini EA, Ulisse S, D'Armiento M** 1995 Thyroid hormone and male gonadal function. *Endocr Rev* 16:443–459
 47. **Buzzard JJ, Morrison JR, O'Bryan MK, Song Q, Wreford NG** 2000 Developmental expression of thyroid hormone receptors in the rat testis. *Biol Reprod* 62:664–669
 48. **Miranda JR** 2002 Effects of neonatal treatment with 6-*n*-propyl-2-thiouracil (PTU) and FSH on Sertoli cell proliferation and testis function in Wistar rats [in Portuguese]. Belo Horizonte, Brazil: Federal University of Minas Gerais; 47
 49. **Caprio M, Fabbrini E, Ricci G, Basciani S, Gnessi L, Arizzi M, Carta AR, De Martino MU, Isidori AM, Fradjese GV, Fabbri A** 2003 Ontogenesis of leptin receptor in rat Leydig cells. *Biol Reprod* 68:1199–1207
 50. **Robaire B, Viger RS** 1995 Regulation of epididymal epithelial cell functions. *Biol Reprod* 52:226–236
 51. **Ezer N, Robaire B** 2002 Androgenic regulation of the structure and functions of the epididymis. In: Robaire B, Hinton BT, eds. The epididymis: from molecules to clinical practice. New York: Kluwer Academic/Plenum; 297–316
 52. **Dolnikoff MS, Kater CE, Egami M, de Andrade IS, Marmo MR** 1988 Neonatal treatment with monosodium glutamate increases plasma corticosterone in the rat. *Neuroendocrinology* 48:645–649
 53. **Clemens JA, Roush ME, Fuller RW, Shaar CJ** 1978 Changes in luteinizing hormone and prolactin control mechanisms produced by glutamate lesions of the arcuate nucleus. *Endocrinology* 103:1304–1312
 54. **Miskowiak B, Partyka M** 1993 Effects of neonatal treatment with MSG (monosodium glutamate) on hypothalamo-pituitary-thyroid axis in adult male rats. *Histol Histopathol* 8:731–734
 55. **Russell LD, França LR** 1995 Building a testis. *Tissue Cell* 27:129–147
 56. **Mori H, Christensen, AK** 1980 Morphometric analysis of Leydig cells in the rat testis. *J Cell Biol* 84:340–354
 57. **Zirkin BR, Ewing LL** 1987 Leydig cell differentiation during maturation of the rat testis: a stereological study of cell number and ultrastructure. *Anat Rec* 219:157–163
 58. **Berndtson WE, Igboeli G, Pickett BW** 1987 Relationship of absolute numbers of Sertoli cells to testicular size and spermatogenesis in young beef bulls. *J Anim Sci* 64:241–246
 59. **Orth JM, Gonsalvus GL, Lamperti AA** 1988 Evidence from Sertoli cell-depleted rats indicates that spermatid number in adults depends on numbers of Sertoli cells produced during perinatal development. *Endocrinology* 122:787–794
 60. **Johnson L, Carter GK, Varner DD, Taylor TS, Blanchard TL, Rembert MS** 1994 The relationship of daily sperm production with number of Sertoli cells and testicular size in adult horses: role of primitive spermatogonia. *J Reprod Fertil* 100:315–321
 61. **França LR, Russell LD** 1998 The testis of domestic animals. In: Martínez-García E, Regadera J, eds. Male reproduction: a multidisciplinary overview. Madrid: Churchill Communications Europe España; 197–219
 62. **Hess RA, Cooke PS, Bunick D, Kirby JD** 1993 Adult testicular enlargement induced by neonatal hypothyroidism is accompanied by increased Sertoli and germ cell numbers. *Endocrinology* 132:2607–2613
 63. **Dohle GR, Smit M, Weber RF** 2003 Androgens and male fertility. *World J Urol* 21:341–345
 64. **Perello M, Moreno G, Gaillard RC, Spinedi E** 2004 Glucocorticoid-dependency of increased adiposity in a model of hypothalamic obesity. *Neuro Endocrinol Lett* 25:119–126
 65. **Pizzi WJ, Barnhart JE, Fanslow DJ** 1977 Monosodium glutamate administration to the newborn reduces reproductive ability in female and male mice. *Science* 196:452–454
 66. **Lalau JD, Aubert ML, Carmignac DF, Gregoire I, Dupouy JP** 1990 Reduction in testicular function in rats. II. Reduction by dexamethasone in fetal and neonatal rats. *Neuroendocrinology* 51:289–293
 67. **Biagini G, Pich EM** 2002 Corticosterone administration to rat pups, but not maternal separation, affects sexual maturation and glucocorticoid receptor immunoreactivity in the testis. *Pharmacol Biochem Behav* 73:95–103