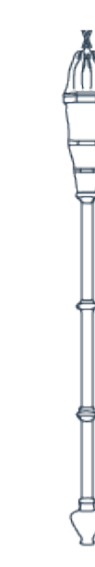

Developing a Methodology Protocol for Identifying the Superficial Peroneal Nerve in Living Models Sonographically and Formalin-Fixed Cadavers Morphologically: A Proof of Concept Study



University of
St Andrews



School of
Medicine

Katie Turnbull*[§] (1), James Bowness[§] (1,2), Fraser Chisholm (1), Alasdair Taylor (2), Jayne Halcrow (2), Calum Grant[§] (2), Ourania Varsou[§] (1)

[§]Equal Primary Authorship

[§]Equal Senior Authorship

(1) School of Medicine, University of St Andrews, Scotland UK
(2) Ninewells Hospital and Medical School, Dundee, Scotland UK

Correspondence to Katie Turnbull: kst2@st-andrews.ac.uk

Introduction

The superficial peroneal nerve (SPN) provides cutaneous innervation to the distal anterolateral leg and dorsum of foot.¹ The position of this nerve is important to know in clinical settings, such as when performing an ankle block in anaesthesia, but published literature provides varying and imprecise accounts. Descriptions suggest that it pierces the deep fascia 'in the distal third of the leg'¹ or 'between the middle and lower third of the leg'². The lack of formal guidelines on methodology used to identify the SPN could be a major factor resulting in such discrepancies. We have therefore created a methodology protocol to reduce this disparity, using ultrasound in living models and dissection in formalin-fixed cadavers.

Sonographic Methodology (Figure 1)

1. Identify and mark the most prominent part of the head of the fibula and the lateral malleolus and draw a straight line between them.
2. Measure the length of the fibula – Distance between the most prominent parts of the head of the fibula and the lateral malleolus.
3. Position a 6-12MHz linear array ultrasound probe on the distal anterolateral leg, anterior to the lateral malleolus.
4. Move the probe proximally with the point of interest being the location where the SPN penetrates the deep fascia of the leg to lie immediately superficial.
5. With the SPN in the centre of the ultrasound screen, draw the midpoint of each end and side of the probe on the individual's leg.
6. Draw a straight line to connect the midpoints of the sides and another to connect the midpoints of each end creating a cross with the intersection representing the location of the SPN.
7. Draw a straight line from this intersection to bisect the length of fibula line.
8. Measure the distance of emergence from the deep fascia of the SPN anterior or posterior to the length of fibula.
9. Measure the distance between the lateral malleolus and SPN.
10. Measure the distance between the lateral malleolus and the point where the SPN would lie on the length of fibula allowing a ratio to be calculated.

Morphological Methodology (Figure 2)

1. Reflect the skin laterally from the anterior border of the tibia to a line posterior to the intermuscular septum.
2. Continue this reflection as far inferiorly as the anterior intermalleolar line.
3. Carefully explore the superficial fascia to reveal the SPN and its branches.
4. Remove the skin and superficial fascia over the head of the fibula and the lateral malleolus to allow the bony landmarks to be clearly identified.
5. Measure the length of the fibula – Distance between the most prominent parts of the head of the fibula and the lateral malleolus.
6. This creates a baseline which is important for the rest of the measurements.
7. Identify the SPN as it emerges through the deep fascia and follow the SPN inferiorly to the level of the intermalleolar line.
8. Measure the distance between the lateral malleolus to the point of SPN emergence from the deep fascia.
9. Measure the distance of emergence of the SPN anterior or posterior to a point perpendicular to the baseline.
10. Measure the distance between the lateral malleolus to the point where the SPN would lie perpendicularly on the baseline allowing a ratio to be calculated.

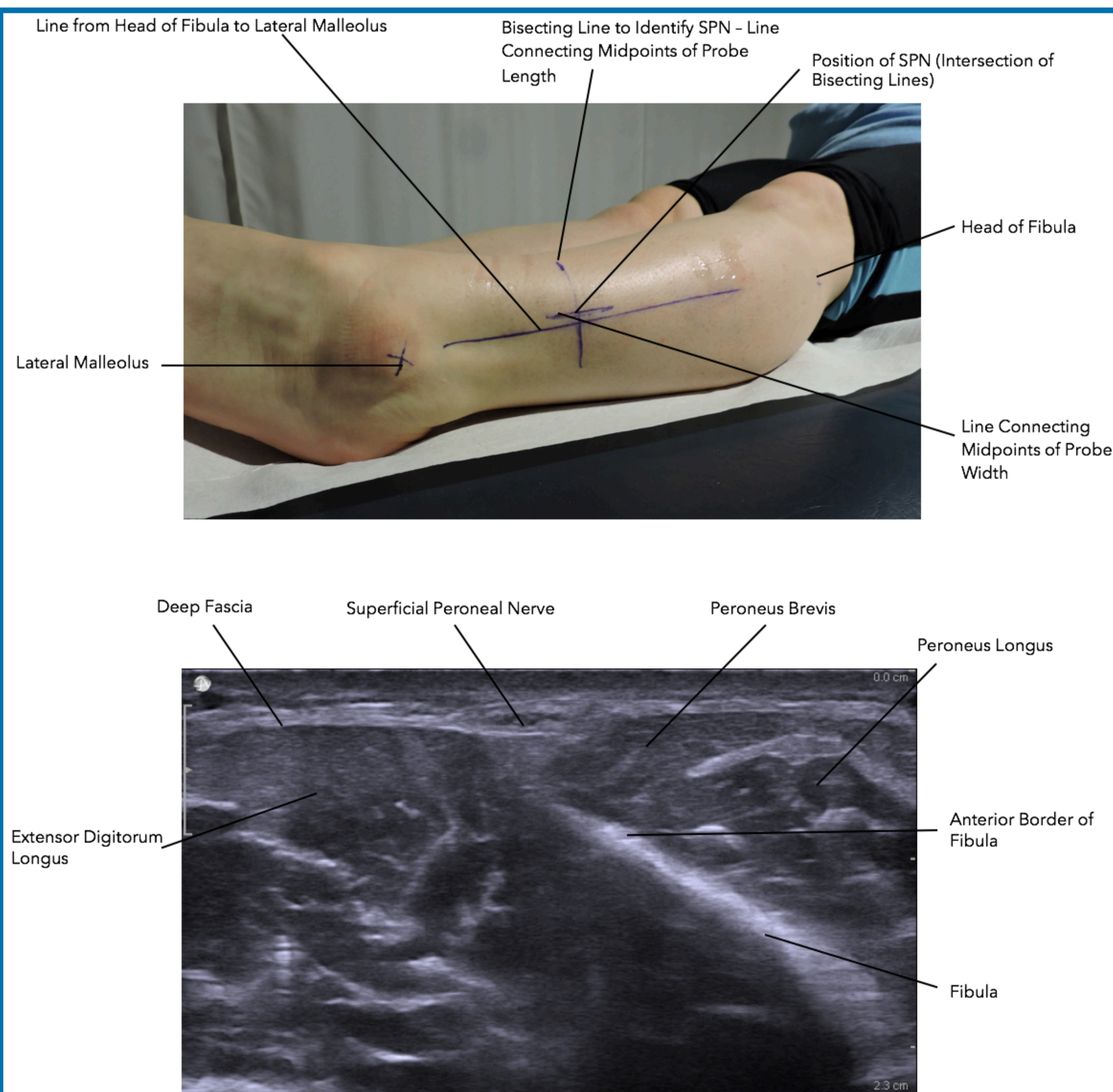


Figure 1 – Markings drawn on an individual's leg and a sonographic picture of the SPN superficial to the deep fascia.




Figure 2 – Cadaveric dissection to show SPN.

Results and Discussion

From the conducted study a methodology protocol for both sonographic and morphological means has been created.

The methodology could be made into a uniform set of guidelines which would be a useful teaching aid both in the classroom, at university and for anaesthetic trainees learning to carry out ankle blocks. With a formal set of guidelines it could reduce incorrect identification and therefore improve success rate of procedures involving the SPN.

References

1. Mahadevan, V. (ed.) (2008) 'Pelvic Girdle and Lower Limb', in Standring, S. (ed.), *GRAY'S Anatomy: The Anatomical Basis of Clinical Practice*. London (UK): Churchill Livingstone Elsevier, p. 1427.
2. Sinнатamby, C. S. (2006) *Last's Anatomy: Regional and Applied*. Eleventh Edition. London (UK): Churchill Livingstone Elsevier.