

Keywords: BRCA; veliparib; pancreatic cancer; oxaliplatin; 5-fluorouracil; DNA damage response

BRCA2 secondary mutation-mediated resistance to platinum and PARP inhibitor-based therapy in pancreatic cancer

Michael J Pishvaian^{*,1}, Andrew V Biankin^{*,2,3,4}, Peter Bailey², David K Chang^{2,3,4}, Daniel Laheru⁵, Christopher L Wolfgang⁶ and Jonathan R Brody⁷

¹Lombardi Comprehensive Cancer Center, Georgetown University Medical Center, Washington, DC, USA; ²Wolfson Wohl Cancer Research Centre, Institute of Cancer Sciences, University of Glasgow, Garscube Estate, Switchback Road, Bearsden, Glasgow G61 1BD, UK; ³West of Scotland Pancreatic Unit, Glasgow Royal Infirmary, Glasgow G31 2ER, UK; ⁴Faculty of Medicine, South Western Sydney Clinical School, University of NSW, Liverpool, New South Wales 2170, Australia; ⁵Sidney Kimmel Comprehensive Cancer Center, Johns Hopkins University, Baltimore, MD, USA; ⁶Department of Surgery, Johns Hopkins University, Baltimore, MD, USA and ⁷Kimmel Cancer Center, Thomas Jefferson University, Philadelphia, PA, USA

Background: Pancreatic cancer has become the third leading cause of cancer death with minimal improvements in outcome for over 40 years. Recent trials of therapies that target-defective DNA maintenance using poly (ADP-ribose) polymerase (PARP) inhibitors are showing promising results, yet invariably patients recur and succumb to disease. Mechanisms of resistance to platinum-based and PARP inhibitor therapy in other cancer types include secondary mutations, which restore the integrity of DNA repair through an increasing number of different mechanisms.

Methods: Here we present a case of a 63-year-old female patient with a germ line pathogenic *BRCA2* mutation (6714 deletion) who developed pancreatic cancer and had an exceptional response to platinum and PARP inhibitor therapy. Through next-generation sequencing and clinical follow-up, we correlated tumour response and resistance to the *BRCA2* mutational status in the tumour.

Results: Initially, the patient had an exceptional response to platinum and PARP inhibitor therapy, most likely due to the *BRCA2* mutation. However, the primary lesion recurred while on PARP inhibitor therapy and contained a secondary mutation in *BRCA2*, which mostly likely restored *BRCA2* function in PARP inhibitor-resistant tumour cells.

Conclusions: To our knowledge, this is the first report of a *BRCA2* reversion mutation that conferred resistance to PARP inhibitor-based therapy in a pancreatic ductal adenocarcinoma patient. Future studies are needed to understand this important mechanism of resistance and how it may impact the choice of therapy for patients with pancreatic cancer.

Emerging data suggest that the subgroup of pancreatic ductal adenocarcinoma (PDA) patients whose tumours harbour defects in genes involved in the homologous recombination pathway, most notably *BRCA1* and *BRCA2* mutations, may benefit significantly from poly (ADP-ribose) polymerase (PARP) inhibitor-based therapy (Lowery *et al*, 2011; Pishvaian *et al*, 2013; O'Reilly *et al*,

2014; Kaufman *et al*, 2015). From a personalised therapy perspective, this patient cohort is sizable as previous reports claim a conservative 5–7% of PDAs harbour mutations in the *BRCA* pathway, whereas more recent sophisticated interrogations of PDA genomes estimate that up to 20% of PDA have defects in DNA damage response, which may confer sensitivity to platinum

*Correspondence: Dr MJ Pishvaian; E-mail: pishvaim@georgetown.edu or Dr AV Biankin; E-mail: andrew.biankin@glasgow.ac.uk

Received 4 October 2016; revised 29 November 2016; accepted 16 January 2017

© 2017 Cancer Research UK. All rights reserved 0007–0920/17

therapy and drugs that specifically target these mechanisms (PARP, ATR, and Wee1 inhibitors; Waddell *et al*, 2015; Bailey *et al*, 2016). In fact, ongoing clinical trials have revealed that patients with BRCA-mutated PDAs are experiencing progression-free survival times of 12 months or more, with frank response rates of over 50%. Unfortunately these patients' tumours eventually develop resistance to PARP inhibitor-based therapy.

Pancreatic ductal adenocarcinoma cells altered in the DNA repair genes, BRCA2, FANCC, and G (labelled as 'BRCA-deficient'), are all hypersensitive to inter-strand cross-linking agents and platinum-based drugs in *in vitro* and *in vivo* models (van der Heijden *et al*, 2005). Ashworth and colleagues showed that cells deficient in genes involved in homologous recombination repair pathway of double-stranded breaks (including BRCA1, BRCA2, RAD51, RAD54, DSS1, RPA1, NBS1, ATR, ATM, CHK1, CHK2, FANCD2, FANCA, or FANCC) are also hypersensitive to PARP inhibitors (Farmer *et al*, 2005; McCabe *et al*, 2006). Hence, PARP inhibitors are being investigated as a therapeutic option for various cancers disrupted in the BRCA pathway, and the PARP inhibitor olaparib (Lynparza, Astra Zeneca, Cambridge, UK) was recently approved for BRCA-mutated ovarian cancer.

Poly (ADP-ribose) polymerase is a nuclear enzyme that plays a critical role in the repair of DNA damage (McCabe *et al*, 2006; Donawho *et al*, 2007; Kummar *et al*, 2009). Thus, PARP inhibition results in less efficient DNA repair following a cytotoxic insult. Consequently, PARP inhibitors act as sensitising agents for a variety of DNA-damaging chemotherapeutic agents and with radiotherapy. Veliparib (ABT-888, Abbvie Inc., Lake Bluff, IL, USA) is a PARP inhibitor that has proven *in vivo* activity (Kummar *et al*, 2009), and increases the sensitivity of tumour cells to chemotherapy, including cisplatin, irinotecan, and temozolomide, and to radiation (Curtin *et al*, 2004; DePinho and Polyak, 2004; Langelier *et al*, 2008; Sharpless and DePinho, 2004). Thus, there are currently dozens of ongoing clinical trials of PARP inhibitor-based combination therapies (ClinicalTrials.gov).

Since the mid-2000s, PARP inhibitor-based therapies have shown promising results in patients with BRCA-mutated cancers (Audeh *et al*, 2010; Fong *et al*, 2010; Tutt *et al*, 2010; Gelmon *et al*, 2011; Lowery *et al*, 2011; Kaye *et al*, 2012; Ledermann *et al*, 2012; Sandhu *et al*, 2013; Kaufman *et al*, 2015; Mateo *et al*, 2015; Oza *et al*, 2015). For example, Audeh *et al* (2010) demonstrated that patients with BRCA-mutated recurrent ovarian cancer had a 33% response rate to single agent olaparib dosed at 400 mg twice daily. Similar results were published by Fong *et al* (2010), though in their cohort of BRCA-mutated ovarian cancer patients, the response rate in platinum-sensitive disease was 61%. Herein, we present a case report of a PDA patient with a germ line BRCA2 mutation who was selected for PARP inhibitor-based therapy.

METHODS AND RESULTS

Our patient is a 63-year-old female who was diagnosed with pancreatic cancer when she initially presented with nausea, vomiting, abdominal pain, and jaundice in April 2014. She had a strong family history of cancer, with her brother having had breast cancer, and her mother having breast cancer and uterine cancer, and her father having prostate cancer. The patient had previously chosen to undergo germ line testing (from a buccal swab) through Myriad on 22 April 2010, which demonstrated a deleterious 6714 deletion mutation in BRCA2. An MRI on 03 April 2014 revealed a 1.7 × 2.1 cm mass in the head of the pancreas, and the patient was referred to Johns Hopkins University Hospital for evaluation. A pancreas protocol CT scan obtained for staging revealed a localised tumour with no vessel involvement. She enrolled in a pre-operative trial of a short course of vaccine (GVAX) therapy with 7

days of oral cyclophosphamide (50 mg daily) pre-operatively. Then on 01 May 2014, the patient underwent surgical exploration for an intended pancreaticoduodenectomy. Unfortunately, intra-operatively, she was found to have metastatic disease to the liver, which was proven on an intraoperative frozen section. The liver lesion was excised and sent to Foundation Medicine for next-generation sequencing of cancer-related genes (Foundation ONE test), the results of which revealed a pathogenic BRCA2 mutation (c.6486_6489delACAA p.K2162fs*5), a four base pair deletion that resulted in a premature STOP codon (Figure 2). Careful review of the BRCA2 mutation identified in the tumour specimen by Foundation Medicine (and discussion with Foundation Medicine) have confirmed that the specific mutation was the same as the patient's germ line BRCA2 mutation identified on the buccal swab. Of note, an assessment of the mutational allele frequency (MAF) revealed that the MAF of the BRCA2 mutation was 61% – thus a higher allele frequency than would be expected for a purely heterozygous state, and suggesting that there was loss of heterozygosity in a portion of the cancer cells. However, because the tested sample was not of isolated tumour cells, adjacent stromal cell contamination may have affected the MAF results, and the MAF purely in the tumour cells may actually have been higher than 61%. The tumour also exhibited a KRAS G12V and a TP53 mutation (P295fs*50) both typical for pancreatic adenocarcinomas.

After recovery from surgery, the patient was seen at Georgetown University for enrolment in an IRB-approved Phase I/II trial of 5-FU, oxaliplatin, and veliparib (NCT01489865). Her pre-treatment CA 19-9 was 31.5, and her baseline imaging revealed a pancreatic head mass 1.7 cm × 1.7 cm, as well as a left lobe liver lesion, 2.3 cm × 2.0 cm (Figure 1A, baseline imaging). The treatment consisted of the standard modified FOLFOX6 regimen with oxaliplatin (85 mg m⁻²) Day 1, and continuous infusion 5-fluorouracil (2400 mg m⁻²) Days 1–3 but without the 5-fluorouracil bolus. She also received veliparib 200 mg orally twice a day for 7 days, and the cycles were repeated every 2 weeks. Our patient began therapy on 05 June 2014, and had a fair degree of nausea and vomiting, ultimately requiring the dose of veliparib to be reduced by 50%, to 100 mg twice a day. She also had to stop the oxaliplatin after Cycle 13 for neuropathy. Nevertheless, the patient stayed on therapy for 31 cycles, through 10 August 2015 (progression-free survival = 15 months). While on study, she experienced a near complete response, with a virtual radiographic disappearance of the liver lesion and pancreatic head lesion by 23 March 2015 (Figure 1B, near complete response imaging). Then, starting 18 May 2015, her imaging revealed renewed progression of the pancreatic head mass. Interestingly, the re-growth, in retrospect, was eccentric, when compared to the primary pancreatic mass, visually suggesting growth of an independent, resistant clone on the periphery (Figure 1C and D, emerging resistance imaging).

Per RECIST criteria, the patient had developed progressive disease by 10 August 2015, but her disease burden was still minimal, and there was no evidence of extrapancreatic disease. On the basis of the lack of development of additional liver lesions and the response to systemic therapy, the patient underwent surgical exploration on 10 September 2015 at the Johns Hopkins University Hospital with the intent of performing a pancreaticoduodenectomy. The only identifiable liver lesion was resected and found to be scar tissue on intraoperative frozen section. As a result of these intraoperative findings the patient underwent a margin-negative pancreaticoduodenectomy at that time. Final pathology revealed a primary pancreatic adenocarcinoma with 3 out of 24 local lymph nodes positive for disease. Final pathology confirmed only scar within the liver lesion. She had an unremarkable recovery from the operation.

After resection, due to the patient's reluctance to have additional cytotoxic chemotherapy she initiated olaparib as a maintenance strategy in place of cytotoxic adjuvant therapy. She was treated at

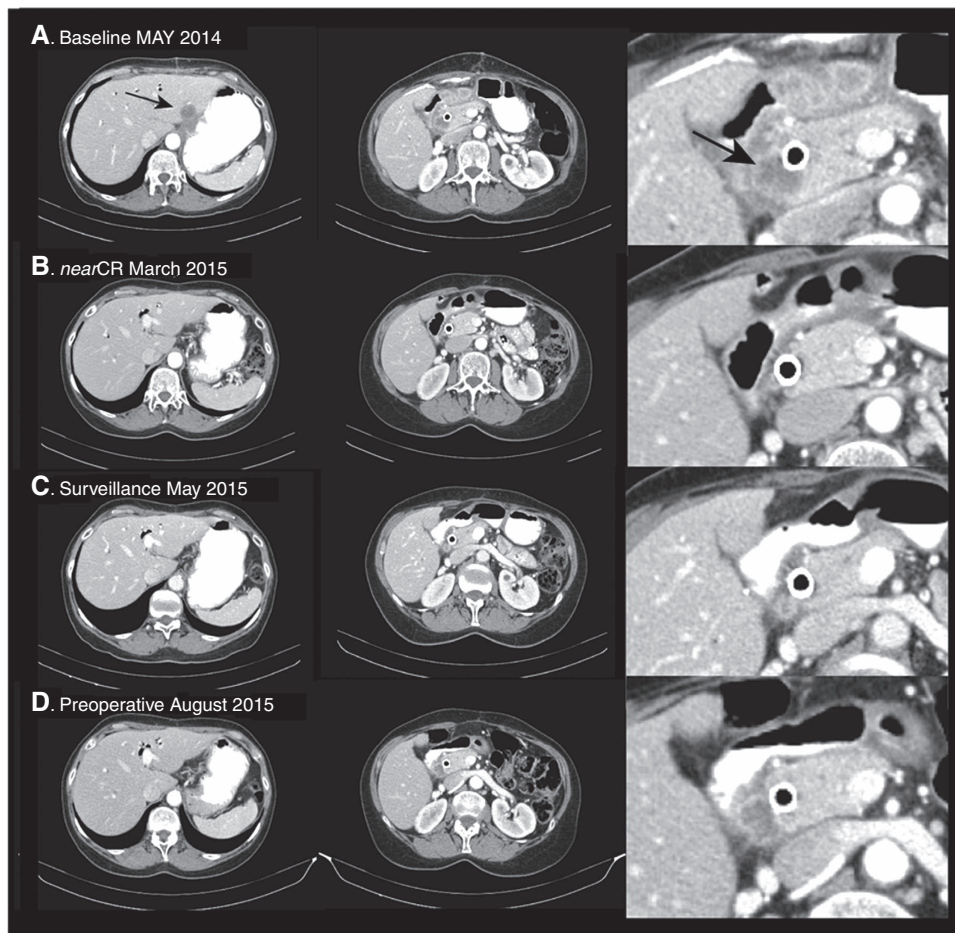


Figure 1. Patient images. The baseline scans from 28 May 2014 revealed a liver lesion and pancreatic mass. These lesions slowly improved on veliparib, 5-FU, and oxaliplatin therapy, and by 23 March 2015, the liver lesion was not visible, and the pancreatic mass was barely visible. However, from May 2015 to August 2015, there was steady re-growth of what proved to be a resistant clone in the pancreas, eccentric from the original mass.

400 mg orally twice a day, but quickly needed to reduce the dose to 200 mg twice a day due to nausea and fatigue. During this time, the resection specimen was re-sent to Foundation Medicine, which again reported the original mutations (including the identical *KRAS* and *TP53* mutations), but also revealed a new somatic (secondary) *BRCA2* mutation (c.6448_6473delAAAAGTTTCTCCA TATCTCTCTCAATT p.K2150fs*17). This somatic 26 base deletion in the *BRCA2* gene was located 13 bases upstream of the germ line 4 base pair deletion of the same allele. This secondary somatic deletion restored the reading frame of the *BRCA2* gene, which contained the four base deletion (Figure 2). Interestingly, the MAF of the secondary mutation from the pancreatic resection specimen was only 8%, whereas the MAF of the germ line *BRCA2* mutation was reduced to 52%. These results suggest that only a relatively small portion of the mutated alleles harboured this secondary mutation. Clinically, immediately following the pancreaticoduodenectomy, there was no evidence of recurrent metastatic disease and the functional consequences of this secondary mutation in this context were not known. That is, although the reading frame was restored, there was no knowledge of whether this produced a fully, or even hypo-functional *BRCA2*. As a consequence, olaparib was continued. Unfortunately, by early January, 2016 the patient was clearly becoming symptomatic, and imaging revealed early peritoneal carcinomatosis, suggesting olaparib offered no control of her disease. Thus, she was taken off therapy, and was able to enrol in an immunotherapy trial of the combination of the CXCR2 antagonist, AZD5069, and durvalumab (NCT02499328). While on

study, she developed suppurative cholecystitis, and passed away on 24 May 2016.

CONCLUSIONS

Many PARP inhibitor resistance mechanisms have been proposed (Montoni *et al*, 2013), but Sakai *et al* (2008) and Edwards *et al* (2008) were the first to describe that *BRCA2* reversion mutations could confer resistance to PARP inhibitor-based therapy (Ashworth, 2008). They demonstrated that the PDA cell line CAPAN1 that has lost one copy of the *BRCA2* gene and harbours a c.6174delT mutation in the other, are exquisitely sensitive to potent PARP inhibitors (McCabe *et al*, 2005). In the cell line, this mutation was accompanied by a loss of the wild-type copy of the *BRCA2* gene, yet made a truncated protein ~2000 amino acids. This study, albeit in just one cell line, demonstrated that PARP inhibitors targeted this *BRCA2* genetic lesion by showing that isogenic cells generated to become >1000-fold resistant harboured a secondary mutation, which restored the open reading frame of the *BRCA2* sequence, and thus restoring the DNA repair function (i.e., RAD51 binding to the BRCA repeats; Ashworth, 2008).

Subsequently, others also demonstrated the presence of secondary *BRCA1/2* mutations that confer resistance to therapy in *BRCA1/2*-mutated ovarian cancer patients, whose tumours had become resistant to platinum-based therapies (Swisher *et al*, 2008;




Figure 2. Germ line and secondary *BRCA2* mutations in pancreatic cancer. **(A)** Location of mutations in exon 11 – note proximity. **(B)** The germ line mutation with the deletion highlighted in yellow, with **(C)** showing the resultant transcript with a premature STOP codon. **(D)** shows the secondary somatic mutation in normal *BRCA2* sequence, with **(E)** showing the secondary mutation in the context of the germ line deletion with restoration of the reading frame. The green box with arrow shows how the secondary mutation brings the coding region back into the correct reading frame. A full colour version of this figure is available at the *British Journal of Cancer* journal online

Norquist *et al*, 2011), and may occur through a variety of mechanisms that would not be detected using NGS for selected genes and may require whole-genome sequencing (Patch *et al*, 2015). Importantly, Sakai *et al* (2008) demonstrated that the platinum-resistant, *BRCA2* functionally reverted ovarian cancer cell lines also demonstrate resistance to PARP inhibitor therapy. Additional studies in breast and ovarian cancer patients described the development of *BRCA* reversion and PARP inhibitor resistance (Barber *et al*, 2013). Of note, Ang *et al* (2013) assessed response to chemotherapy including platinum-based chemotherapy in patients with PARP inhibitor (olaparib)-resistant ovarian cancer. Surprisingly, these PARP inhibitor-resistant ovarian cancers retained sensitivity to chemotherapies including platinum. However, these observations were confounded by the fact that none of the PARP inhibitor-resistant ovarian cancers were found to have *BRCA* reversion events, thus providing evidence that other mechanisms may be at play such as defects in drug transport or drug metabolism.

As our patient received several therapies, including those that target similar mechanisms such as platinum and PARP inhibition, it is difficult to be definitive. Yet it is reasonable that either the platinum and/or the PARP inhibitor induced selection pressure on the tumour to restore defective DNA damage response mechanisms. To our knowledge, this is the first report of a *BRCA2* reversion mutation, which conferred resistance to PARP inhibitor-based therapy in a PDA patient. Future studies are needed to understand this important mechanism of resistance and how it may impact the choice of therapy for patients with pancreatic cancer. Central to this approach is the assessment of tumour biopsies pre- and post treatment.

ACKNOWLEDGEMENTS

We wish to thank the Ruesch Center for the Cure of Gastrointestinal Cancers for support of the clinical trial; Abbvie Inc. for supplying the veliparib; and Foundation Medicine for providing detailed analyses of the tumour mutational testing. Also, the 2015 Pancreatic Cancer Action Network American Association for Cancer Research Acceleration Network Grant (15-90-25-BROD).

CONFLICT OF INTEREST

The authors declare no conflict of interest.

REFERENCES

- Ang JE, Gourley C, Powell CB, High H, Shapira-Frommer R, Castonguay V, De Greve J, Atkinson T, Yap TA, Sandhu S, Banerjee S, Chen LM, Friedlander ML, Kaufman B, Oza AM, Matulonis U, Barber LJ, Kozarewa I, Fenwick K, Assiotis I, Campbell J, Chen L, de Bono JS, Gore ME, Lord CJ, Ashworth A, Kaye SB (2013) Efficacy of chemotherapy in *BRCA1/2* mutation carrier ovarian cancer in the setting of PARP inhibitor resistance: a multi-institutional study. *Clin Cancer Res* **19**(19): 5485–5493.
- Ashworth A (2008) Drug resistance caused by reversion mutation. *Cancer Res* **68**(24): 10021–10023.
- Audeh MW, Carmichael J, Penson RT, Friedlander M, Powell B, Bell-McGuinn KM, Scott C, Weitzel JN, Oaknin A, Loman N, Lu K, Schmutzler RK, Matulonis U, Wickens M, Tutt A (2010) Oral poly (ADP-ribose) polymerase inhibitor olaparib in patients with *BRCA1* or *BRCA2* mutations and recurrent ovarian cancer: a proof-of-concept trial. *Lancet* **376**(9737): 245–251.
- Bailey P, Chang DK, Nones K, Johns AL, Patch AM, Gingras MC, Miller DK, Christ AN, Bruxner TJ, Quinn MC, Nourse C, Murtaugh LC, Harliwong I, Idrisoglu S, Manning S, Nourbakhsh E, Wani S, Fink L, Holmes O, Chin V, Anderson MJ, Kazakoff S, Leonard C, Newell F, Waddell N, Wood S, Xu Q, Wilson PJ, Cloonan N, Kassahn KS, Taylor D, Quek K, Robertson A, Pantano L, Mincarelli L, Sanchez LN, Evers L, Wu J, Pinese M, Cowley MJ, Jones MD, Colvin EK, Nagrial AM, Humphrey ES, Chantrill LA, Mawson A, Humphris J, Chou A, Pajic M, Scarlett CJ, Pinho AV, Giry-Laterriere M, Rooman I, Samra JS, Kench JG, Lovell JA, Merrett ND, Toon CW, Epari K, Nguyen NQ, Barbour A, Zeps N, Moran-Jones K, Jamieson NB, Graham JS, Duthie F, Oien K, Hair J, Grutzmann R, Maitra A, Iacobuzio-Donahue CA, Wolfgang CL, Morgan RA, Lawlor RT, Corbo V, Bassi C, Rusev B, Capelli P, Salvia R, Tortora G, Mukhopadhyay D, Petersen GM. Australian Pancreatic Cancer Genome IMunzy DM, Fisher WE, Karim SA, Eshleman JR, Hruban RH, Pilarsky C, Morton JP, Sansom OJ, Scarpa A, Musgrove EA, Bailey UM, Hofmann O, Sutherland RL, Wheeler DA, Gill AJ, Gibbs RA, Pearson JV, Waddell N, Biankin AV, Grimmond SM (2016) Genomic

- analyses identify molecular subtypes of pancreatic cancer. *Nature* **531**(7592): 47–52.
- Barber LJ, Sandhu S, Chen L, Campbell J, Kozarewa I, Fenwick K, Assiotis I, Rodrigues DN, Reis Filho JS, Moreno V, Mateo J, Molife LR, De Bono J, Kaye S, Lord CJ, Ashworth A (2013) Secondary mutations in BRCA2 associated with clinical resistance to a PARP inhibitor. *J Pathol* **229**(3): 422–429.
- Curtin NJ, Wang LZ, Yiakouvaki A, Kyle S, Arris CA, Canan-Koch S, Webber SE, Durkacz BW, Calvert HA, Hostomsky Z, Newell DR (2004) Novel poly (ADP-ribose) polymerase-1 inhibitor, AG14361, restores sensitivity to temozolomide in mismatch repair-deficient cells. *Clin Cancer Res* **10**(3): 881–889.
- DePinho RA, Polyak K (2004) Cancer chromosomes in crisis. *Nat Genet* **36**(9): 932–934.
- Donawho CK, Luo Y, Luo Y, Penning TD, Bauch JL, Bouska JJ, Bontcheva-Diaz VD, Cox BF, DeWeese TL, Dillehay LE, Ferguson DC, Ghoreishi-Haack NS, Grimm DR, Guan R, Han EK, Holley-Shanks RR, Hristov B, Idler KB, Jarvis K, Johnson EF, Kleinberg LR, Klinghofer V, Lasko LM, Liu X, Marsh KC, McGonigal TP, Meulbroek JA, Olson AM, Palma JP, Rodriguez LE, Shi Y, Stavropoulos JA, Tsurutani AC, Zhu GD, Rosenberg SH, Giranda VL, Frost DJ (2007) ABT-888, an orally active poly (ADP-ribose) polymerase inhibitor that potentiates DNA-damaging agents in preclinical tumor models. *Clin Cancer Res* **13**(9): 2728–2737.
- Edwards SL, Brough R, Lord CJ, Natrajn R, Vatcheva R, Levine DA, Boyd J, Reis-Filho JS, Ashworth A (2008) Resistance to therapy caused by intragenic deletion in BRCA2. *Nature* **451**(7182): 1111–1115.
- Farmer H, McCabe N, Lord CJ, Tutt AN, Johnson DA, Richardson TB, Santarosa M, Dillon KJ, Hickson I, Knights C, Martin NM, Jackson SP, Smith GC, Ashworth A (2005) Targeting the DNA repair defect in BRCA mutant cells as a therapeutic strategy. *Nature* **434**(7035): 917–921.
- Fong PC, Yap TA, Boss DS, Carden CP, Mergui-Roelvink M, Gourley C, De Greve J, Lubinski J, Shanley S, Messiou C, A'Hern R, Tutt A, Ashworth A, Stone J, Carmichael J, Schellens JH, de Bono JS, Kaye SB (2010) Poly(ADP)-ribose polymerase inhibition: frequent durable responses in BRCA carrier ovarian cancer correlating with platinum-free interval. *J Clin Oncol* **28**(15): 2512–2519.
- Gelmon KA, Tischkowitz M, Mackay H, Swenerton K, Robidoux A, Tonkin K, Hirte H, Huntsman D, Clemons M, Gilks B, Yerushalmi R, Macpherson E, Carmichael J, Oza A (2011) Olaparib in patients with recurrent high-grade serous or poorly differentiated ovarian carcinoma or triple-negative breast cancer: a phase 2, multicentre, open-label, non-randomised study. *Lancet Oncol* **12**(9): 852–861.
- Kaufman B, Shapira-Frommer R, Schmutzler RK, Audeh MW, Friedlander M, Balmana J, Mitchell G, Fried G, Stemmer SM, Hubert A, Rosengarten O, Steiner M, Loman N, Bowen K, Fielding A, Domchek SM (2015) Olaparib monotherapy in patients with advanced cancer and a germline BRCA1/2 mutation. *J Clin Oncol* **33**(3): 244–250.
- Kaye SB, Lubinski J, Matulonis U, Ang JE, Gourley C, Karlan BY, Amnon A, Bell-McGuinn KM, Chen LM, Friedlander M, Safra T, Vergote I, Wickens M, Lowe ES, Carmichael J, Kaufman B (2012) Phase II, open-label, randomized, multicenter study comparing the efficacy and safety of olaparib, a poly (ADP-ribose) polymerase inhibitor, and pegylated liposomal doxorubicin in patients with BRCA1 or BRCA2 mutations and recurrent ovarian cancer. *J Clin Oncol* **30**(4): 372–379.
- Kummar S, Kinders R, Gutierrez ME, Rubinstein L, Parchment RE, Phillips LR, Ji J, Monks A, Low JA, Chen A, Murgu AJ, Collins J, Steinberg SM, Eliopoulos H, Giranda VL, Gordon G, Helman L, Wiltrout R, Tomaszewski JE, Doroshow JH (2009) Phase 0 clinical trial of the poly (ADP-ribose) polymerase inhibitor ABT-888 in patients with advanced malignancies. *J Clin Oncol* **27**(16): 2705–2711.
- Langelier MF, Servent KM, Rogers EE, Pascal JM (2008) A third zinc-binding domain of human poly (ADP-ribose) polymerase-1 coordinates DNA-dependent enzyme activation. *J Biol Chem* **283**(7): 4105–4114.
- Ledermann J, Harter P, Gourley C, Friedlander M, Vergote I, Rustin G, Scott C, Meier W, Shapira-Frommer R, Safra T, Matei D, Macpherson E, Watkins C, Carmichael J, Matulonis U (2012) Olaparib maintenance therapy in platinum-sensitive relapsed ovarian cancer. *N Engl J Med* **366**(15): 1382–1392.
- Lowery MA, Kelsen DP, Stadler ZK, Yu KH, Janjigian YY, Ludwig E, D'Adamo DR, Salo-Mullen E, Robson ME, Allen PJ, Kurtz RC, O'Reilly EM (2011) An emerging entity: pancreatic adenocarcinoma associated with a known BRCA mutation: clinical descriptors, treatment implications, and future directions. *Oncologist* **16**(10): 1397–1402.
- Mateo J, Carreira S, Sandhu S, Miranda S, Mossop H, Perez-Lopez R, Nava Rodrigues D, Robinson D, Omlin A, Tunariu N, Boysen G, Porta N, Flohr P, Gillman A, Figueiredo I, Paulding C, Seed G, Jain S, Ralph C, Protheroe A, Hussain S, Jones R, Elliott T, McGovern U, Bianchini D, Goodall J, Zafeiriou Z, Williamson CT, Ferraldeschi R, Riisnaes R, Ebbs B, Fowler G, Roda D, Yuan W, Wu YM, Cao X, Brough R, Pemberton H, A'Hern R, Swain A, Kunju LP, Eeles R, Attard G, Lord CJ, Ashworth A, Rubin MA, Knudsen KE, Feng FY, Chinnaiyan AM, Hall E, de Bono JS (2015) DNA-repair defects and olaparib in metastatic prostate cancer. *N Engl J Med* **373**(18): 1697–1708.
- McCabe N, Lord CJ, Tutt AN, Martin NM, Smith GC, Ashworth A (2005) BRCA2-deficient CAPAN-1 cells are extremely sensitive to the inhibition of poly (ADP-ribose) polymerase: an issue of potency. *Cancer Biol Ther* **4**(9): 934–936.
- McCabe N, Turner NC, Lord CJ, Kluzek K, Bialkowska A, Swift S, Giavara S, O'Connor MJ, Tutt AN, Zdzienicka MZ, Smith GC, Ashworth A (2006) Deficiency in the repair of DNA damage by homologous recombination and sensitivity to poly (ADP-ribose) polymerase inhibition. *Cancer Res* **66**(16): 8109–8115.
- Montoni A, Robu M, Pouliot E, Shah GM (2013) Resistance to PARP-inhibitors in cancer therapy. *Front Pharmacol* **4**: 18.
- Norquist B, Wurz KA, Pennil CC, Garcia R, Gross J, Sakai W, Karlan BY, Taniguchi T, Swisher EM (2011) Secondary somatic mutations restoring BRCA1/2 predict chemotherapy resistance in hereditary ovarian carcinomas. *J Clin Oncol* **29**(22): 3008–3015.
- O'Reilly EM, Lowery MA, Segal MF, Smith SC, Moore MJ, Kindler HL, Golan T, Segal A, Salo-Mullen EE, Hollywood E, Epstein AS, Capanu M, Moynahan ME, Fusco A, Stadler ZK, Do RKG, Chen AP, Yu KH, Tang LH, Kelsen DP (2014) Phase IB trial of cisplatin (C), gemcitabine (G), and veliparib (V) in patients with known or potential BRCA or PALB2-mutated pancreas adenocarcinoma (PC). *J Clin Oncol* **32**(5s suppl): abstr 4023.
- Oza AM, Cibula D, Benzaquen AO, Poole C, Mathijssen RH, Sonke GS, Colombo N, Spacek J, Vuylsteke P, Hirte H, Mahner S, Plante M, Schmalfeldt B, Mackay H, Rowbottom J, Lowe ES, Dougherty B, Barrett JC, Friedlander M (2015) Olaparib combined with chemotherapy for recurrent platinum-sensitive ovarian cancer: a randomised phase 2 trial. *Lancet Oncol* **16**(1): 87–97.
- Patch AM, Christie EL, Etemadmoghadam D, Garsed DW, George J, Feraday S, Nones K, Cowin P, Alsop K, Bailey PJ, Kassahn KS, Newell F, Quinn MC, Kazakoff S, Quek K, Wilhelm-Benartzi C, Curry E, Leong HS, Australian Ovarian Cancer Study GHamilton A, Mileshekin L, Au-Yeung G, Kennedy C, Hung J, Chiew YE, Harnett P, Friedlander M, Quinn M, Pyman J, Cordner S, O'Brien P, Leditschke J, Young G, Strachan K, Waring P, Azar W, Mitchell C, Traficante N, Hendley J, Thorne H, Shackleton M, Miller DK, Arnau GM, Tohill RW, Holloway TP, Semple T, Harliwong I, Nourse C, Nourbakhsh E, Manning S, Idrisoglu S, Bruxner TJ, Christ AN, Poudel B, Holmes O, Anderson M, Leonard C, Lonie A, Hall N, Wood S, Taylor DF, Xu Q, Fink JL, Waddell N, Drapkin R, Stronach E, Gabra H, Brown R, Jewell A, Nagaraj SH, Markham E, Wilson PJ, Ellul J, McNally O, Doyle MA, Vedururu R, Stewart C, Lengyel E, Pearson JV, Waddell N, deFazio A, Grimmond SM, Bowtell DD (2015) Whole-genome characterization of chemoresistant ovarian cancer. *Nature* **521**(7553): 489–494.
- Pishvaian MJ, Wang H, Zhuang T, He AR, Hwang JJ, Hankin A, Ley L, White K, Littman SJ, Weiner LM, Marshall J, Brody JR (2013) A phase I/II study of ABT-888 in combination with 5-fluorouracil (5-FU) and oxaliplatin (Ox) in patients with metastatic pancreatic cancer (MPC). *J Clin Oncol suppl* **4**: abstr 147.
- Sakai W, Swisher EM, Karlan BY, Agarwal MK, Higgins J, Friedman C, Villegas E, Jacquemont C, Farrugia DJ, Couch FJ, Urban N, Taniguchi T (2008) Secondary mutations as a mechanism of cisplatin resistance in BRCA2-mutated cancers. *Nature* **451**(7182): 1116–1120.
- Sandhu SK, Schelman WR, Wilding G, Moreno V, Baird RD, Miranda S, Hylands L, Riisnaes R, Forster M, Omlin A, Kreischer N, Thway K, Gevensleben H, Sun L, Loughney J, Chatterjee M, Toniatti C, Carpenter CL, Iannone R, Kaye SB, de Bono JS, Wenham RM (2013) The poly (ADP-ribose) polymerase inhibitor niraparib (MK4827) in BRCA mutation carriers and patients with sporadic cancer: a phase I dose-escalation trial. *Lancet Oncol* **14**(9): 882–892.
- Sharpless NE, DePinho RA (2004) Telomeres, stem cells, senescence, and cancer. *J Clin Invest* **113**(2): 160–168.

- Swisher EM, Sakai W, Karlan BY, Wurz K, Urban N, Taniguchi T (2008) Secondary BRCA1 mutations in BRCA1-mutated ovarian carcinomas with platinum resistance. *Cancer Res* **68**(8): 2581–2586.
- Tutt A, Robson M, Garber JE, Domchek SM, Audeh MW, Weitzel JN, Friedlander M, Arun B, Loman N, Schmutzler RK, Wardley A, Mitchell G, Earl H, Wickens M, Carmichael J (2010) Oral poly (ADP-ribose) polymerase inhibitor olaparib in patients with BRCA1 or BRCA2 mutations and advanced breast cancer: a proof-of-concept trial. *Lancet* **376**(9737): 235–244.
- van der Heijden MS, Brody JR, Dezentje DA, Gallmeier E, Cunningham SC, Swartz MJ, DeMarzo AM, Offerhaus GJ, Isacoff WH, Hruban RH, Kern SE (2005) *In vivo* therapeutic responses contingent on Fanconi anemia/BRCA2 status of the tumor. *Clin Cancer Res* **11**(20): 7508–7515.
- Waddell N, Pajic M, Patch AM, Chang DK, Kassahn KS, Bailey P, Johns AL, Miller D, Nones K, Quek K, Quinn MC, Robertson AJ, Fadlullah MZ, Bruxner TJ, Christ AN, Harliwong I, Idrisoglu S, Manning S, Nourse C, Nourbakhsh E, Wani S, Wilson PJ, Markham E, Cloonan N, Anderson MJ, Fink JL, Holmes O, Kazakoff SH, Leonard C, Newell F, Poudel B, Song S, Taylor D, Waddell N, Wood S, Xu Q, Wu J, Pinese M, Cowley MJ, Lee HC, Jones MD, Nagrial AM, Humphris J, Chantrill LA, Chin V, Steinmann AM, Mawson A, Humphrey ES, Colvin EK, Chou A, Scarlett CJ, Pinho AV, Giry-Laterriere M, Rooman I, Samra JS, Kench JG, Pettitt JA, Merrett ND, Toon C, Epari K, Nguyen NQ, Barbour A, Zeps N, Jamieson NB, Graham JS, Niclou SP, Bjerkvig R, Grutzmann R, Aust D, Hruban RH, Maitra A, Iacobuzio-Donahue CA, Wolfgang CL, Morgan RA, Lawlor RT, Corbo V, Bassi C, Falconi M, Zamboni G, Tortora G, Tempero MA. Australian Pancreatic Cancer Genome IGill AJ, Eshleman JR, Pilarsky C, Scarpa A, Musgrove EA, Pearson JV, Biankin AV, Grimmond SM (2015) Whole genomes redefine the mutational landscape of pancreatic cancer. *Nature* **518**(7540): 495–501.

This work is published under the standard license to publish agreement. After 12 months the work will become freely available and the license terms will switch to a Creative Commons Attribution-NonCommercial-Share Alike 4.0 Unported License.