

# Biochemical and molecular mechanisms of diabetic retinopathy

M. Balasubramanyam\*, M. Rema and C. Premanand

Madras Diabetes Research Foundation, Gopalapuram, Chennai 600 086, India

Diabetic retinopathy is one of the most common devastating complications of diabetes. Currently there are no accepted drug treatments for diabetic retinopathy and laser therapy is the most accepted treatment option. Biochemical and physiological changes that occur very early in the retina of diabetic patients are the major signaling determinants of future damage to the retina. However, drug treatment for diabetic retinopathy that will specifically ameliorate biochemical defects, is still only at an experimental stage. Research during the past few decades has provided ample evidence that hyperglycaemia is one of the main factors driving the onset and progression of diabetic retinopathy. Furthermore, hyperglycaemia-induced events regulate a variety of cellular signals including the stimulation of growth factors that are implicated in retinopathy. It is possible that in the future, novel therapeutic measures may emerge for the treatment of diabetic retinopathy. In order to discover anti-permeability and anti-angiogenic compounds, a more comprehensive understanding of the mechanisms governing the vascularization of the retina is required. Some of the experimental approaches currently under investigation, such as protein kinase C inhibitors, VEGF inhibitors, pigment epithelium-derived factor, and many others may prove useful as new therapeutic approaches in the treatment of various stages of diabetic retinopathy. Significant efforts continue to be directed toward the evaluation of the mechanisms underlying diabetic retinopathy in order to achieve newer and better therapies for this potentially preventable cause of blindness.

DIABETIC retinopathy is one of the most common microvascular complications of diabetes, affecting 80% of patients over 20 years duration of diabetes. Despite remarkable advances in the diagnosis and treatment of diabetic retinopathy and its associated complications, diabetic retinopathy remains the leading cause of blindness among working-age individuals in developed countries. In developing countries like India also, it may become one of the major causes of blindness in view of the prevailing diabetes epidemic. In an epidemiological study done at Chennai, the Chennai Urban Population Study (CUPS) involving two residential colonies of

Chennai, the overall prevalence of diabetic retinopathy among the 1262 eligible subjects was 19.0%, which included 17.5% with non-proliferative diabetic retinopathy and 1.5% with proliferative diabetic retinopathy<sup>1</sup>. In a clinic-based study<sup>2</sup> the overall prevalence of diabetic retinopathy was 33.4% in Type 2 diabetic patients. The sight-threatening lesions of diabetic retinopathy with maculopathy was 8% and proliferative diabetic retinopathy was 3% in this study. Interestingly, another study showed that 7% of Type 2 diabetic patients had diabetic retinopathy even at the time of diagnosis of diabetes<sup>3</sup>. Familial clustering of diabetic retinopathy was also demonstrated in a large clinic-based study where the siblings of Type 2 diabetes mellitus with diabetic retinopathy were 3.4 times more prone to develop diabetic retinopathy than the siblings of Type 2 diabetics without retinopathy<sup>4</sup>. The prevalence of DR among the known and newly diagnosed diabetes was 23.1% and 10.9% respectively. Diabetes and visual disability due to diabetic retinopathy thus remain a serious health and socio-economic problem in India. This review summarizes the complex cellular and molecular pathogenesis of diabetic retinopathy with particular reference to biochemical pathways, early damage to the retinal cells and new vessel formation.

## Clinical pathogenesis and classification of diabetic retinopathy

Diabetic retinopathy is detected clinically by the presence of visible ophthalmoscopic retinal microvascular lesions in an individual with diabetes mellitus. The classification of diabetic retinopathy has evolved as our understanding of diabetic eye disease has increased. Retinopathy has been broadly classified as nonproliferative (NPDR) and proliferative diabetic retinopathy (PDR). NPDR is again divided into NPDR with maculopathy, NPDR without maculopathy and pre-proliferative retinopathy. NPDR indicates progressive ischemia in the retina and an increased risk for the development of PDR and blindness. The prominent clinical features of NPDR include microaneurysms, dot or blot haemorrhages, venous abnormalities, hard yellow exudates, intraretinal microvascular abnormalities, and cotton wool spots. Microaneurysms are focal outpouchings of the capillary

\*For correspondence. (e-mail: mvdsc@vsnl.net)

wall in the region of vascular occlusions<sup>5</sup>. Hemorrhages and exudates result from the damaged vasculature. Increase in retinal blood flow and vasodilation occurs early in the course of the disease, followed by the microvascular leakage and occlusion, and histologic data corroborates the clinical evidence<sup>6,7</sup>. Maculopathy is defined as the presence of edema and/or haemorrhages and/or exudates and/or retinal thickening within 500  $\mu$  (i.e., 1 disc diopter) of the fovea, with or without visual loss. Proliferative diabetic retinopathy is the stage before the onset of neovascularization and is characterized by (a) extensive retinal haemorrhages, (b) marked venous beading, (c) numerous cotton wool spots or retinal infarcts, (d) intra-retinal microvasculature abnormalities (IRMA), and (e) marked retinal ischaemia as evidenced by capillary drop outs in the fundus fluorescein angiogram. Proliferative diabetic retinopathy is characterized by retinal new vessels (neovascularization), fibrous tissue, pre-retinal haemorrhage, vitreous haemorrhage, vitreoretinal traction and localized retinal detachment.

### Current treatments for diabetic retinopathy

Laser photocoagulation is the primary means by which ophthalmologists control the progression of macular edema and neovascularization. The short and long-term beneficial effects of photocoagulation have led to its wide clinical acceptance for the treatment of proliferative diabetic retinopathy. This treatment was first described in 1950 (ref. 8) and involves the creation of thermal chorioretinal burns that cauterize leaking microaneurysms and ablate hypoxic retinal tissue. Laser increases O<sub>2</sub> diffusion from the choroid to the retina<sup>9</sup> and decreases the volume of ischemic tissue so that the available O<sub>2</sub> and substrates are adequate to nourish the remaining retina. Although its exact mode of action is still unknown, laser photocoagulation may exert its beneficial effect by altering angiostatic and/or angiogenic factors, thus decreasing the hypoxia in the retina. Unfortunately, there are many patients in whom laser therapy cannot be done due to an obstructing vitreous hemorrhage or severe fibrous proliferation. Since laser photocoagulation is still an invasive procedure destroying the retinal cells, future pharmacotherapeutic approaches should be developed to prevent or regress retinal lesions in diabetic subjects.

### Biochemical defects

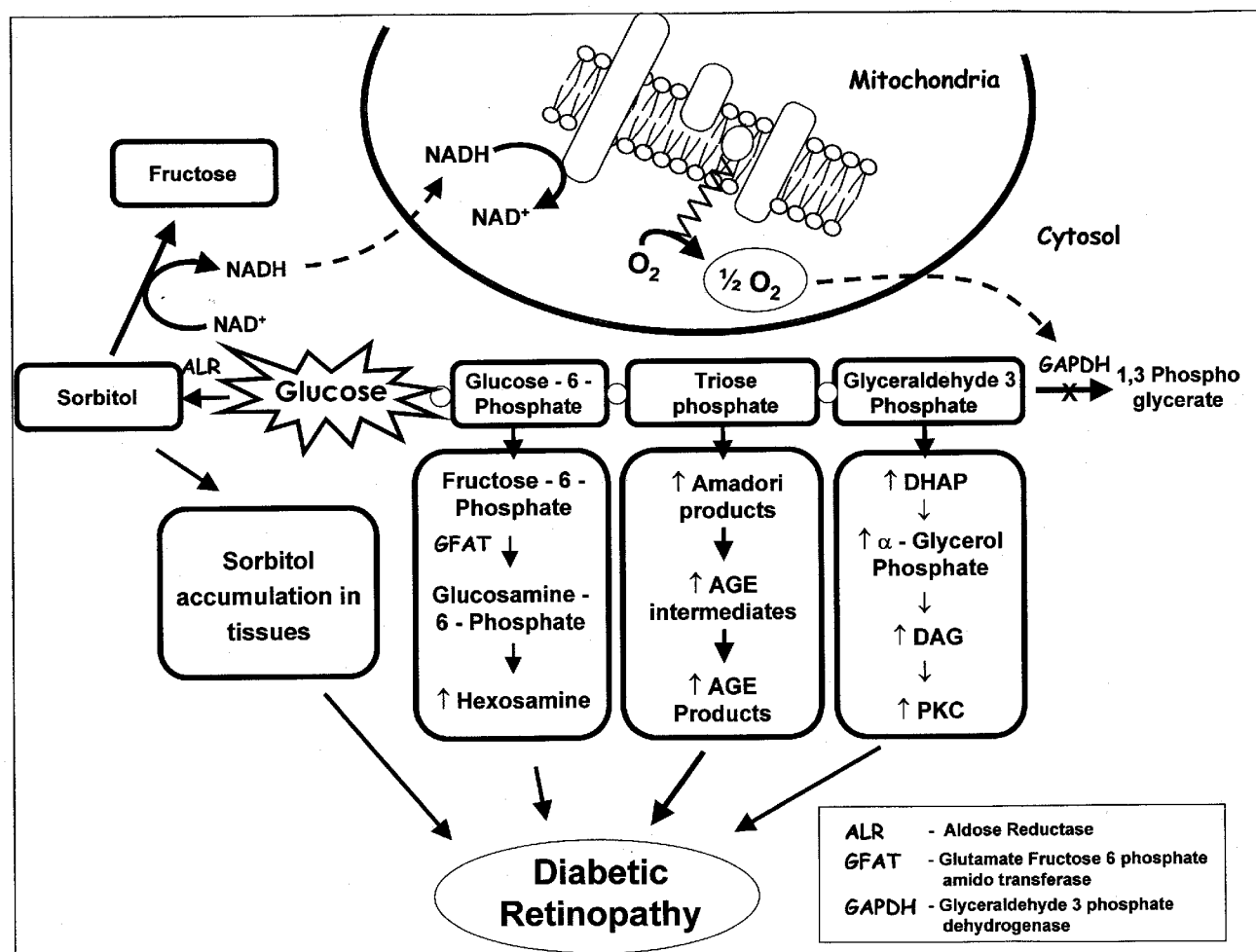
Multiple biochemical pathways have been proposed to explain the pathogenesis of diabetic retinopathy all starting initially from hyperglycaemia (Figure 1). These mainly include increased polyol pathway; increased advanced glycation end-products (AGE) formation; activation of protein kinase C (PKC) and increased hexosamine pathway flux.

### Increased polyol pathway

The polyol pathway consists of two steps, the reduction of glucose to sorbitol by aldose reductase and NADPH, followed by oxidation of sorbitol to fructose by sorbitol dehydrogenase and NAD<sup>+</sup> (Figure 1). Under normal conditions, glucose is channelled preferentially into the glycolytic pathway catalysed by hexokinase, which has a much higher affinity for glucose (low K<sub>m</sub>). During physiology, glucose hardly utilizes polyol pathway because of the low affinity of aldose reductase (high K<sub>m</sub>) for glucose. In tissues such as nerve, lens, retina and kidney, which do not require insulin for the intracellular transport of glucose, aldose reductase activity has been shown to be increased in an hyperglycaemic environment<sup>10,11</sup> with concomitant sorbitol accumulation in tissues. The potential detrimental effects of this include sorbitol-induced osmotic stress, decreased Na<sup>+</sup>/K<sup>+</sup> ATPase activity, an increase in cytosolic NADH/NAD<sup>+</sup> and a decrease in cytosolic NADPH, as well as activation of PKC, decreased glutathione and depletion of other antioxidant defences. These metabolic changes culminate in tissue damage and defined structural changes in the retinal vasculature<sup>12</sup>. It is important to mention that the flux through polyol pathway during hyperglycaemia varies from 33% of total glucose use in the rabbit lens to 11% in human erythrocytes. Therefore, the contribution of polyol pathway to diabetic complications may be very much species, site and tissue-dependent<sup>13</sup>. Although animal data convincingly shows that aldose reductase plays an early role in the pathogenesis of diabetic retinopathy, studies of inhibition of the polyol pathway *in vivo* have yielded inconsistent results. The long-term Sorbinil Trial<sup>14</sup> also indicated that sorbinil (an inhibitor of aldose reductase) did not prevent the worsening of the disease except for a slower progression rate in the number of microaneurysms. However, the positive effect of aldose reductase inhibition on diabetic neuropathy with zenarostat<sup>15</sup> provides vested hopes in the use of these compounds in diabetic retinopathy<sup>16</sup> which needs to be tested and validated by future studies.

### Increased AGE formation

Increased formation of advanced glycation end products (AGEs) correlate with poor glycaemic control and these reactive adducts form on DNA, lipids and proteins representing pathophysiological modifications that precipitate dysfunction at a cellular and molecular level. Glucose-derived AGE formation readily explains the development of diabetic complications in kidney, nerve, retina and vasculature – tissues in which glucose transport is relatively independent of insulin, but which are rich in long-lived proteins, such as collagen, elastin and myelin. Originally AGEs were thought to arise from non-



**Figure 1.** Hyperglycemia-driven biochemical alterations precipitated by mitochondria-driven oxidative stress leading to diabetic complications (Modified from Brownlee, 2002).

enzymatic reactions between extracellular proteins and glucose. But, the rate of AGE formation from glucose is orders of magnitude slower than the rate of AGE formation from glucose-derived dicarbonyl precursors generated intracellularly, and it is now recognized that intracellular hyperglycaemia is the primary initiating event in the formation of both intracellular and extracellular AGEs<sup>17</sup>. AGEs can arise from intracellular auto-oxidation of glucose to glyoxal, decomposition of the Amadori product (glucose-derived 1-amino-1-deoxy-fructose lysine adducts) to 3-deoxyglucosone and fragmentation of glyceraldehyde-3-phosphate and dihydroxyacetone phosphate to methylglyoxal (Figure 1). These reactive intracellular dicarbonyls (glyoxal, methylglyoxal and 3-deoxyglucosone) react with amino groups of intracellular and extracellular proteins to form AGEs (pyrrolidine, pentosidine, CML, crossline, etc).

In clinical diabetes, the incidence of chronic complications (including retinopathy) was logistically linked to the metabolism of methylglyoxal by the glyoxalase sys-

tem<sup>18</sup>. High levels of AGEs in diabetic patients implicate a deficient glyoxalase detoxification of reactive carbonyls<sup>19</sup> but there is paucity of studies on this subject in retinal tissues. The potential importance of AGEs in the pathogenesis of diabetic complications is indicated by the observation in animal models that two structurally unrelated AGE inhibitors (aminoguanidine and OPB 9195) partially prevented various functional and structural manifestations of diabetic microvascular disease in retina, kidney and nerve<sup>20-22</sup>. Pyridoxine, an inhibitor of formation of advanced glycation end products and lipoxidation end products, has been shown to protect against many retinal vascular lesions in experimental diabetes<sup>23</sup>. Studies using animal models and preliminary clinical trials have also shown the ability of the AGE-inhibitor, pimgedine and the cross-link breaker, ALT 711, to reduce the severity of pathologies of advanced glycation<sup>24</sup>. As more therapeutic agents are developed to inhibit AGE formation or limit their pathogenic influence during chronic diabetes, it is becoming clear that these

anti-AGE strategies have an important role to play in the treatment of diabetic complications with special reference to retinopathy.

### Hexosamine pathway

Recent *in vitro* and *in vivo* studies suggested that the increased flux of glucose through the hexosamine pathway may contribute to insulin resistance, diabetic vascular complications and to the induction of the synthesis of growth factors<sup>25,26</sup>. During normal physiology, only ~3% glucose is channeled into the hexosamine pathway. The rate-limiting enzyme in this pathway is glutamine: fructose-6-phosphate amidotransferase (GFAT), which catalyses the conversion of fructose-6-phosphate to glucoseamine-6-phosphate (Figure 1). The latter is rapidly metabolized to UDP-*N*-acetyl-glucosamine and is, along with other hexosamines, used as essential substrates for the synthesis of glycoproteins, proteoglycans, gangliosides and glycolipids. During hyperglycaemia, increased glucose flux follows hexosamine pathway and results in raised glucosamines that may cause insulin resistance in skeletal muscle and adipocytes.

In clinical diabetes, the increased GFAT activity in Type 2 diabetes has been well correlated with HbA1c levels<sup>27</sup> and higher levels and distinct regulation of GFAT expression were demonstrated in diabetic nephropathy<sup>26</sup>. Despite the documentation that GFAT is expressed in most tissues involved in the development of diabetic late complications<sup>25</sup>, there is no data on GFAT in eye-specific tissues. However, a recent study<sup>28</sup> suggests that the excessive glucose flux through the hexosamine pathway may direct retinal neurons to undergo apoptosis in a bimodal fashion, i.e. via perturbation of the neuroprotective effect of insulin mediated by Akt and via induction of apoptosis possibly by altered glycosylation of proteins. This report emphasizes that hexosamine pathway may be involved in retinal neurodegeneration in diabetes.

### Increased PKC activation

The protein kinase C (PKC) family is a large group of structurally related enzymes that require for their activation, phosphatidylserine/diacylglycerol (DAG)/free fatty acids and/or Ca<sup>2+</sup> ions in addition to Mg<sup>2+</sup>. Because of their involvement in multiple cellular functions, they are also referred to as 'microchips' in the cell signaling machinery<sup>29</sup>. Out of twelve PKC isoforms so far identified, nine are activated by the lipid second messenger DAG, and this implies that altered DAG-PKC pathway may have an important role in diabetic complications. The  $\beta$  isoform of PKC has been identified to be specific to the retinal complications. It appears that increased *de novo* DAG synthesis arises from the altered glycolysis

wherein (a) glyceraldehyde-3-phosphate dehydrogenase is inhibited and (b) there is acceleration in the reduction of dihydroxyacetone phosphate to  $\alpha$ -glycerol-3-phosphate. Increased formation of  $\alpha$ -glycerol-3-phosphate serves as a readily available precursor of DAG that stimulates PKC (Figure 1). Increased *de novo* synthesis of DAG was reported to activate PKC (predominantly PKC- $\beta$ ) both in cultured vascular cells<sup>30</sup> and in retina and glomeruli of diabetic animals<sup>31</sup>. Hyperglycaemia may also activate PKC isoforms indirectly through both ligation of AGE receptors and increased activity of the polyol pathway. Activation of PKC- $\beta$  isoforms has been shown to mediate retinal and renal blood flow abnormalities in experimental diabetes<sup>32</sup> and this led to the development of specific inhibitors of PKC- $\beta$  isoforms. An investigational compound known as LY333531, a protein kinase C- $\beta$  inhibitor is presently in Phase III clinical trials for severe preproliferative diabetic retinopathy and for diabetic macular edema. In experimental diabetes, these inhibitors prevented the slowing of retinal blood flow, induced regression of retinal neovascularization that is produced by laser-induced major branch vein occlusions<sup>33</sup> and inhibited vascular leakage induced by VEGF<sup>34</sup>. Preclinical and initial clinical studies evaluating LY333531 are thus far promising, as it did ameliorate diabetes-associated abnormalities in retinal vascular function. Patient identification for PKC- $\beta$  inhibitor therapy, cost effectiveness, toxicity if any, are some of the issues that await results of the currently undergoing clinical trials.

### Cross-talking of molecular signals

Although hyperglycaemia and haemodynamic changes are initiating factors in diabetic retinopathy, there is increasing evidence that many other pathways are involved in the early stages of diabetic retinopathy. These pathways involve intracellular signalling changes involving the cytoplasm and the nucleus. It appears that there is significant interaction between components of the four main pathways and a variety of intracellular signalling molecules (Figure 2). In the following paragraphs, we have attempted to review the classical interplay of a variety of molecular signals which initially originate from hyperglycemia but induce persistent biochemical and molecular abnormalities mostly occurring through the genesis of AGEs and/or oxidative stress and finally resorting the retinal cells to neovascularization.

There is a general consensus that the full spectrum of retinal microangiopathy due to diabetes arises from a continuum, and that one stage of the disease is likely to lead to the next and more advanced stage leading to increasingly greater risks for blindness. Although the 'no retinopathy' stage signifies that the retina appears clinically normal by standard fundus examination, early

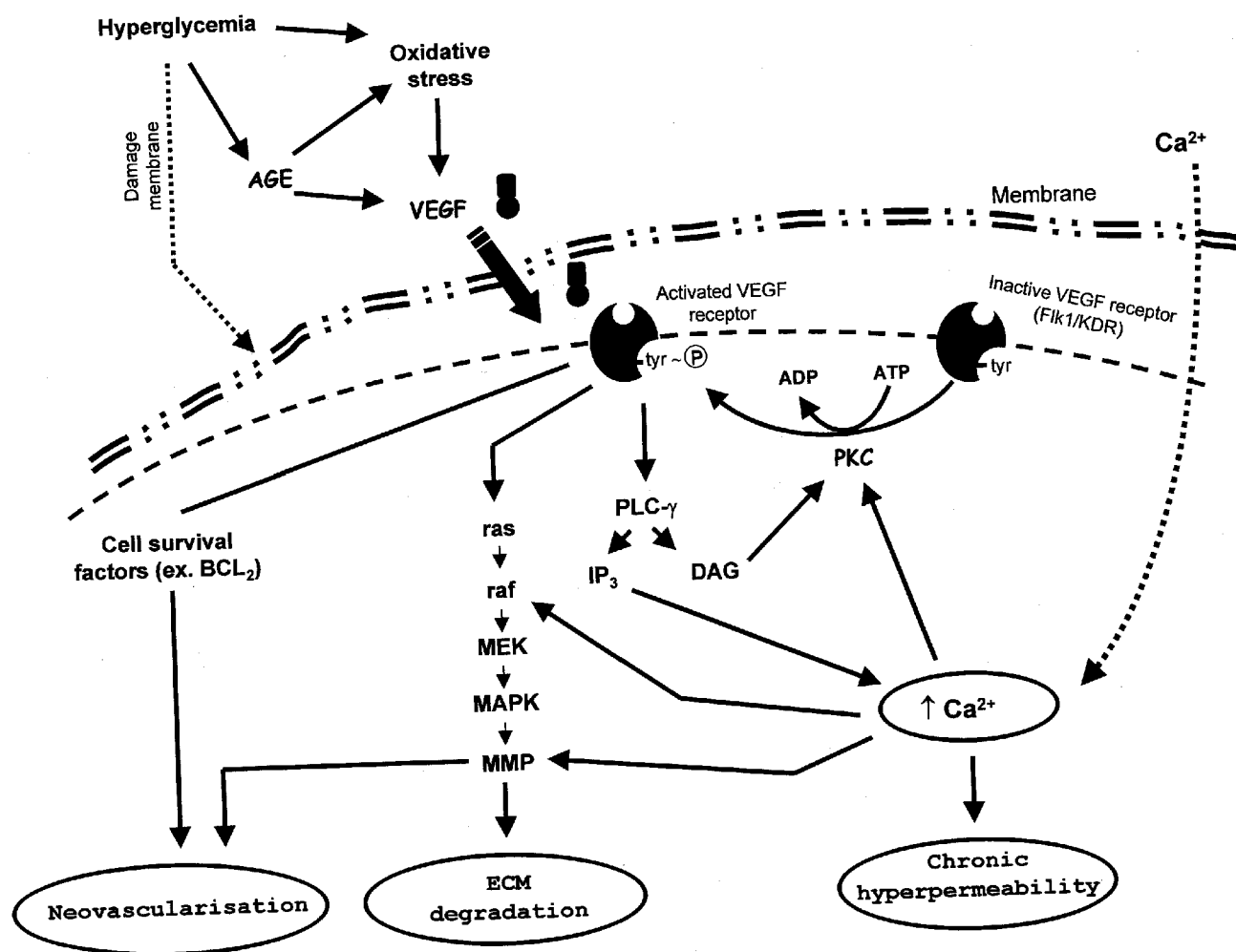


Figure 2. VEGF-driven neovascularization and retinal damage are co-ordinated by cross-talking of upstream and downstream molecular signals.

alterations in haemodynamic parameters and early histopathological changes are considered to be masked events at this stage. Thus, some of the earliest histopathological lesions like capillary dilatation, alteration in hyaloid membrane barrier, diffuse thickening of basement membrane and selective loss of pericytes<sup>35</sup>, go undetected by routine fundus examination. While a 1:1 ratio of endothelial cells to pericytes has been reported in normal humans, this ratio becomes 4:1 in diabetes<sup>36</sup>. The underlying mechanism determining why some pericytes degenerate while others persist, still remains an enigma. However, the pericyte is believed to play a central role in the development of diabetic microangiopathy<sup>37</sup>. Proliferative retinopathy invariably developed in mice when pericyte density was <50% of normal<sup>38</sup>. It has been hypothesized that the loss of pericytes provides a 'permissive' environment for the subsequent proliferation of endothelial cells, giving rise to the characteristic and unique vasculopathy (neovascularization) seen in diabetic retinopathy. This suggests that prevention of

the early stages of retinopathy, such as pericyte loss, may prevent the subsequent late stages of neovascularization.

The underlying mechanisms responsible for pericyte loss are very complex and not completely elucidated. A role for AGEs involving the two other signals, diacylglycerol/ceramide production and oxidative stress induction has been implicated in the apoptosis of bovine retinal pericytes in culture<sup>39</sup>. Recently<sup>40</sup> it has been demonstrated that a proapoptotic program triggered by NF $\kappa$ B selectively in retinal pericytes in response to hyperglycemia, is a possible mechanism for the early demise of pericytes in diabetic retinopathy. Using pericyte-endothelial cell co-culture systems<sup>41</sup>, it has been shown that pericytes not only regulate the growth but also preserve the prostacyclin-producing ability and protect against lipid peroxide-induced injury of endothelial cells. This has provided a basis for understanding how diabetic retinopathy develops consequent to pericyte loss. The same group has found that advanced glycation end prod-

ucts (AGE) exert a growth inhibitory effect and a cell type-specific immediate toxicity on pericytes through interactions with their receptor for AGE (RAGE). This is reported to lead to pericyte dropout, which by facilitating endothelial cell replication can promote angiogenesis. Indeed it has also been demonstrated that AGE exerts angiogenic activities directly on microvascular endothelial cells and that autocrine vascular endothelial growth factor (VEGF) is the major mediator of the AGE-driven angiogenesis<sup>42</sup>.

A role for pigment-epithelium-derived factor (PEDF) has also been emphasized recently as a protective mechanism against AGE-induced injury in retinal pericytes<sup>43,44</sup>. The following experiments supports this: (a) Ligand blot analysis revealed that pericytes possessed a membrane protein with binding affinity for PEDF and (b) PEDF proteins were found to significantly inhibit both AGE-induced reactive oxygen species (ROS) generation and the subsequent decrease in DNA synthesis and apoptotic cell death in pericytes. At present, it is not clear whether the substitution of PEDF proteins may serve as a promising strategy in treatment of patients with early diabetic retinopathy.

Several experiments suggest that VEGF is one of the important molecular signals directly implicated in the retinal neovascularization processes. VEGF is a potent angiogenic factor capable of stimulating endothelial cells to degrade extracellular matrix, migrate, proliferate and form tubes<sup>45</sup>. VEGF exerts its functions on endothelial cells via interaction with cellular receptors Flt-1 (VEGFR-1) and Flk-1/KDR (VEGFR-2), both receptor tyrosine kinases. It appears that activation of Flt-1 receptor regulates the metabolism of a range of vascular and non-vascular cells while KDR which is relatively specific for vascular endothelial cells promotes migration and proliferation. Increased levels of VEGF have been identified in the vitreous and the retina of patients with diabetes<sup>45-47</sup> and reported to have tight interactions with oxidative stress in the ischemic retina. VEGF also appears to play an early role in the development of diabetic retinopathy, as its original name was 'vascular permeability factor'. These observations have theoretic appeal in that the potential benefits of modulating the angiogenic response within the eye are obviously tremendous with the use of antiangiogenic agents such as VEGF inhibitors. However, studies have shown that inhibition of VEGF activity by specific antisense oligonucleotides<sup>48</sup>, VEGF neutralizing antibodies<sup>49</sup> or soluble receptors<sup>50</sup> was insufficient to completely prevent neovascularization. Nevertheless, continued evaluation of VEGF inhibitors for ocular neovascular disorders is warranted since a recent case study reported rapid and durable recovery of visual function with use of VEGF receptor inhibitor, SU5416 (ref. 51). Apart from VEGF, a plethora of other angiogenic factors including insulin-like growth factor-1 (IGF-1), basic fibroblast growth factors

(bFGF or FGF2), platelet-derived growth factor (PDGF), hepatocyte growth factor/scatter factor (HGF/SF), placenta growth factor (PIGF) and angiopoietin2 (Ang2) have been implicated in retinal vascularization.

The retina is high in polyunsaturated fatty acids and has the highest glucose oxidation and oxygen uptake of any tissue, thus making retina potentially extremely susceptible to increased oxidative stress<sup>52</sup>. Increased oxidative stress can modify interactions between circulating blood cells and retinal capillary endothelial cells, thereby disturbing the complex cellular organization in which retinal microvessels are embedded<sup>53</sup>. Impaired activities of antioxidant defence enzymes such as superoxide dismutase (SOD) appear to be one of the possible sources of oxidative stress in diabetes<sup>54,55</sup>. Recent evidence also implicates Reactive Oxygen Species (ROS) in the mitogenic cascade initiated by the tyrosine kinase receptors of several growth factor peptides including VEGF<sup>56</sup>. This is again supported by the demonstration that regulation of VEGF expression by advanced glycation end products occurs through the activation of hypoxia inducible factor-1 (HIF-1) which could play an important role in the development of diabetic retinopathy<sup>57</sup>.

Observations in the EURODIAB Complications Study demonstrated that one of the markers of insulin resistance, high triglyceride level is a risk factor for retinopathy in patients with diabetes<sup>58</sup>. As an explanation to the molecular mechanism underlying this work, it is demonstrated that palmitate, a major saturated free fatty acid in plasma, when applied *in vitro* induced apoptotic cell death in microvascular endothelial cells and pericytes through increased generation of intracellular ROS. Other reports also implicate the role of phospholipase C, protein kinase C and calcium in the down-stream VEGF-induced vascular permeability and neovascularization<sup>59</sup>. The role of VEGF, as an important mediator of increased vascular permeability, acting via a PKC-dependent mechanism is now firmly established<sup>60</sup>. Awata *et al.*<sup>61</sup> have recently demonstrated a common polymorphism of the VEGF to have an association with diabetic retinopathy in Type 2 diabetes. In addition, VEGF induction of vascular permeability may contribute to the development of non-proliferative diabetic retinopathy<sup>47</sup>. The observation of increased retinal VEGF expression early in diabetic retinopathy<sup>62,63</sup> and the finding in non-diabetic animals that exogenous intraocular VEGF administration can elicit retinal abnormalities resembling diabetic retinopathy<sup>64</sup> suggest that VEGF may also play a role in the development of the earliest stages of retinopathy. A recent study<sup>65</sup> also demonstrated that the concentrations of both VEGF and endostatin in vitreous fluid are correlated with angiogenesis in DR. This study suggests that the regulatory mechanism between VEGF and endostatin is associated with the activity of DR and this may be a good target to develop useful therapeutic agents for proliferative DR. Further studies are needed to see whether

early induction of VEGF has an association with pericyte loss, which is the hallmark of early diabetic microangiopathy.

### Role of cytokines

Preretinal proliferative membrane formation, which is regulated by various cytokines, is a very important step in the pathogenesis of proliferative diabetic retinopathy<sup>66,67</sup>. In addition to vascular endothelial growth factor, transforming growth factor 2 (TGF-2) has been shown to play a key role in preretinal membrane formation caused by retinal metabolic abnormalities<sup>68</sup>. Contraction of neovascular and proliferative membranes is closely associated with cytokine expression by retinal cells, particularly Muller cells. Inflammatory cytokines like interleukin-6 (IL-6), interleukin-8 (IL-8) and tumour necrosis factor- $\alpha$  (TNF- $\alpha$ ) have also been studied in the vitreous and serum samples of patients with proliferative diabetic retinopathy<sup>69</sup>. IL-6 and IL-8 were higher in the vitreous of patients with PDR and TNF- $\alpha$  was elevated in the serum of PDR patients compared to the patients with non-inflammatory retinopathy. These cytokines form a network and it remains to be resolved to determine the contribution of each component. Ultrastructural studies of blood retinal barrier (BRB) after exposure to IL-1 $\beta$  or TNF- $\alpha$  show pro-inflammatory effects in experimental animals. The causative factors leading to BRB breakdown are not entirely understood although cytokines have been implicated in the development of diabetic retinopathy. Regulation and inhibition of cytokines may have a potential use to prevent intraocular proliferative diseases.

### Hyperglycemic memory and DR

The relationship between hyperglycemia and the development of long-term diabetic complications has now become firmly established. Classic observational studies by Pirart *et al.*<sup>70</sup> described the relationship between increased glycosuria and the ultimate development of diabetic retinopathy, nephropathy, and neuropathy. Nonetheless, it required the findings of randomized, controlled clinical trials to finally and definitively establish the relationship between glucose control and microvascular diabetic complications. With the publication of the Diabetes Control and Complications Trial, the Kumamoto Trial, and the United Kingdom Prospective Diabetes Study, the impact of glycemic control in the prevention of microvascular complications was finally established. However, these studies also unmasked certain paradoxical situations, which warrant still more understanding with respect to the pathophysiology of diabetic complications. One such paradox is termed as 'hyperglycemic memory'. This refers to the persistence of progression of

hyperglycemia-induced microvascular alterations during subsequent periods of normal glucose homeostasis. This striking phenomenon occurred in the eyes of diabetic dogs during a post-hyperglycemic period of euglycaemia<sup>71</sup>. The eyes were histologically normal for 2.5 years on exposure to sustained and elevated glucose. But after a subsequent 2.5-year period of normal glycaemia, the eyes developed severe retinopathy. The worsening retinopathy despite sustained recovery to normoglycemia, has also been reported in streptozotocin-induced diabetic rats implying that good glucose control alone does not stop the progression of the retinal microangiopathy at its late stage<sup>72</sup>.

Results from the Epidemiology of Diabetes Interventions and Complications study indicate that hyperglycaemic memory also occurs in human patients. The effects of intensive and conventional therapy on the occurrence and severity of post-study retinopathy and nephropathy were shown to persist for four years after the Diabetes Control and Complications Trial (DCCT), despite nearly identical glycosylated haemoglobin values during the 4-year follow-up<sup>73</sup>. Interestingly, achievement of normoglycemia by pancreatic transplantation is also not effective in halting the progression of diabetic retinopathy in patients<sup>74</sup>. Other studies support that previous glycemic exposure (HbA1c) and glycemic level at the first visit also influenced the development of DR<sup>75</sup>. The lesson from these studies is that achieving the best glycemic control from the onset of diabetes appears to be of outstanding importance as the HbA1c levels already during the first year of diabetes are related to the later development of background retinopathy<sup>76</sup>. Long-term diabetes control, therefore, can no longer be viewed exclusively as glucose management. Rather, a more holistic approach is necessary to minimize risks of both microvascular and macrovascular complications. As suggested by Brownlee *et al.*<sup>13</sup>, hyperglycaemia-induced mitochondrial superoxide production (oxidative stress) may provide an explanation for the development of complications during post-hyperglycaemic periods of normal glycaemia. Counteracting biochemical derangements arising from oxidative stress, with the conventional antioxidants might be difficult to accomplish as these scavenge reactive oxygen species in a stoichiometric manner. In this context, there is much hope in new, low-molecular-mass compounds that act as SOD or catalase mimetics and scavenge reactive oxygen species continuously by acting as catalysts with efficiencies approaching those of the native enzymes<sup>77</sup>. Such drugs are expected to offer novel ways of preventing the development and progression of diabetic complications.

### Future perspectives

Diabetic retinopathy is a preventable cause of visual loss in adults of all ages. As the diabetes incidence is increas-

ing with lifestyle changes and advancing human longevity, diabetic retinopathy is truly a major challenge for the new millennium. Although the pathogenesis of the disease is extremely complex, this complexity also provides a plethora of possible mechanistic targets for therapeutic intervention. Preclinical animal data for the emerging therapies that target the early (non-proliferative) or late (proliferative) stages of the disease are very promising. Since the clinical manifestations of retinopathy require several years to develop, the evaluation of therapies is slow. At present, the clinical outcome end-points that are typically evaluated by the ETDRS scale predicate clinical trials of 3–5 years duration. One possible way to shorten the length of the trial, as suggested by FDA, is to establish new surrogate end-points of clinical and prognostic significance. There is much scope for these in the on-going preclinical research. To support anti-angiogenic compounds as a powerful therapeutic modality, we still need to learn more about the complex mechanisms governing the neovascularization of the retina. A limiting factor in the treatment of diabetic retinopathy is that high blood levels of systemically administered drugs are required to achieve a therapeutic effect in the eye. Secondly, certain disease-correcting processes in diabetics may need angiogenesis. For example, there may be side-effects from administering a systemic anti-angiogenic agent to patients with diabetes who are at risk of developing atherosclerotic vessels of the myocardium, where they may actually require the growth of collateral microvessels to compensate for the myocardial ischemia. Similarly, they may need angiogenesis to overcome peripheral ischaemia and wound healing especially in the diabetic foot. Additionally, some VEGF antagonists such as VEGF receptor chimeric protein and the VEGF neutralizing antibodies are large molecules with poor diffusion into tissues. Repetitive invasive procedures such as intravitreal injection also seem to be impractical due to potential complications of retinal detachment, bleeding and infection. Therefore, an ideal therapy for the treatment of diabetic retinopathy will be an anti-angiogenic agent that is specific for the aberrant retinal vasculature. This should be possible only by (a) using a retinal vessel-specific targeting molecule and (b) establishment and implementation of a novel ophthalmic drug delivery mechanism. Recent progress on transscleral delivery of bioactive proteins and DNAs to the choroid and retina provides promising future regarding the local delivery of therapeutic agents. Hopefully in the future, therapies may also become possible to appropriately programme the bone-marrow-derived hematopoietic stem cells to counteract new vessel formation in the retina. Hope for this has recently come from a study which showed that retinal neovascularization results not only from stimulation of resident endothelial cells through an angiogenic process, but also relies on recruitment of undifferentiated precursor cells that aid in functional vessel regeneration<sup>78</sup>.

1. Rema, M., Shanthi Rani, C. S., Deepa, R. and Mohan, V., *Diab. Res. Clin. Pract.*, 2000, 1460.
2. Rema, M., Ponnaiya, M. and Mohan, V., *ibid*, 1996, **34**, 29–36.
3. Rema, M., Deepa, R. and Mohan, V., *Br. J. Ophthalmol.*, 2000, **84**, 1058–1060.
4. Rema, M., Saravanan, G., Deepa, R. and Mohan, V., *Diab. Med.*, 2002, **19**, 910–916.
5. Gardner, T. W. and Aiello, P., *Am. Acad. Ophthalmol. Monogr.*, 2000, **14**, 1–18.
6. Kristinsson, J. K., Gottfredsdottir, M. S. and Stefansson, E., *Br. J. Ophthalmol.*, 1997, **81**, 274–278.
7. Engerman, R. L. and Kern, T. S., *Diab. Metab. Rev.*, 1995, **11**, 109–120.
8. Wetzig, P. C. and Jepson, C. N., *Am. J. Ophthalmol.*, 1966, **62**, 459–464.
9. Stefansson, E., *Graefes Arch. Clin. Exp. Ophthalmol.*, 1990, **228**, 120–123.
10. Nishimura, C., Saito, T., Ito, T., Omori, Y. and Tanimoto, T., *Diabetologia*, 1994, **37**, 328–330.
11. Das, A., Shah, V. O., Dorin, R. I. and Zager, P. G., *Invest. Ophthalmol. Vis. Sci.*, 1996, **3**, S105.
12. Robison, G. W., Laver, N. M., Jacot, J. L. and Glover, J. P., *ibid*, 1995, **26**, 2368–2380.
13. Brownlee, M., *Nature*, 2002, **414**, 813–820.
14. Sorbinil Retinopathy Trial Research Group, *Arch. Ophthalmol.*, 1990, **108**, 1234–1244.
15. Greene, D. A., Arezzo, J. C. and Brown, M. B., *Neurology*, 1999, **53**, 580–591.
16. Fujishima, H. and Tsubota, K., *Br. J. Ophthalmol.*, 2002, **86**, 860–863.
17. Degenhardt, T. P., Thorpe, S. R. and Baynes, J. W., *Cell Mol. Biol.*, 1998, **44**, 1139–1145.
18. McLellan, A. C., Thornalley, P. J., Benn, J. and Sonksen, P. H., *Clin. Sci.*, 1994, **87**, 21–29.
19. Miyata, T. *et al.*, *Kidney Int.*, 2001, **60**, 2351–2359.
20. Nakamura, S. *et al.*, *Diabetes*, 1997, **46**, 895–899.
21. Hammes, H., Martin, S., Federlin, K., Geisen, K. and Brownlee, M., *Proc. Natl. Acad. Sci. USA*, 1991, **88**, 11555–11558.
22. Du, Y., Smith, M. A., Miller, C. M. and Kern, T. S., *J. Neurochem.*, 2002, **80**, 771–779.
23. Stitt, A. *et al.*, *Diabetes*, 2002, **51**, 2826–2832.
24. Vasan, S., Foiles, P. G. and Founds, H. W., *Expert. Opin. Investig. Drugs*, 2001, **10**, 1977–1987.
25. Nerlich, A. G., Sauer, U., Kolm-Litty, V., Wagner, E., Koch, M., and Schleicher, E. D., *Diabetes*, 1998, **47**, 170–178.
26. Schleicher, E. D. and Weigert, C., *Kidney Int.*, 2000, **88**, S12–S18.
27. Yki-Jarvinen, H., Daniels, M. C., Virkamai, A., Makimattila, S., DeFranzo, R. A. and McClain, D., *Diabetes*, 1996, **45**, 302–307.
28. Nakamura, M., Barber, A. J., Antonetti, D. A., LaNoue, K. F., Robison, K. A., Buse, M. G. and Gardner, T. W., *J. Biol. Chem.*, 2001, **276**, 43748–43755.
29. Balasubramanyam, M. and Mohan, V., *Indian Heart J.*, 2000, **52**, 226–232.
30. Xia, P., Inoguchi, T., Kern, T. S., Engerman, R. L., Oates, P. J. and King, G. L., *Diabetes*, 1994, **43**, 1122–1129.
31. Koya, D. and King, G. L., *ibid*, 1998, **47**, 859–866.
32. Ishi, H. *et al.*, *Science*, 1996, **272**, 728–731.
33. Danis, R. P., Bingaman, D. P. and Jrousek Yang, Y., *Invest. Ophthalmol. Vis. Sci.*, 1998, **39**, 171–179.
34. Aiello, L. P. *et al.*, *Diabetes*, 1997, **46**, 1473–1480.
35. Addison, D. J., Garner, A. and Ashton, N., *Br. Med. J.*, 1970, **1**, 264–266.
36. Robison, W. G. Jr, Kador, P. F. and Kinoshita, J. H., *Diab. Med.*, 1985, **2**, 196–199.
37. Patz, A., *Am. J. Ophthalmol.*, 1982, **94**, 715–743.



38. Enge, M. *et al.*, *EMBO J.*, 2002, **21**, 4307–4316.
39. Denis, U., Lecomte, M., Paget, C., Ruggiero, D., Wiernsperger, N. and Lagarde, M., *Free Radic. Biol. Med.*, 2002, **33**, 236–247.
40. Romeo, G., Liu, W. H., Asnaghi, V., Kern, T. S. and Lorenzi, M., *Diabetes*, 2002, **51**, 2241–2248.
41. Yamagishi, S., Hsu, C. C., Kobayashi, K. and Yamamoto, H., *Biochem. Biophys. Res. Commun.*, 1993, **191**, 840–846.
42. Yamagishi, S. *et al.*, *J. Biol. Chem.*, 1997, **272**, 8723–8730.
43. Yamagishi, S., Inagaki, Y., Amano, S., Okamoto, T., Takeuchi, M. and Makita, Z., *Biochem. Biophys. Res. Commun.*, 2002, **296**, 877.
44. Ogata, N., Nishikawa, M., Nishimura, T., Mitsuma, Y. and Matsumura, M., *Am. J. Ophthalmol.*, 2002, **134**, 348–353.
45. Williams, B., *Vasc. Med.*, 1996, **1**, 251–258.
46. Adamis, A. P., Miller, J. W., Bernal, M. T., D'Amico, D. J., Folkman, J., Yeo, T. K. and Yeo, K. T., *Am. J. Ophthalmol.*, 1994, **118**, 445–450.
47. Boulton, M., Foreman, D., Williams, G. and McLeod, D., *Br. J. Ophthalmol.*, 1998, **82**, 561–568.
48. Robinson, G. S., Pierce, E. A., Rook, S. L., Foley, E., Webb, R. and Smith, E., *Proc. Natl. Acad. Sci. USA*, 1996, **93**, 4851–4856.
49. Adamis, A. P. *et al.*, *Arch Ophthalmol.*, 1995, **114**, 66–71.
50. Aiello, L. P. *et al.*, *Proc. Natl. Acad. Sci. USA*, 1995, **92**, 10457–10461.
51. Aiello, L. P., George, D. J., Cahill, M. T., Wong, J. S., Cavallerano, J., Hannah, A. L. and Kaelin, W. G. Jr, *Ophthalmology*, 2002, **109**, 1745–1751.
52. Anderson, R. E., Rapp, M. and Wiegand, R. D., *Curr. Eye Res.*, 1984, **3**, 223–227.
53. Ruggiero, D., Lecomte, M., Michoud, E. and Lagarde, M., *Diab. Metab.*, 1997, **23**, 30–42.
54. Parthiban, A., Vijayalingam, S., Shanmugasundaram, K. R. and Rema, M., *Cell Biol. Int.*, 1995, **19**, 987–993.
55. Kowluru, R. A. and Kennedy, A., *Expert. Opin. Invest. Drugs*, 2000, **10**, 1665–1676.
56. Colavitti, R., Pani, G., Bedogni, B., Anzevino, R., Borrello, S., Waltenberger, J. and Galeotti, T., *J. Biol. Chem.*, 2002, **277**, 3101–3108.
57. Treins, C., Giorgetti-Peraldi, S., Murdaca, J. and Van Obberghen, E., *J. Biol. Chem.*, 2001, **276**, 43836–43841.
58. Chaturvedi, N., Sjoelie, A. K., Porta, M., Aldington, S. J., Fuller, J. H., Songini, M. and Kohner, E. M., *Diab. Care*, 2001, **24**, 284–289.
59. Wu, H. M., Yuan, Y., Zawieja, D. C., Tinsley, J. and Granger, H. J., *Am. J. Physiol.*, 1999, **276**, H535–H542.
60. Duh, E. and Aiello, L. P., *Diabetes*, 1999, **48**, 1899–1906.
61. Awata, T., Inoue, K., Kurihara, S. and Ohkubo, T., *ibid*, 2002, **51**, 1635–1639.
62. Amin, R. H., Frank, R. N., Kennedy, A., Elliott, D. and Puklin, J. E., *Invest. Ophthalmol. Vis. Sci.*, 1997, **38**, 36–47.
63. Tolentino, M. J., Miller, J. W., Gragoudas, E. S., Jakobiec, F. A., and Adamis, A. P., *Ophthalmology*, 1996, **103**, 1820–1828.
64. Aiello, L. P. *et al.*, *Diabetes*, 1997, **46**, 1473–1480.
65. Noma, H., Funatsu, H., Yamashita, H., Kitano, S., Mishima, H. K. and Hori, S., *Arch. Ophthalmol.*, 2002, **120**, 1075–1080.
66. Casey, R. and Li, W. W., *Am. J. Ophthalmol.*, 1997, **124**, 521–529.
67. Elner, S. G., Elner, V. M., Jaffe, G. J., Stuart, A., Kunkel, S. L. and Strieter, R. M., *Curr. Eye Res.*, 1995, **14**, 1045–1053.
68. Pena, R. A., Jerdan, J. A. and Glaser, G. M., *Invest. Ophthalmol. Vis. Sci.*, 1994, **35**, 2804–2808.
69. Takashi Yuuki, Tsugiyasu Kanda, Yasutaka Kimura, Nobuo Kotajima, Jun'ichi Tamura, Isao Kobayashi and Shoji Kishi, *J. Diab. Complic.*, 2001, **15**, 257–259.
70. Pirart, J., *Minerva Endocrinol.*, 1984, **9**, 55–58.
71. Engerman, R. I. and Kern, T. S., *Diabetes*, 1987, **36**, 808–812.
72. Su, E. N., Alder, V. A., Yu, D. Y., Yu, P. K., Cringle, S. J. and Yogesan, K., *Graefes Arch. Clin. Exp. Ophthalmol.*, 2000, **238**, 163–173.
73. The Diabetes Control and Complications Trial Research Group, *Diab. Care*, 2000, **23**, 1084–1091.
74. Petersen, M. R. and Vine, A. K., *Ophthalmology*, 1990, **97**, 496–500.
75. Zhang, L., Krzentowski, G., Albert, A. and Lefebvre, P. J., *Diab. Care*, 2001 **24**, 1275–1279.
76. Danne, T., Kordonouri, O., Enders, I., Hovener, G. and Weber, B., *Horm. Res.*, 1998, **50**, 28–32.
77. Salvemini, D., Riley, D. P. and Cuzzocrea, S., *Nat. Rev. Drug Discov.*, 2002, **1**, 367–374.
78. Grant, M. B. *et al.*, *Nat. Med.*, 2002, **8**, 606–612.