

## Ultrasonography for diagnosis of abdominal tuberculosis in HIV infected people

Dipti Agarwal, Shamrendra Narayan, Jaya Chakravarty & Shyam Sundar

*ART Center, Department of Medicine, Institute of Medical Science, Banaras Hindu University, Varanasi, India*

Received October 21, 2008

**Background & objectives:** There is an increasing incidence of abdominal tuberculosis with the advent of HIV infection. This study was aimed at determining the pattern of presentation of abdominal tuberculosis on ultrasonography (USG) in HIV positive patients.

**Methods:** This retrospective study was carried at the ART Centre, Sir Sunderlal Hospital, Banaras Hindu University, Varanasi, between March 2005 to July 2007. HIV positive patients (n=2453) with prolonged fever, abdominal pain/distension, altered bowel habits and diarrhoea underwent ultrasonography for tuberculosis of abdomen. The different ultrasonological findings in abdominal tuberculosis were noted. CD<sub>4</sub> counts of these patients were also recorded.

**Results:** Of the total 2453 patients, 244 showed findings suggestive of abdominal tuberculosis. Lymphadenopathy with predominantly hypoechoic/necrotic echotexture was seen in 158/244 (64.8%) patients. Splenomegaly was seen in 68 patients with 61 of them (89.7%) showing multiple hypoechoic lesions in the parenchyma. 53 of 244 (21.7%) showed extensive abdominal involvement. Liver enlargement was seen as a part of extensive abdominal involvement. A total of 203 patients completed antitubercular treatment, of which 198 (97.5%) showed resolution of lesions in USG. CD<sub>4</sub> counts in patients with extensive abdominal involvement were lowest compared to CD<sub>4</sub> count in patients with others USG findings.

**Interpretation & conclusion:** Ultrasonological findings like lymphadenopathy ( $\geq 1.5$  cm) with hypoechoic/necrotic echotexture, hypoechoic splenic lesions and extensive abdominal involvement in HIV infected patients may be suggestive of abdominal tuberculosis.

**Key words** Abdominal tuberculosis - HIV - ultrasonography

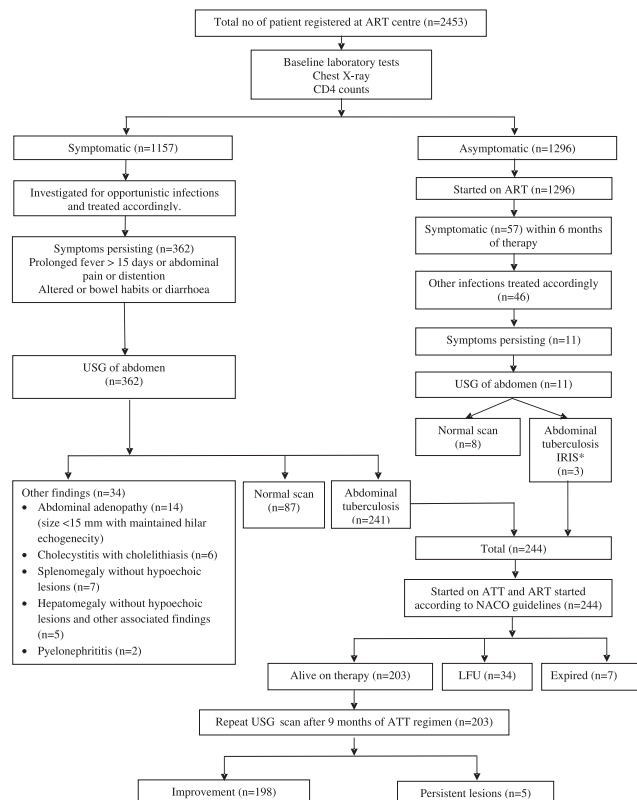
The prevalence of abdominal tuberculosis seems to be rising, particularly due to increasing prevalence of HIV infection<sup>1</sup>. The diagnosis of abdominal tuberculosis can often be difficult, in view of its protean manifestations and mimicry of other diseases. The clinical features of abdominal tuberculosis are vague. The investigations involved in its diagnosis are expensive and time consuming like CT scan of abdomen,

laparotomy and others. However, ultrasonography (USG) is an affordable, non invasive and widely available modality which can be of help in diagnosis of abdominal tuberculosis<sup>2</sup>. We undertook this study to determine the patterns of clinical presentation of abdominal tuberculosis on ultrasonography in patients positive for HIV and also to see its association with CD<sub>4</sub> counts.

## Material & Methods

This retrospective study was done at Antiretroviral Therapy (ART) Centre, Sir Sundarlal Hospital, Banaras Hindu University, Varanasi, Uttar Pradesh. It was approved by the Ethics committee of the Institute. A total of 2453 HIV infected patients aged >15 yr were registered for antiretroviral therapy at the ART Centre between March 2005 to July 2007. Detailed clinical examination with World Health Organization (WHO) staging<sup>3</sup>, routine biochemical tests, and chest X-ray were performed in all patients. Symptomatic patients were investigated for opportunistic infections and treated accordingly. Patients with persistent fever of more than 15 days with abdominal pain or distension, or altered bowel habit or diarrhoea which could not be attributed to any other cause underwent ultrasonography of abdomen (Fig.). The following features on USG were considered suggestive of abdominal tuberculosis as obtained from other studies in HIV patients<sup>4-6</sup>.

1. Enlarged lymph nodes predominantly hypoechoic/necrotic. Size of lymph nodes greater than 15 mm



\*Immune reconstitution syndrome  
LFU, lost to follow up

**Fig.** Deposition of subjects in a study of ultrasonography in abdominal tuberculosis in HIV patients.

was considered tubercular<sup>5</sup>. Hypoechoic nodes means that hilar echogenicity of the nodes are lost.

2. Visceral involvement may be seen as organomegaly or as multiple small abscesses/hypoechoic lesions in the organs.
3. Bowel wall thickening (especially in the ileo-cecal junction), peritoneal nodules, mesenteric thickening or ascites.
4. Presence of more than one of the above findings was considered as extensive abdominal involvement.

Clinical records of patients with these ultrasonographic findings suggestive of abdominal tuberculosis were reviewed. Apart from the details of the findings obtained on ultrasonography, demographic variables, clinical details, and CD<sub>4</sub> counts were recorded. Ascitic fluid cytology and USG guided fine needle aspiration of the lymph nodes were performed, where possible. All these patients were started on antitubercular therapy for a duration of 9 months comprising four drugs (rifampicin, isoniazid, pyrazinamide, and ethambutol) for 3 months and 3 drugs for 6 months.

Antiretroviral therapy was initiated 2 wk to 2 months after start of antitubercular therapy as per guidelines of the National AIDS Control Organization (NACO)<sup>7</sup>. Clinical responses were monitored monthly. Subsidence of presenting complaints of fever, abdominal pain, distension, altered bowel habits at the end of antitubercular regimen was considered as clinical improvement. Ultrasonography was repeated at the end of antitubercular therapy and compared with the prior findings to assess improvement. Resolution of adenopathy, hypoechoic lesions in spleen and liver, bowel wall thickening and ascites was considered as ultrasonographic improvement. CD<sub>4</sub> counts in patients with these ultrasonographic findings were recorded.

Data were analyzed using SPSS (version 16, USA). Frequencies of ultrasonography findings in abdominal tuberculosis were noted along with their CD<sub>4</sub> counts (mean ± SD). The USG findings were also categorized in non-overlapping groups and One way ANOVA was applied to see relation with CD<sub>4</sub> counts.

## Results

Out of 2453 patients 244 (9.9%) showed features suggestive of abdominal tuberculosis on ultrasonography. Of these, 21 (8.6%) had pulmonary tuberculosis. 196 (80.5%) were males and the mean

age was  $33.3 \pm 3.6$  yr. Fever was the most common symptom in 170 (70%) subjects followed by weight loss seen in 74 (30.3%). Diarrhoea was seen in 66 (27%) and altered bowel habits in 42 (17%) subjects. Abdominal pain and distension was seen in 56 (23%) and 17 (7%) patients respectively.

Enlarged lymph nodes (mean diameter  $22.5 \pm 6.45$  mm) was found in 158 (64.8%) of the patients. Mesentric and retroperitoneal lymphnodes were most commonly involved. Lymph nodes showed hypoechoic echotexture, with loss of central hilar echogenicity in 76 of 158 (48.1%) patients with lymphadenopathy. Twenty one (13.2%) showed necrosis. In 27 (17.08%) cases, multiple enlarged lymph nodes formed a large conglomerate mass. USG guided lymph node fine needle aspiration cytology was performed in 15 subjects revealed caseating granulomas.

Splenomegaly was found in 68 (27.86%) patients. Sixty one (89.7%) of these patients showed numerous hypoechoic lesions spread throughout the splenic parenchyma and 7 (20.30%) showed area of necrosis.

Extensive abdominal involvement was seen in 53 (21.7%). Hepatomegaly seen in 49 (20.08%) patients, was found only as a part of extensive abdominal involvement. Of these 49 patients, 27 (55.2%) showed hypoechoic lesions, there was no change in echogenicity in 13 (26.5%) and increased echogenicity was seen in 9 (18.3%) patients. Multiple hypoechoic lesions were seen in other viscera like kidney in 3 patients, adrenal gland, and urinary bladder in one patient each.

Small intestinal wall thickening was seen in 15 (6.1%) patients showing uniform thickening mostly in the ileocecal region. Mild to moderate ascites was found only in 7 (2.9%) subjects (Table). Ascitic fluid examination in these patients revealed an exudative fluid. Chest X-ray in patients with pulmonary tuberculosis showed military mottling in 14 patients; 4 patients had pleural effusion and in 3 bilateral pulmonary infiltrates were seen. Mean  $CD_4$  counts were  $88.2 \pm 36.4/\mu\text{l}$  in these patients with abdominal tuberculosis.

The non-overlapping USG findings in 244 patients and their respective  $CD_4$  counts showed lymphadenopathy in 147 (60.24%) with mean  $CD_4$  of  $98.8 \pm 54.0/\mu\text{l}$ , splenomegaly in 32 (13.11%) with mean  $CD_4$  of  $87.5 \pm 48.9/\mu\text{l}$ , bowel wall thickening in 7 (2.9%) with mean  $CD_4$  of  $94.6 \pm 88.6/\mu\text{l}$ , ascites in 5 (2.07%) with mean  $CD_4$  of  $96.8 \pm 51.4/\mu\text{l}$  and extensive

abdominal involvement in 53 (21.7%) with mean  $CD_4$  of  $75.7 \pm 62.7/\mu\text{l}$ . Patients with only lymphadenopathy had significantly higher ( $P < 0.05$ )  $CD_4$  counts as compared to those with extensive abdominal involvement.

Of the 244 patients, 34 were lost to follow up (not attended antiretroviral therapy for consecutive 3 months) and 7 expired. USG evaluation was done in the remaining 203 subjects at the end of 9 months of antitubercular regimen. Resolution of lesions was seen in 198 (97.5%) patients and 5 (2.5%) subjects showed residual changes (Fig.). Clinical improvement was observed in all the 203 patients.

### Discussion

Abdominal tuberculosis was seen to affect young males in this study which was similar to other studies<sup>8</sup>. Clinical symptoms were vague and resembled other studies<sup>9</sup>. Fever was the most common presenting clinical symptom suggesting that HIV infected patients with prolonged fever should be screened for abdominal tuberculosis.

Abdominal tuberculosis has varied findings on ultrasonography, involving the gastrointestinal tract, lymphnodes, peritoneum, and solid organs. Tuberculosis of the abdomen in non HIV patients most commonly affects the ileocaecal region of the bowel where it causes circumferential ulcers with multiple strictures and sometimes involves the draining lymph nodes<sup>10</sup>. Another common presentation is tubercular peritonitis with ascites<sup>8</sup>. However, bowel wall involvement and ascites were quite low in our subjects.

In this study, majority of the patients showed enlargement of abdominal lymph nodes, similar to other studies on abdominal tuberculosis in HIV patients<sup>5,11</sup>. Though HIV infection itself can lead to lymphadenopathy, however, size more than 15 mm and hypoechoic representing zones of caseation was suggestive of abdominal tuberculosis in our study. Size and characteristic of nodes can help differentiate between adenopathy caused by abdominal tuberculosis and HIV *per se*.

Splenic tuberculosis is a rare entity in immunocompetent patients with only sporadic cases reported in literature<sup>12,13</sup>. In our study splenomegaly with hypoechoic or necrotic lesions were seen in a large number of patients as observed in other studies on HIV infected patients<sup>5,14</sup>. Thus, presence of splenic abscess in a patient with abdominal tuberculosis carries a high suspicion of HIV infection.

**Table.** Abdominal ultrasonographic findings (not mutually exclusive) and mean CD<sub>4</sub> counts in patients with HIV infection in abdominal tuberculosis

	Number (%)	Mean CD <sub>4</sub> counts /μl
Lymphadenopathy	158 (64.8)	97.8 ± 59.0
Splenomegaly	68 (27.9)	86.5 ± 46.9
Hepatomegaly	49 (20.1)	86.9 ± 43.7
Bowel thickening	15 (6.1)	93.6 ± 89.6
Ascites	7 (2.9)	96.6 ± 49.4
Extensive abdominal involvement*	53 (21.7)	75.7 ± 62.7

\*More than one findings were present

As abdominal tuberculosis is a WHO stage IV disease, CD<sub>4</sub> count in our subjects were quite low and, lowest CD<sub>4</sub> counts were seen in patients with extensive abdominal involvement.

Antitubercular therapy led to clinical improvement and ultrasonographic resolution in majority of patients suggesting that USG can be used for treatment follow up. Cause of persistence of lesions in a few subjects could be due to HIV itself and needs further evaluation.

In conclusion, the findings of lymphadenopathy (size >15 mm) and hypoechoic/necrotic echotexture, hepatosplenomegaly with hypoechoic lesions in ultrasonography is suggestive of abdominal tuberculosis in HIV infected patients with prolonged fever and low CD<sub>4</sub> counts. However, above findings are not standardized and inability to confirm the diagnosis of tuberculosis by direct microscopy and culture is the limitation of this study. Ultrasonography is an affordable, widely available, non invasive tool which may be optimally utilized for the diagnosis of abdominal tuberculosis in HIV infected patients.

### References

1. Kwara A, Roahen-Harrison S, Prystowsky E, Kissinger R, Adams R, Mathision J, et al. Manifestations and outcome of extra-pulmonary tuberculosis: impact of human immunodeficiency virus co-infection. *Int J Tuberc Lung Dis* 2005; 9 : 485-93.
2. Sharma YR, Roy PK, Hasan M. Abdominal tuberculosis –a study of 25 cases. *Kathmandu Univ Med J (KUMJ)* 2004; 2 : 137-47.
3. National AIDS Control Organisation (NACO) . *Antiretroviral therapy guidelines for HIV-infected adults and adolescents including post-exposure prophylaxis*, NACO Guideline, New Delhi: NACO; 2007. p. 10.
4. Mugala DD. Abdominal tuberculosis in Chingola-Zambia: pattern of presentation. *East Cent Afr J Surg* 2006; 11 : 41-7.
5. Tarantino L, Giorgio A, de Stefano G, Farella N, Perrotta A, Esposito F. Disseminated mycobacterial infection in AIDS patients: abdominal US features and value of fine-needle aspiration biopsy of lymph nodes and spleen. *Abdom Imaging* 2003; 28 : 602-8.
6. Monill-Serra JM, Martinez-Noguera A, Montserrat E, Maideu J, Sabaté JM. Abdominal ultrasound findings of disseminated tuberculosis in AIDS. *J Clin Ultrasound* 1997; 25 : 1-6.
7. Joint United Nations Programme on HIV/AIDS (UNAIDS)/WHO. AIDS epidemic update. 2009. Available at: <http://www.unaids.org/en/knowledge/HIVDate/EpiUdata/EpiUpdArchive/2009/default.asp>, accessed on May 24, 2010.
8. Uzunkoy A, Harma M, Harma M. Diagnosis of abdominal tuberculosis: experience from 11 cases and review of the literature. *World J Gastroenterol* 2004; 10 : 3647-9.
9. Muneef MA, Nemish Z, Mahmoud SA, Sadoon SA, Bannatyne R, Khan Y. Tuberculosis in the belly: a review of forty-six cases involving the gastrointestinal tract and peritoneum. *Scand J Gastroenterol* 2001; 36 : 528-32.
10. Khan R, Abid S, Jafri W, Abbas Z, Hameed K, Ahmad Z. Diagnostic dilemma of abdominal tuberculosis in non-HIV patients: an ongoing challenge for physicians. *World J Gastroenterol* 2006; 12 : 6371-5.
11. Sharma MP, Bhatia V. Abdominal tuberculosis. *Indian J Med Res* 2004; 120 : 305-15.
12. Hui JP, Kwok KM, Lai MH, Loke TK, Luk WH, Chan JC. Tuberculous splenic abscess: an unusual presentation. *JHK Coll Radiol* 2007; 10 : 19-22.
13. Imani Fooladi AA, Hosseini MJ, Azizi T. Splenic tuberculosis: a case report. *Int J Infect Dis* 2009; 13 : e273-5.
14. Sharma SK, Smith-Rohrberg D, Tahir M, Mohan A, Seith A. Radiological manifestations of splenic tuberculosis: a 23 –patient case series from India. *Indian J Med Res* 2007; 125 : 669-78.

Reprint requests: Dr D. Agarwal, B-32/16A, Naria, Varanasi 221 005, Uttar Pradesh, India  
e-mail: drdiptiagarwal@yahoo.co.in