

# Infections of the Nervous System in India — a Review

**N. H. Wadia**

## **Introduction**

Regrettably, in an economically under-privileged environment, infections of the nervous system, as elsewhere in the body, prevail. Poor communication and illiteracy make prevention of spread of such diseases difficult. Whereas newer viral infections seem to predominate now in the West and developed nations, infection by bacteria, viruses and parasites is still seen in India.

## **Bacterial-Infections**

### Leprosy

This commonest peripheral neuropathy (neuritis) prevalent in India since 1400 B. C. still persists despite availability of curative drugs. Four million were said to be affected in 1985, but this is probably an underestimate (26). Nearly half a million new cases (of whom 20 to 25% are children) are detected every year and these appear to be more than the number cured despite much national effort at prevention and cure. The prevalence rate varies from 2 per 1,000 in certain parts of North India to 20 per 1,000 in the South and East. Borderline tuberculoid leprosy is prominent and 80% are of the non-lepromatous variety.

Preventive vaccines are being tried and treatment protocol by and large follows the WHO recommendations (19).

### Tuberculosis

There has been some downward trend in the incidence of tuberculosis of the central nervous system, but the position is far from satisfactory. It manifests intracranially as tuberculous basal meningitis (TBM), tuberculous encephalopathy and tuberculoma and less commonly as spinal meningitis and intraspinal tuberculoma.

### Basal Meningitis

The clinical features of the disease are well known, and need no repetition, but UDANI and colleagues (25) have drawn attention to a typical feature and unusual presentation. The diagnosis in India still depends on a clinician's skill and CSF examination, as demonstration of acid fast bacilli in the CSF has been possible in less than 30% of cases. No satisfactory rapid and sensitive confirmatory test based on detection of the bacterial antigen or antibody has yet been developed though a test devised by FRENCH et al. (6) to detect tuberculostearic acid (a structural component of *M. tuberculosis*) in the CSF has much to recommend.

## Encephalopathy

This condition though comparatively rare needs to be highlighted. UDANI and DASTUR (24) drew attention to its clinical features, pathology and pathogenesis. The child presents with convulsions, deepening coma, decorticate and decerebrate posturing due to diffuse cerebral oedema resulting either from delayed hypersensitivity to tuberculo-proteins or the brain's own myelin proteins.

## Tuberculomas

The incidence of intracranial tuberculoma is slowly declining. Autopsy data gathered from 1953 to 1978 (15) have revealed that whereas in 1963, 30.5% of all intracranial space occupying lesions were tuberculomas, in 1974 the percentage had fallen to 12.3%. Today most tuberculomas, even previously inoperable ones can be treated with antituberculous therapy under close CT/MRI monitoring and surgery is only reserved for large tumours with rapidly rising intracranial pressure where time is of the essence.

## Spinal Meningitis

Whereas intraspinal extension of basal meningitis with or without paraplegia is well known, WADIA and DASTUR (27) drew attention to patients who presented primarily with signs of radiculomyelopathy associated with spinal meningitis.

In the *subacute* form, the patient may have low fever and pain in the spine, severe signs of multiple root pains and paraplegia or quadriplegia with an ascending or transverse sensory level depending on the rapidity and localization of the infection and its effect on the underlying nervous tissue. The progress is usually over a few days but can extend to 6 to 8 weeks. In some untreated patients, the infection spreads intracranially showing signs of basal meningitis. The chronic form is much slower and often simulates a spinal cord tumour and cannot be clinically differentiated, except when there are widespread root pains not coinciding with the spinal cord level. In some patients, evidence of tuberculosis elsewhere or a history of contact can be obtained.

Pleocytosis, raised proteins and reduced sugar content in the CSF depend on the severity of infection and xanthochromia indicates a spinal block. Myelography shows an irregular column with filling defects and even a block.

Early vigorous antituberculous therapy can result in cure, but a high degree of morbidity is unfortunately seen.

## Viral-Infections

Whereas herpes simplex encephalitis, herpes zoster infection, Creutzfeldt-Jacob disease, the newly discovered Aids, and other viral infections prevalent in the West are also seen in India, the age-old Japanese-B encephalitis, poliomyelitis, rabies still continue to affect Indians in large numbers. Subacute sclerosing panencephalitis also occurs regularly in children. Further, a new tick-borne viral infection, the Kyasanur Forest disease was first reported from India in 1957 and attention was drawn to the neurovirulence of a new virus (EV 70) which had caused a pandemic essentially of an acute haemorrhagic conjunctivitis.

## Japanese-B Encephalitis

The disease was first recognized amongst patients in South India in 1955 and serologically confirmed (36, 37) and the virus isolated from mosquitoes in the same year (4). In 1973, a large epidemic occurred a thousand miles away in West Bengal. Since then the disease is endemic in these two areas as also Uttar Pradesh and Assam.

The disease affects the rural poor. In the South, children under 15 years are mostly affected, elsewhere no age is bar. The outbreaks occur commonly during the monsoon when mosquitoes multiply. Pigs act as intermediate hosts and neutralizing antibodies to the virus are found in 33 to 83%. Cattle egrets and pond-herons can also be hosts. Man to man transmission does not occur as the viremia is low. The disease manifests in the classical manner with fever, seizures, paralysis and unconsciousness. The mortality can reach 40%. There is no specific anti-viral therapy and prophylactic vaccines are not yet widely used.

### Poliomyelitis

With failed vaccination programmes over 30 years the disease has not abated. The annual incidence even today, is 20 to 40 per 100,000 population and nearly 500 cases are said to occur daily (9, 10). The high morbidity can be seen from the fact that lameness amongst preschool children due to it, rates 1 to 2 per 1,000 per year! Happily a fresh assault on the problem is being mounted with more potent vaccines and stricter monitoring of the programme.

### Rabies

This is endemic in India as there is a high population of stray unattended dogs. Incidence estimates are hard to make in the under-doctored rural areas. The disease presents most often in the classical hydrophobic (furious, fulminant) form, but attention has been drawn from India (2) as also elsewhere in the East to a form of paralytic or "dumb" rabies. Twenty percent of the patients present thus with an acute often ascending limb and intercostal paralysis rather than encephalitis and are initially mistreated as Guillain Barré syndrome till terminal convulsions, disorientation, confusion and coma occur, though the hydrophobia is often absent. As the dog-bite might have occurred months before the disease, careful questioning of such patients is required to make an early diagnosis.

### Kyasanur Forest Disease

A new virus disease affecting the villagers and wild monkeys of the Kyasanur Forest of the Shimoga district in the South Indian State of Karnataka was first reported in 1957 by WORK and TRAPIDO (38).

This RNA virus causes the only tick-borne virus disease in India. The tick *Haemaphysalis* usually transmits the virus amongst monkeys but about 10% of the population of the village get affected, children suffering most. It manifests (35) as a biundulant fever, with myalgia in the first phase and headache, vertigo, mental disturbance, focal neurological signs and neck stiffness after two to three weeks. The CSF shows pleocytosis and raised proteins. The virus can be always isolated up to the fifth day and at times the tenth. The diagnosis, therefore, later in the disease has to be confirmed by haemagglutination inhibition (HI) and complement fixation (CF) tests. The disease is comparable to the haemorrhagic fever described from the Soviet Union and the Far East.

### Enterovirus 70 disease (acute haemorrhagic conjunctivitis associated with neurological manifestations)

In March 1971, an epidemic of acute haemorrhagic conjunctivitis (AHC) spread in India, affecting several million persons. It was part of a pandemic which began in 1969 in Accra, Ghana and spread across North Africa and the Middle East to reach India. Another almost simultaneous focus began in Indonesia and spread in the East upto Japan. As the disease appeared at the time of the launching of the U. S. Apollo II spaceship to the moon, the natives called it the Apollo II disease.

Although no virus had been isolated, it was from West India that the first clinical observations regarding its neurovirulence were made. WADIA demonstrated two patients with an acute, hypotonic areflexic paralysis of the lower limbs following AHC and later published a report of 19 such patients (28, 29) and suggested that this new disease was due to a polio-like virus causing the conjunctivitis in many and an associated CNS disease in a few. KONO et al. (11) who had simultaneously isolated a new enterovirus (J 670/71 — later called EV 70) from the eyes of Japanese patients on accepting this clinical evidence of neurovirulence (12) injected the virus into the lumbar cord of monkeys to produce hind leg paralysis confirming the Indian observations. Soon KONO, WADIA and their colleagues collaborated to show significantly high antibody titres against the Japanese virus (J 670/71) in the serum of Indian patients, both with AHC alone, and AHC and CNS disease (13). Reports from other centres in India and the world which the conjunctivitis had visited amply confirmed the original observations (30, 33, 34).

In 1981, another pandemic engulfed the world. Once again there were millions of patients with conjunctivitis, and many centres from India reported associated paralysis (8, 33, 34). On this occasion, the Indo-Japanese collaboration showed high and rising antibody titres to EV 70 in the serum and CSF of patients with the neurological disease and the serum/CSF ratio indicated *de novo* synthesis of antibodies in the CNS (14, 31). Recently TANIYA et al. (23) have identified EV 70 specific IgG and IgM antibodies in the serum and CSF and suggested that this may be the most sensitive test to diagnose the disease early in future epidemics and to do serum surveys in affected populations.

The disease is bimodal. The AHC is usually bilateral. It lasts from 3 to 7 days and malaise is common. After an interval of an average of 3 weeks, paralysis follows often heralded by pains in the limbs, fever and headache. Very occasionally, the CNS disease may precede the AHC or appear on the same day, but it may be delayed by as long as 120 days.

In an Indian National Registry (8) which analysed 581 patients, 380 developed only limb paralysis, 104 only cranial nerve palsies and 97 had both in various combinations as also recorded by WADIA (30, 33, 34) (Table 1 and 2). Pains and occasionally burning paraesthesiae were soon followed by a hypotonic, asymmetrical, patchy paralysis.

The lower limbs were clearly more affected and sudden buckling of the knees was a common complaint at onset. Isolated affection of upper limbs was not often seen. In more severe cases, three or even all limbs, respiratory and bulbar muscles were involved. These cases were at times mistaken for Guillain Barré syndrome. The tendon reflexes were absent in the paralysed limbs. Amongst the cranial nerves, the facial was by far the most affected, alone or in combination with limb paralysis. Retention of urine, vertigo more often in patients with facial palsy, paraesthesiae, patchy sensory loss and even extensor plantar response was seen in a few patients at the onset of the disease, but disappeared within a few days or weeks.

The disease usually spares children and young adult males between 20 to 40 are most likely to become paralysed, though the conjunctivitis affects males and females equally. Pregnancy, exertion and intramuscular injections during the incubation period are more likely to precipitate paralysis. Recovery begins within weeks and continues for months, but the residual weakness depends on the initial severity and extent of the paralysis. Death has been reported in those extensively paralysed.

In the 1981 epidemic, a few patients with encephalitis, optic neuritis, papilloedema (with small ventricles), acute polyneuritis and a picture like Devic's disease closely associated with the AHC were seen. Whether these were also due to the virus itself or merely coincidental was never firmly established. A rare immunological response to the virus in the CNS has also been suggested.

TABLE 1  
**Clinical features of the neurological disease.**  
 581 patients of the Indian national registry.

PRODROMAL	NO. OF PATIENTS
Constitutional	353
Limb pains (Muscular and/or root)	318
Details unknown	28
<b>LOWER MOTOR NEURON PARALYSIS</b>	
Lower limb	457
Upper limb	85
Facial	130
Trigeminal	38
Vagus	33
Oculomotor	10
Abducens	6
Hypoglossal	5
<b>MILD, INFREQUENT FEATURES</b>	
Brisk reflexes, extensor plantars	7
Cutaneous sensory loss	51
Retention of urine	23
Vertigo	9
Impaired vibration	10

TABLE 2  
**Forms of presentation (90 patients)**

	NO. OF PATIENTS		TOTAL
	1971	1981	
Spinal	19	36	55
Facial	1	20	21
Spinal + Facial	0	6	6
Spinal + Trigeminal	0	3	3
Abducens	0	2	2
Trigeminal	0	1	1
Spinal + Facial + Vagus	0	1	1
Facial + Vagus	0	1	1
<b>TOTAL</b>	<b>20</b>	<b>70</b>	<b>90</b>

The neurological diagnosis is obvious during an epidemic, but may pose a problem at the beginning or end of an epidemic, in sporadic cases and in those not giving a history of AHC. In the acute phase pleocytosis and raised protein are found in the CSF especially in the spinal cases. The cellular response settles rapidly, and a later CSF examination may show only increased protein suggesting a false albumino-cytologic dissociation leading to a misdiagnosis of Guillain Barré syndrome.

Electromyography has been extensively done (28, 30, 33, 34), but is not necessary in the vast majority of cases. It shows classical changes of acute anterior horn cells disease, such as seen in poliomyelitis.

Isolation of the virus from the conjunctiva is possible in the first 3 days, but difficult from the CSF even in the paralysed patients. PAL et al. (18) have detected viral antigen in the CSF. Serological tests comprise virus neutralization (NT) and haemagglutination (HIT). High and rising titres in paired sera and CSF can be detected by now standardized tests. Further, a reduced serum NAT to CSF NAT ratio would suggest entry of the virus into the CNS. TANIYA et al. (23) have recently recommended adoption of the immunoglobulin-capture Elisa technique as a sensitive test to identify EV 70-specific IgG and IgM antibodies.

The real incidence in India or globally of the AHC or the CNS involvement has not been estimated, but an idea of its extent can be had from the fact that small focal surveys in India (3, 21) have shown that a quarter of the surveyed population had suffered from AHC, and HUNG and KONO (7) from Taiwan concluded that there was one neurological case for every 10,000 with AHC. Whereas extrapolation from these figures is palpably incorrect, WADIA (33, 34) felt that an estimate of 15,000 paralysed Indian patients in the 1981 pandemic was not too high.

It thus appears that a new virus causing an innocent-looking conjunctivitis can also cause in some a permanently crippling disease.

## **Parasitic-Infections**

### **Cysticercosis**

Cysticercosis is endemic in India since its first recognition. DIXON and LIPSCOMB (5) reported 450 cases over a span of 20 years amongst the British army in India. Today's surveys reveal no less. Random stool examination of 250,000 hospitalized patients in North India revealed taeniasis in 0.5 to 2% and figures rose to 12 to 15% in those living in labour colonies and slums (16). Further 25% of all intracranial space occupying lesions (22) and 2.2% of patients with epilepsy (17) are said to be due to cysticercosis.

The manifestation of the disease need not be discussed here, but it should be pointed out that in India multiple parenchymatous cysticerci in the brain are more than a single one and the meningeal racemose and ventricular types prevalent elsewhere are less common. Attention has been drawn from India to a rarer variety of cysticercosis where the patient comes with progressive dementia, intractable epilepsy and pseudohypertrophy of muscles mistaken for myopathy with few focal signs or raised intracranial pressure. WADIA et al. (32) have recently shown that this form is due to thousands of living cysticerci lodged in the brain and muscles simply occupying space without causing any local reaction as is seen with dying cysticerci. Therefore, the usual tell-tale calcification in muscles is not seen. They, however, showed elegantly for the first time that identification of these living forms can be made during life by CT scan of brain and muscles (Fig. 1 and 2). They also warned of the danger of the usual praziquantel therapy, reporting even fatality.

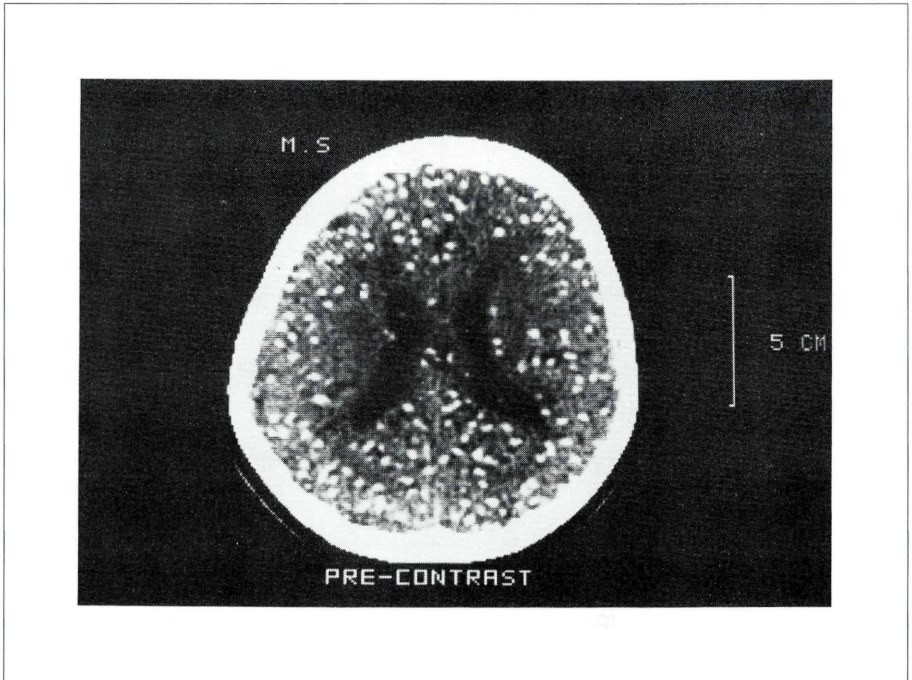


Figure 1:

Pre-contrast CT scan of the brain showing large numbers of cysticerci giving an effect of a "sky on a starry night". The white spots are the scolices of living cysticerci and not dead calcified cysticerci, attenuation density values being less than that of calcium. The cystic part can be seen next to each scolex though not very clearly here.

Finally, with the advent of new imaging techniques a previously undetected lesion in the brain has been revealed following a seizure, often focal. What is seen is a low attenuation area enhancing as a "ring" or "disc" after administration of contrast (Fig. 3). The patient has often no other symptoms or signs. As tuberculosis is common and some patients had associated tuberculosis, this was thought to be a micro-tuberculoma, and anti-tuberculous therapy given, with disappearance of the lesion. As more such cases appeared, and the lesion at times disappeared without any therapy except anticonvulsants, biopsies were done.

Now it appears that a variety of conditions can cause such an image. Besides, an isolated cysticercus, a small tuberculoma, focal encephalitis, a pyogenic microabscess, histoplasmosis, blastomycosis, sarcoidosis and infectious vasculitis have been found (1).

#### Cerebral Malaria

Immediately after the second world war, the annual incidence of malaria was 75 million cases and 0.8 million deaths in a population then of 300 million (20). With a massive campaign the incidence was reduced to 0.1 million by 1965 -1966, but with the resurgence of the mosquito, the number rose to 6.4 million by 1976 and now hovers around 2 to 3 million annually, 25% of which are believed to be due to *P. falciparum* causing cerebral malaria and more deaths. What has been equally worrying is the emergence of the chloroquine resistant strain in some parts of the country. Diagnosis is easy, once the index of suspicion is high.

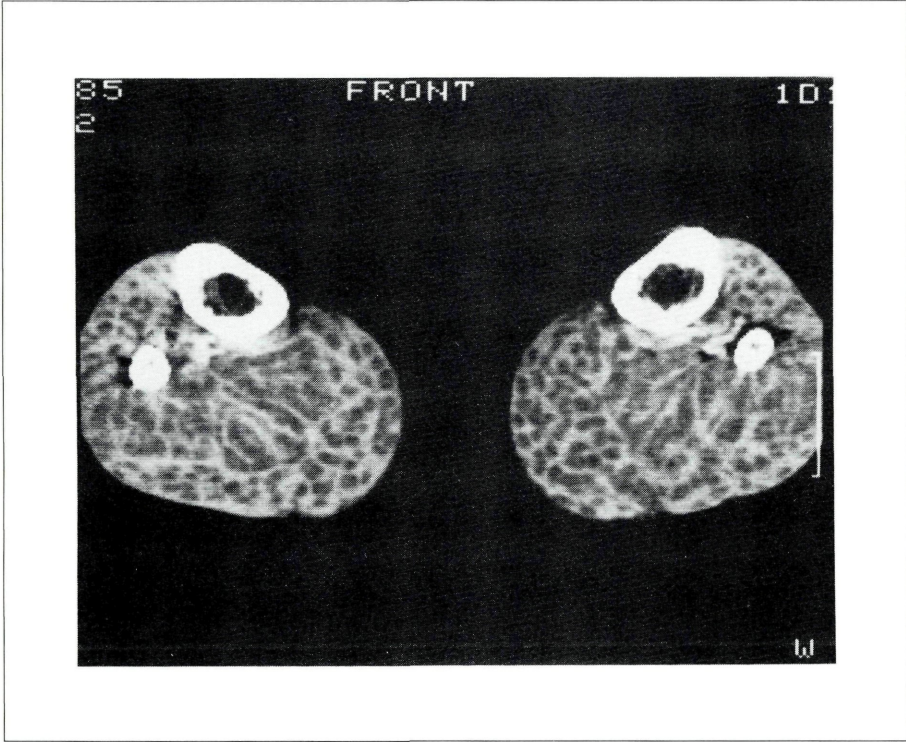


Figure 2:

Pre-contrast CT scan of both calves infiltrated with a vast number of living cysticerci giving a "honey-comb" effect. The cystic part is well seen, the scolices are the tiny white dots within. These are better seen on a magnified scan.

In patients with cerebral malaria, the parasitemia can be easily detected by thick smear preparation of blood. Where the incidence is low, the cases can be mistaken for viral encephalitis or other forms of coma.

### Summary

Whereas viral infection seems to now predominate in the developing world, regrettably bacterial, viral and parasitic infections are still seen in India in endemic and epidemic form affecting very large numbers. A short account, with some incidence and prevalence data of these is given.

### Key words

Infections, nervous system, India, bacterial, viral, parasitic.

### Zusammenfassung

Infektionen des Nervensystems in Indien — eine Übersicht

Während in den sogenannten entwickelten Ländern virale Infektionen des zentralen und peripheren Nervensystems vorherrschen, werden vor allem bakterielle und parasi-



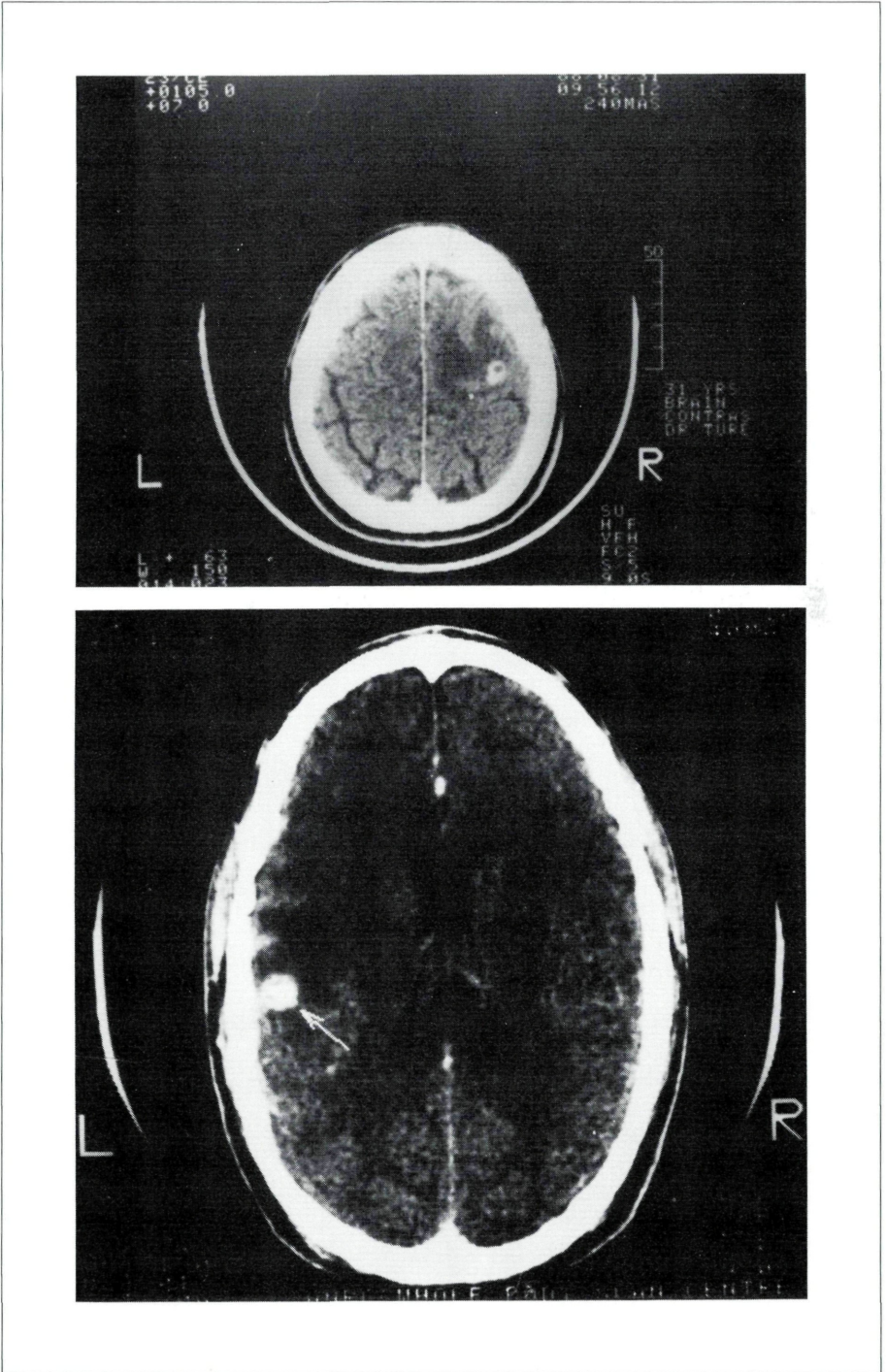


Figure 3:

CT scans of brain after contrast showing:  
(a) a ring and (b) a disc-enhancing lesion with adjacent oedema.

täre, neben viralen Infektionen in Indien beobachtet, wo diese Erkrankungen in epidemischer und/oder endemischer Form auftreten. Die wichtigsten neurologischen Infektionserkrankungen Indiens werden in ihrer Klinik und Epidemiologie dargestellt.

## Schlüsselwörter

Infektionen des Nervensystems, Indien, bakteriell, viral, parasitär.

## Literatur

1. BHATIA, R., TANDON, P. (1988): Solitary "microlesions" in CT: A clinical study and follow-up. *Neurol. India* 36, 139-150.
2. CHOPRA, J., BANERJEE, A., MURTHY, J., PAL, S. (1980): Paralytic Rabies. A clinico-pathological study. *Brain* 103, 789-802.
3. CHUTTANI, C. (1987): Personal communication.
4. DANDWATE, C., RAJAGOPALAN, P., PAVRI, K., WORK, T. (1969): Virus isolation from mosquitoes collected in North Arcot district, Madras State, and Chittoor district, Andhra Pradesh, between November 1955 and October 1956. *Indian J. Med. Res.* 57, 1420-1426.
5. DIXON, H., LIPSCOMB, F. (1961): Cysticercosis: An analysis and follow-up of 450 cases. *Medical Research Council Special Report Series* 299, 1-58.
6. FRENCH, G., TEOH, R., CHAN, C., HUMPHRIES, M., CHEUNG, S., MOHONY, G. (1987): Diagnosis of tuberculous meningitis by detection of tuberculosteric acid in cerebrospinal fluid. *Lancet* 1, 117-119.
7. HUNG, T., KONO, R. (1979): Neurological complications of acute haemorrhagic conjunctivitis (a polio-like syndrome in adults). In: *Handbook of Clinical Neurology*. Eds. Vinken, P., Bruyn, G., Elsevier, North Holland, Amsterdam 38, 595-623.
8. Indian Council of Medical Research (1985): Registry of patients with neurological complications following acute haemorrhagic conjunctivitis. *Jaslok Hosp. & Res. Centre, Bombay* (Principal investigator, Wadia, N.). *ICMR Bulletin* 15, 109-111.
9. Indian Council of Medical Research Bulletin (1988): Polio vaccine and poliomyelitis control 18, 10, 97-102.
10. JOHN, T. (1984): Poliomyelitis in India: Prospects and problems of control. *Rev. Infect. Dis.* 6 (Suppl.). S 438-441.
11. KONO, R., SASAGAWA, A., ISHII, K., SUGUIRA, S., OCHI, M., MATSUMIYA, H., UCHIDA, Y., KAMEYAMA, K., KANEKO, M., SAKURI, N. (1972): Pandemic of new type of conjunctivitis. *Lancet* 1, 1192-1194.
12. KONO, R., UCHIDA, N., SASAGAWA, A., AKAO, Y., KODAMA, H., MUKOYAMA, J., FUJIWARA, T. (1973): Neurovirulence of acute haemorrhagic conjunctivitis in monkeys. *Lancet* 1, 61-63.
13. KONO, R., MIYAMURA, K., TAJIRI, E., SHIGA, S., SASAGAWA, P., IRANI, P., KATRAK, S., WADIA, N. (1974): Neurological complications associated with acute haemorrhagic conjunctivitis virus infection and its serologic confirmation. *J. Infect. Dis.* 129, 590-593.

14. KONO, R., MIYAMURA, K., OGINO, T., WADIA, N., WADIA, P., KATRAK, S., MISRA, V. (1981): Antibody titres to enterovirus type 70 in the 1981 Indian Epidemic of acute haemorrhagic conjunctivitis. *Lancet* 2, 924.
15. LALITHA, V., DASTUR, D. (1980): Tuberculosis of the central nervous system (II Brain tuberculomas vis a vis intracranial space occupying lesions 1953-1978). *Neurol. India* 28, 202-206.
16. MAHAJAN, R. (1982): Geographical distribution of human cysticercosis. In: *Cysticercosis: Present state of knowledge and perspective*. Academic Press. 39-46.
17. MANI, A., RAMESH, C., AHUJA, G., MANI, K. (1974): Cerebral cysticercosis presenting as epilepsy. *Neurol. India* 22, 30-34.
18. PAL, S., SZUCS, G., MEHRICK, J. (1983): Rapid Immunofluorescence diagnosis of acute haemorrhagic conjunctivitis caused by Enterovirus 70. *Intervirology* 20, 19-22.
19. RAO, C., MITTAL, B., DHARMSHAKTU, N. (1988): Leprosy control based on multidrug treatment in India. *Ind. J. Leprosy* 60, 290-302.
20. SHARMA, G. (1983): Review of Malaria and its control in India. In: *Proceedings of the Indo-UK Workshop on Malaria*. Ed. Sharma, V. Malaria Research Centre, New Delhi 13.
21. SRINIVASA, D., D'SOUZA, V., KAMAT, G., ZINGDE, K. (1984): Epidemic haemorrhagic conjunctivitis in a rural community of Goa. *Ind. J. Med. Res.* 114-117.
22. TANDON, P. (1983): Cerebral cysticercosis. *Neurosurg. Review* 6, 119-127.
23. TANIYA, M., SAITO, M., FUJII, E., KONO, R., HIKIJI, K., ISHII, K. (1989): Polio-like motor paralysis associated with acute haemorrhagic conjunctivitis in an outbreak in 1981 in Bombay, India. Serologic studies by immunoglobulin capture Elisa and electrophoresis (submitted for publication).
24. UDANI, P., DASTUR, D. (1970): Tuberculous encephalopathy with and without meningitis. Clinical features and pathological correlations. *J. Neurol. Sci.* 10, 541-561.
25. UDANI, P., PAREKH, V., DASTUR, D. (1971): Neurological and related syndromes in CNS tuberculosis. Clinical feature and pathogenesis. *J. Neurol. Sci.* 10, 341-357.
26. VERMA, B. (1988): Task oriented medical education in leprosy for undergraduates in medical colleges in India. *Ind. J. Leprosy* 60, 430-441.
27. WADIA, N., DASTUR, D. (1969): Spinal meningitis with radiculomyelopathy. Part I. Clinical and Radiological features. *J. Neurol. Sci.* 8, 239-297.
29. WADIA, N., IRANI, P., KATRAK, S. (1973): Lumbosacral radiculomyelitis associated with pandemic acute haemorrhagic conjunctivitis. *Lancet* 1, 350-352.
30. WADIA, N., WADIA, P., KATRAK, S., MISRA, V. (1983): A study of the neurological disorder associated with acute haemorrhagic conjunctivitis due to Enterovirus 70. *J. Neurol., Neurosurg., Psychiat.* 46, 599-610.
31. WADIA, N., KATRAK, S., MISRA, V., WADIA, P., MIYAMURA, K., HASHIMOTO, K., OGINO, T., HIKIJI, T., KONO, R. (1983): Polio-like motor paralysis associated with acute haemorrhagic conjunctivitis in an outbreak in 1981 in Bombay, India: Clinical and serologic studies. *J. Infect. Dis.* 147, 660-668.

32. WADIA, N., SRINIVAS, D., BHATT, M. (1988):  
Disseminated cysticercosis. New observations, including CT findings and experience with treatment by praziquantel.  
Brain 111, 597-614.
33. WADIA, N. (1989):  
Neurological manifestations of enterovirus 70 (A 15 year review from India) in acute haemorrhagic conjunctivitis and enterovirus 70 infection.  
Eds. Uchida, Y., Ishii, K., Yamasaki, S., Miyamura, K. University of Tokyo Press, Tokyo, 251-266.
34. WADIA, N. (1990):  
Enterovirus 70 disease (Acute haemorrhagic conjunctivitis associated with neurological manifestations). In: Tropical Neurology.  
Ed. Roman, G., CRC Press, Florida, U. S. A. (In press).
35. WADIA, R. (1975):  
Neurological involvement in Kyasanur Forest Disease.  
Neurol. India 23, 115-120.
36. WEBB, J., PEREIRA, S. (1956):  
Clinical diagnosis of an arthropod-borne type of virus encephalitis in children in North Arcot District, Madras State, India.  
Ind. J. Med. Sci. 10, 573-581.
37. WORK, T., SHAH, K. (1956):  
Serological diagnosis of Japanese B encephalitis in North Arcot District of Madras State, India, with epidemiological notes.  
Ind. J. Med. Sci. 10, 582-592.
38. WORK, T., TRAPIDO, H. (1957):  
Kyasanur Forest Disease, a new virus disease in India.  
Ind. J. Med. Sci. 11, 1-2.

**KORRESPONDENZADRESSE:**

Dr. N. H. Wadia

A/8, Ben Nevis  
100, Bhulabhai Desai Road  
Bombay 400 036 · India