

## Interstitial: Site of Steroid Synthesis in the Ovary of the Long Term Hypophysectomized Hamster

KAZUYOSHI TAYA,<sup>1</sup> SRINIVAS K. SAIDAPUR<sup>2</sup>  
and GILBERT S. GREENWALD<sup>3</sup>

*Department of Physiology, Ralph L. Smith Research Center,  
University of Kansas Medical Center,  
Kansas City, Kansas 66103*

### ABSTRACT

The ovaries of hamsters hypophysectomized ( $\bar{H}$ ) on the afternoon of proestrus synthesize *in vitro* substantial amounts of progesterone for as long as 20 days post- $\bar{H}$  (Taya and Greenwald, 1979b). The purpose of the present study was to identify by histochemistry and ultrastructure the ovarian cell type which still possessed the enzymes capable of steroidogenesis despite the long term absence of gonadotropins.

After Day 6 post- $\bar{H}$ , the ovaries contained interstitium and viable and atretic small preantral follicles. The viable preantral follicles were histochemically devoid of  $\Delta^5$ - $3\beta$ -hydroxysteroid dehydrogenase ( $3\beta$ -HSDH). Histochemically, there were no appreciable changes in lipids in the interstitial gland cells (IGC) until Day 20 post- $\bar{H}$ , followed by a slight decrease by Day 30. The  $3\beta$ -HSDH activity in the IGC showed no appreciable changes until Day 6 and thereafter decreased gradually until Day 30. Trace amounts of glucose-6-phosphate dehydrogenase were found in the IGC until Day 6 and thereafter the enzyme was undetectable. The IGC contained only trace amounts of acid phosphatase until Day 10, followed by a gradual increase by Day 30.

A single *i.p.* injection of 5  $\mu$ g ovine LH on Day 10, 20 or 30 resulted 3 h later in dramatic increases in the concentration of serum progesterone and ovarian progesterone and testosterone but not estradiol-17 $\beta$ . Concomitantly, the depletion of lipid droplets in viable interstitial cells was observed by histochemical and ultrastructural criteria. However, lipid accumulations in degenerating interstitial cells and atretic granulosa cells were unaffected by LH treatment.

These data indicate that the interstitium is an active steroidogenic tissue for at least 30 days post- $\bar{H}$  and that LH can rapidly stimulate synthesis and secretion of progesterone and testosterone by the interstitium in long term hypophysectomized hamsters.

### INTRODUCTION

In the hypophysectomized ( $\bar{H}$ ) rat, primordial follicles continually develop but invariably undergo atresia by the time of antral formation; the regressed ovaries therefore contain only interstitial tissue and small preantral follicles (Smith, 1930). Whereas ovarian follicles and corpora lutea of the rabbit show extensive regression within 5-6 days after hypophysectomy, changes in the interstitium occur more slowly and severe vacuolar degener-

ation is not evident for several weeks (Foster et al., 1937). In a previous study, we showed that 2 days after hypophysectomy hamster ovaries *in vitro* produce large amounts of progesterone (P) and small amounts of testosterone (T) and estradiol-17 $\beta$  (E<sub>2</sub>) despite the lack of gonadotropins (Taya and Greenwald, 1979a). Moreover, ovaries removed from hamsters 1-2 weeks after hypophysectomy still synthesize *in vitro* large quantities of P and small amounts of T and E<sub>2</sub> (Taya and Greenwald, 1979b). Even as long as 20 days after hypophysectomy, hamster ovaries *in vitro* and without gonadotropic support are still able to produce  $\sim$ 1 ng/mg/h progesterone. Acute treatment of long term hypophysectomized hamsters with LH increases both the *in vivo* and *in vitro* production of P and T but not E<sub>2</sub> (Taya and Greenwald, 1979b).

Therefore, the present studies were designed to determine which cells are resistant to the effects of hypophysectomy in the hamster using histochemical and ultrastructural methods

Accepted October 31, 1979.

Received August 7, 1979.

<sup>1</sup>Present address: Laboratory of Veterinary Physiology, Faculty of Agriculture, Tokyo University of Agriculture and Technology, Fuchu, Tokyo 183, Japan.

<sup>2</sup>Present address: Department of Zoology, Karnataka University, Dharwar 580 003, India.

<sup>3</sup>Address reprint requests to: Dr. Gilbert S. Greenwald, Department of Physiology, University of Kansas Medical Center, Kansas City, Kansas 66103.

with emphasis on steroidogenic features of these cells.

### MATERIALS AND METHODS

Golden hamsters (*Mesocricetus auratus*) maintained on a 14L:10D schedule were used after 3–4 consecutive 4 day cycles. Proestrous hamsters were hypophysectomized between 1200–1300 h by the parapharyngeal approach under Nembutal anesthesia. After surgery the diet was supplemented with 5% glucose in the drinking water. At necropsy, the sella turcica was examined with a dissecting microscope for fragments of pituitary and animals were rejected in which any gross remnants were present.

Hamsters were decapitated at 1500 h on Day 2, 4, 6, 10, 20 or 30 after hypophysectomy and trunk blood was saved for the determination of progesterone (P), testosterone (T) and estradiol-17 $\beta$  (E<sub>2</sub>). The ovaries were excised immediately and then processed for determination of steroid levels and for histochemical and ultrastructural study.

#### Steroid Radioimmunoassay (RIA)

The ovaries were weighed to the nearest 0.01 mg and stored in 0.4 ml 95% ethanol at  $-20^{\circ}\text{C}$  until used for P, T and 17 $\beta$ -E<sub>2</sub> assays. The RIA methods for steroids were the same as previously described (Saidapur and Greenwald, 1978a; Terranova and Greenwald, 1978). Antisera for P (Surve et al., 1976), T (Pang and Johnson, 1974) and E<sub>2</sub> (Exley et al., 1971) were used. The lower limits of sensitivity were 5 pg/tube for P and 2 pg/tube for T and E<sub>2</sub> assays. Since the T antiserum crossreacts with 5 $\alpha$ -dihydrotestosterone (58%) and androsterone (2%), the steroid levels are referred to as testosterone equivalents. The inter-assay coefficient of variation calculated from control samples run in duplicate with each assay was 4.1% for P, 9.6% for T and 5.2% for E<sub>2</sub>. The intraassay coefficient of variation analyzed for each steroid from 13, 11 and 8 consecutive sets of assays was 2.4% for P, 0.8% for T and 0.7% for E<sub>2</sub>.

Data were analyzed by Student's *t* test. Differences were judged significant if  $P < 0.05$ .

#### Histochemistry

The ovaries were rapidly frozen over dry ice and cut in a cryostat maintained at  $-20^{\circ}\text{C}$ . The histochemical procedures were the same as those employed in an earlier study (Saidapur and Greenwald, 1978b). The lipids were stained using Sudan Black B or Oil red O. The methodological details for  $\Delta^5$ -3 $\beta$ -hydroxysteroid dehydrogenase (3 $\beta$ -HSDH) and glucose-6-phosphate dehydrogenase (G-6-PDH) were similar to those described previously (Baillie et al., 1966; Saidapur and Nadkarni, 1972; Saidapur and Greenwald, 1978b). The procedure for acid phosphatase was described by Pearse (1972). Appropriate controls were employed for all of the tests (Pearse, 1972).

#### Electron Microscopy

Ovaries were fixed in ice cold 3% glutaraldehyde phosphate buffer for 1–2 h at room temperature and

embedded in epon. Thick sections (1  $\mu\text{m}$ ) stained with toluidine blue were used to determine by light microscopy the different cell types of the ovary. Thin sections (600  $\text{\AA}$ ) were then cut using the LKB 8800 ultratome III. Sections were picked up on copper grids (#IGC 300), stained with uranyl acetate followed by lead citrate and examined in a Phillips 300 electron microscope at 60 kV.

#### Acute Effects of LH

Hamsters (3–5 hamsters/group) were injected i.p. with 5  $\mu\text{g}$  LH (NIH-S-16) at 1200 h of Day 10, 20 and 30 of hypophysectomy and killed 3 h later. The trunk blood and the ovaries were then processed for RIA of P, T, and E<sub>2</sub>. Ovaries of 3–5 hamsters were used for histochemical and ultrastructural studies. Saline (0.1 ml) injected hypophysectomized hamsters served as controls.

### RESULTS

Hypophysectomy performed before 1300 h on proestrus prevented ovulation. The ripe antral follicles present at the time of operation

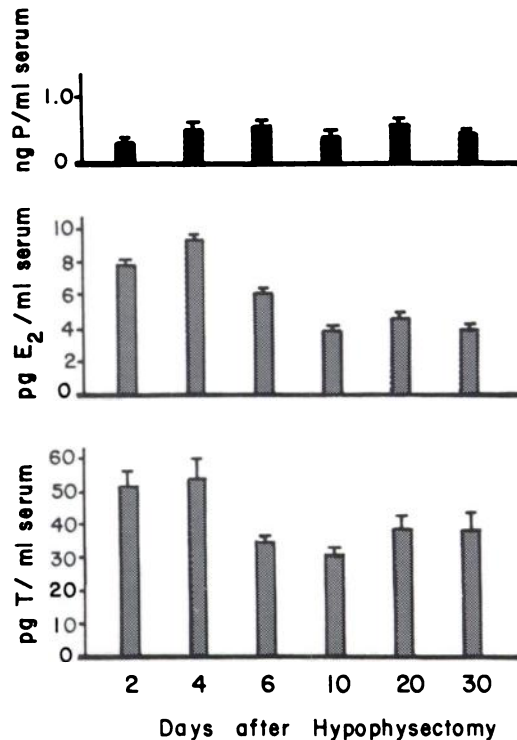


FIG. 1. Serum levels of progesterone (P), estradiol (E<sub>2</sub>) and testosterone (T) (mean + SEM) in the female hamster at different times after hypophysectomy. Sample size varied from 4 to 6 animals, except for Day 6 which had 12 animals.

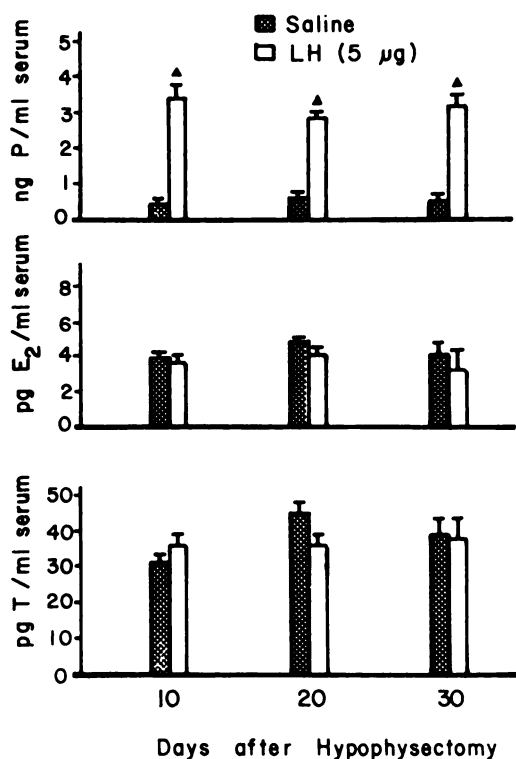


FIG. 2. Effect of 5 µg LH on serum levels of P, E<sub>2</sub> and T (mean + SEM) in the long term hypophysectomized female hamster. Hypophysectomized hamsters were injected i.p. with saline or LH and killed 3 h later. <sup>▲</sup>Significant compared with the controls (P<0.05). Sample size varied from 3 to 6 animals/point.

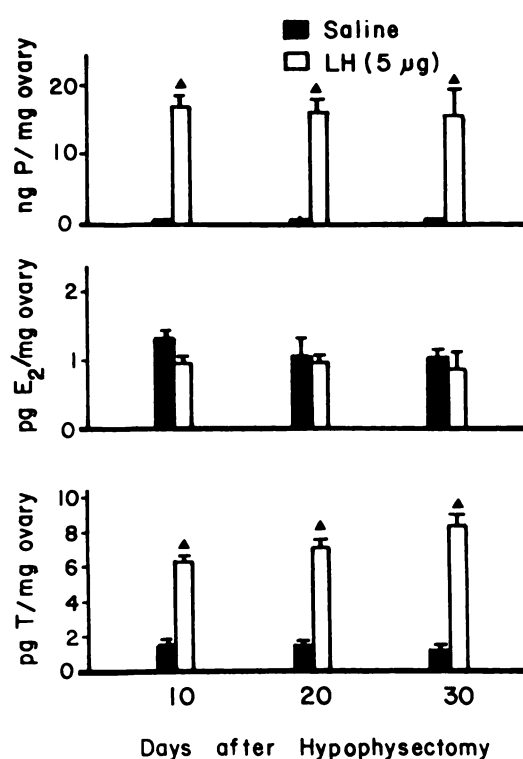


FIG. 3. Effect of 5 µg LH on ovarian levels of P, E<sub>2</sub> and T (mean + SEM) in the long term hypophysectomized hamster. These are the same animals shown in Fig. 2. <sup>▲</sup>Significant compared with the controls (P<0.05).

underwent a rapid degeneration. Histologically, the ovaries in the hypophysectomized hamster contained mainly interstitial gland cells (IGC) and atretic follicles between Days 2–30. A few small preantral follicles were recruited regularly but they rapidly regressed. The normal preantral follicles lacked 3β-HSDH. The description of histochemical and ultrastructural features therefore concerns the IGC, the only steroidogenically “active” component in the ovaries of the hypophysectomized hamster.

*Serum and Ovarian Levels of P, T and E<sub>2</sub> in the Hypophysectomized Hamster: Effect of LH*

Serum P remained at baseline levels (<1 ng/ml) from Days 2 to 30 following hypophysectomy (Fig. 1). Serum T levels were high (53 pg/ml) on Days 2 and 4 and abruptly decreased (35 pg/ml) by Day 6 (Fig. 1). There-

after, the T values remained the same (35 pg/ml) until Day 30. Serum E<sub>2</sub> declined gradually following the operation and was generally below the sensitivity of the assay (6 pg/ml) (Fig. 1). The ovarian P level was also less than 1 ng/mg (Fig. 3). Concentrations of ovarian T and E<sub>2</sub> remained low (1.5 pg/mg ovary).

A single i.p. injection of 5 µg LH on Day 10, 20 or 30 after hypophysectomy significantly increased (P<0.05) serum P, but not serum T and E<sub>2</sub> (Fig. 2). However, ovarian levels of both P and T increased significantly (P<0.05) 3 h after the injection of LH whereas E<sub>2</sub> was unchanged (Fig. 3).

*Histochemical Changes in Lipids, 3β-HSDH, G-6-PDH and Acid Phosphatase Activities*

*Lipids.* The interstitium contained moderate amounts of lipid droplets and did not show appreciable changes until Day 20 with lipids decreasing slightly by Day 30 of hypophysectomy (Table 1). The atretic granulosa cells

TABLE 1. Histochemical features of ovarian interstitial gland cells in the hypophysectomized hamster.

Days after hypophysectomy	Intensity of reaction <sup>a</sup>			
	$\Delta^5$ -3 $\beta$ -HSDH <sup>b</sup>	G-6-PDH	Acid phosphatase	Lipids
2	+++	+	±	++++
4	+++	±	±	++++
6	+++	±	±	++++
10	++	±	+	++++
20	+	±	++	++++
30	±	±	+++	+++

<sup>a</sup>Intensity of reaction is graded from (+) to (+++); (-) denotes the absence of reaction and (++++) denotes a maximal reaction.

<sup>b</sup>Dehydroepiandrosterone was used as the substrate.

of preantral follicles contained varying amounts of lipids depending on the stage of atresia (Figs. 4–7). Injection of LH on Days 10 or 20 resulted in the depletion of sudanophilic lipids from the interstitium (Figs. 4–7). However, some interstitial cells that were in advanced stages of degeneration did not respond to LH and their lipid content was unchanged (Fig. 5, double arrows). Lipid accumulations found in the granulosa cells of atretic preantral follicles were likewise unaffected by the administration of LH (Fig. 5, 7).

**3 $\beta$ -HSDH.** The 3 $\beta$ -HSDH activity in the interstitium appeared the same from Days 2 to 6 after hypophysectomy and began to decrease gradually by Day 10 (Figs. 8, 9). During subsequent days the enzyme was present only in traces and was often undetectable even though NADH-diaphorase was always present. On Day 10, ovarian 3 $\beta$  HSDH activity appeared the same in both LH treated and control hamsters (Figs. 9, 10). However, after LH treatment on Day 20, an increase in 3 $\beta$ -HSDH activity in the interstitium of LH treated animals was evident (Figs. 11, 12). Atretic granulosa cells of pre-

antral follicles showed weak 3 $\beta$ -HSDH activity.

**G-6-PDH.** The interstitium of the hamster ovary contains only traces of G-6-PDH activity (Saidapur and Greenwald, 1978b). After hypophysectomy there was a further decrease in the enzyme and consequently G-6-PDH was nearly undetectable in the interstitium after Day 6. Occasionally, traces of G-6-PDH were present in degenerating interstitial cells and the granulosa cells of atretic preantral follicles. Exogenous LH had no effect on G-6-PDH activity.

**Acid phosphatase.** Intense acid phosphatase activity was encountered only in the granulosa cells of atretic follicles (Figs. 13–16). In the interstitium, the enzyme was present only in trace amounts between Days 2–10 after hypophysectomy (Figs. 13, 14). Between Days 10–30, acid phosphatase activity increased in the interstitial cells (Fig. 14–16). Following the injection of LH, there was no change in histochemically demonstrable acid phosphatase.

#### Ultrastructure of Interstitial Cells

By Day 10 after hypophysectomy, the

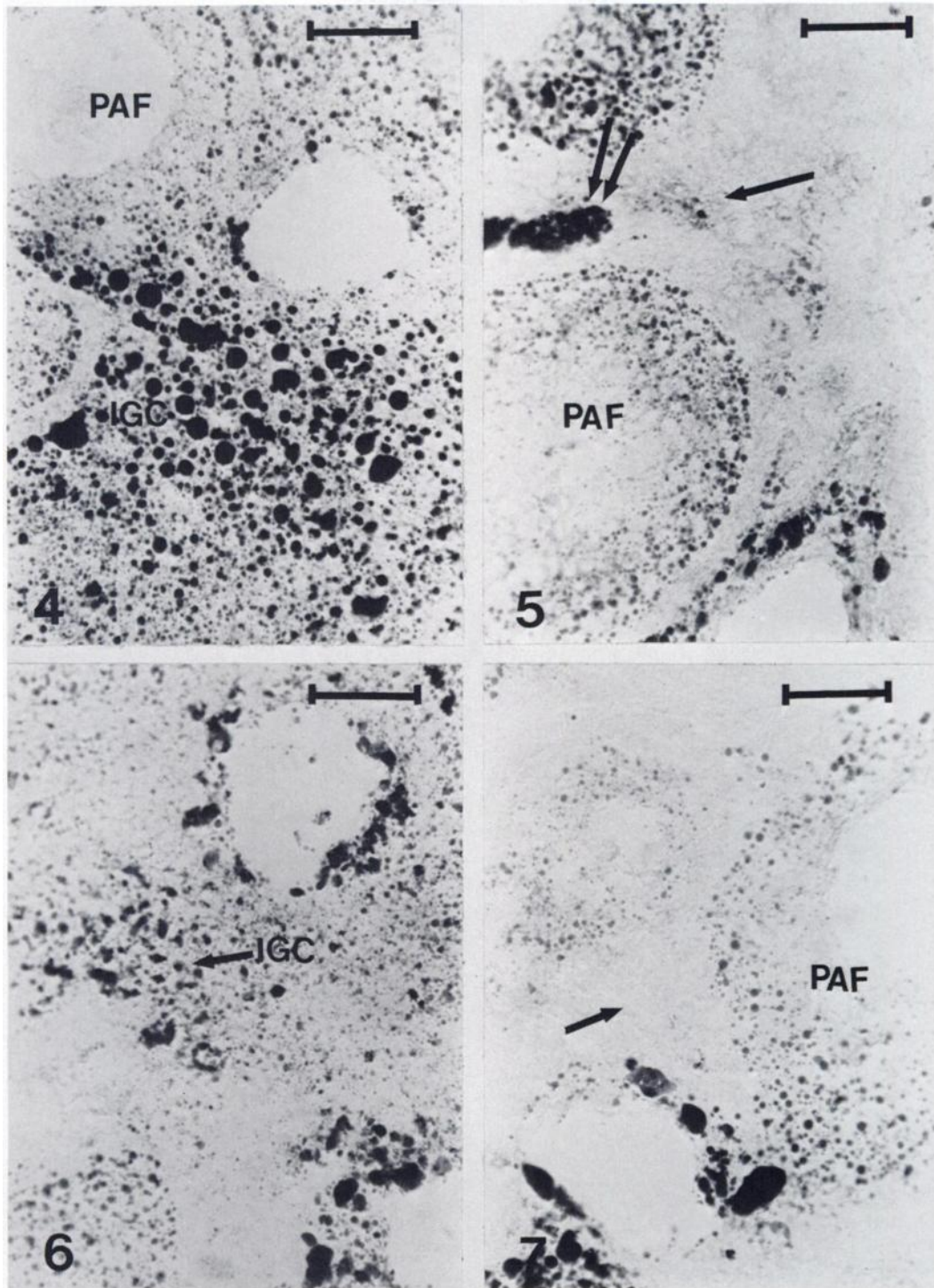
FIGS. 4–7. Distribution of Sudan black B positive lipid droplets in the ovaries of hypophysectomized hamsters. Scale lines indicate 50  $\mu$ m.

FIG. 4. Interstitial gland cells (IGC) and atretic granulosa cells of preantral follicles (PAF) are filled with lipid droplets on Day 10 of hypophysectomy (saline injected control).

FIG. 5. Lipid droplets of interstitial gland cells (arrow) are depleted 3 h after the injection of 5  $\mu$ g LH on Day 10 of hypophysectomy (cf. Fig. 4). Lipid accumulations in degenerative granulosa cells of preantral follicles (PAF) as well as some interstitial gland cells (double arrow) remain unchanged.

FIG. 6. Ovary demonstrating lipids in the interstitial gland cells (IGC) and in the granulosa cells of atretic preantral follicles on Day 20 of hypophysectomy (saline injected control).

FIG. 7. Ovary removed on Day 20 of hypophysectomy 3 h following injection of 5  $\mu$ g LH. Note the depletion of lipid in the interstitial gland cells (arrow). Compare with the control ovary shown in Fig. 6.





interstitium exhibited signs of shrinkage, loss of intercellular cohesion and varying degrees of cytoplasmic vacuolization (Figs. 17, 18). Some of the interstitial cells had undergone advanced degeneration (Fig. 18) whereas others were still well preserved with the characteristic large pleiomorphic nuclei. The mitochondria were spherical but contained mainly lamellar cristae (Fig. 17) and only a few tubular cristae. Myelin figures were also found in some mitochondria. Several lysosome-like bodies and lipid droplets were present. Both smooth and rough endoplasmic reticulum were scarce. Golgi bodies were normal.

After the administration of LH on Day 10, the most noticeable effect 3 h later was the depletion of lipids from several interstitial cells (Fig. 18). The mitochondrial cristae were transformed from lamellar to tubular in shape (Figs. 17, 18). The injection of LH, however, did not deplete lipid from degenerating interstitial cells or the atretic granulosa cells of preantral follicles.

#### DISCUSSION

After hypophysectomy, shortly before the critical period on Day 4 of the hamster cycle, antral follicles always showed definite signs of atresia even 1 day after operation; within 6 days after operation the ovaries contained interstitial tissue and small and medium sized preantral follicles (Taya and Greenwald, 1979a). In the present study, changes in serum P, T and E<sub>2</sub> levels following hypophysectomy also agree with our previous findings (Taya and Greenwald, 1979b).

In the present study, observations were begun on Day 2 posthypophysectomy when the *in vitro* production rate of progesterone was  $5.4 \pm 1.0$  ng/mg ovary/h compared with  $6.6 \pm$

0.7 ng/mg/h on Day 1 (Taya and Greenwald, 1979a). In contrast, in *sham* hypophysectomized hamsters on Day 1, the nonluteal ovary *in vitro* was unable to synthesize progesterone and on Day 2 produced 0.2 ng/mg/h (Taya and Greenwald, 1979a). In all of these experiments, the hamsters were hypophysectomized at 1300 h on Day 4 of the cycle (proestrus). In the *intact* hamster, the nonluteal ovary *in vitro* did not synthesize progesterone on Day 1 and the production rate of progesterone on Days 2–4 averaged 0.3 ng/mg/h (Terranova et al., 1978). Hence, *in vitro* the ovary of the  $\bar{H}$  hamster produces progesterone at a much greater rate than when the pituitary is present.

Histochemically, there were no appreciable changes in lipid in the interstitium until 20 days after hypophysectomy, followed by a slight decrease at 30 days. Moderate amounts of 3 $\beta$ -HSDH were found in the interstitium from Days 2 to 6 and there was a considerable decrease thereafter, consistent with the degenerative changes. The presence of lipid droplets (steroid precursors) and 3 $\beta$ -HSDH activity in the interstitium of ovaries of the hypophysectomized hamster indicates the capacity of these cells to synthesize steroid hormones.

Although with time more and more of the interstitial cells show degenerative changes, some of the population still appears to be morphologically and histochemically active as long as 30 days after hypophysectomy. Acid phosphatase, a lysosomal enzyme, is generally associated with autolytic processes and therefore is found only in the atretic follicles, as reported previously for the rat (Lobel et al., 1961) and the hamster (Saidapur and Greenwald, 1978b). Thus, the apparent lack of acid phosphatase indicates that there is no appreciable degeneration of the interstitium until Day 10. The present histochemical observations

---

FIGS. 8–12. Cryostat sections of the ovary showing 3 $\beta$ -HSDH activity in the hypophysectomized hamster. Scale lines indicate 50  $\mu$ m.

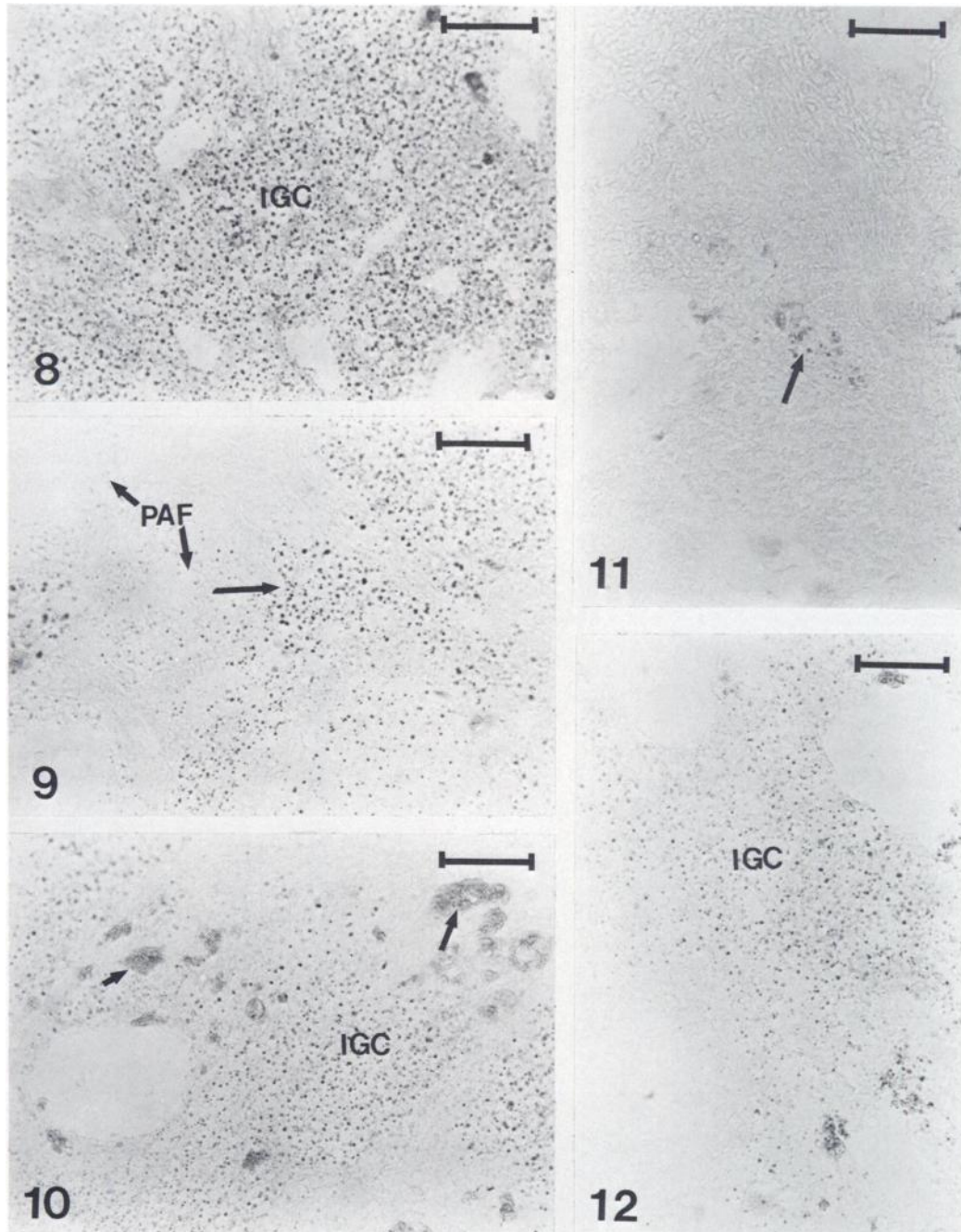
FIG. 8. Intense reaction for 3 $\beta$ -HSDH in the interstitial gland cells (IGC) on Day 2 of hypophysectomy.

FIG. 9. Decreased 3 $\beta$ -HSDH activity in the interstitial gland cells (arrow) on Day 10 of hypophysectomy. Compare with Fig. 8. Atretic granulosa cells of preantral follicles (PAF) also show weak enzyme activity.

FIG. 10. Portion of ovary showing 3 $\beta$ -HSDH in the interstitial gland cells (IGC) on Day 10 of hypophysectomy following the injection of LH. There are no apparent differences compared with the saline injected control ovary shown in Fig. 9. Arrows show degenerating IGC comparable to those shown in the upper portion of Fig. 5.

FIG. 11. Portion of ovary showing a marked decrease in 3 $\beta$ -HSDH activity in the interstitial gland cells (arrow) by Day 20 of hypophysectomy (saline injected control).

FIG. 12. After LH treatment on Day 20 of hypophysectomy, there is an increase 3 h later in 3 $\beta$ -HSDH in the interstitial gland cells (IGC). Compare with the saline injected control ovary shown in Fig. 11.



are in close agreement with our previous findings that ovaries removed from hypophysectomized hamsters still synthesize *in vitro* large amounts of P and small amounts of T and E<sub>2</sub> (Taya and Greenwald, 1979b). However, both studies have shown for the long term hypophysectomized hamster that *in vivo* the serum levels of ovarian steroids are below detectable limits indicating that the pituitary is indispensable for normal secretion of the hormones. At present, no explanation can be offered for the paradoxical difference between the *in vitro* and *in vivo* results.

The ovaries of hypophysectomized rats are characterized by the disappearance of vesicular follicles and regression of interstitial tissue, but the maintenance of the corpora lutea (Smith, 1930; Levy et al., 1959). At progressive periods after hypophysectomy, 3 $\beta$ -HSDH activity gradually declines in the interstitial tissue (Levy et al., 1959). Three months after hypophysectomy, no 3 $\beta$ -HSDH activity is demonstrable and hCG restores 3 $\beta$ -HSDH activity in the interstitial tissue (Taylor, 1961). In addition, ultrastructural changes of the rat ovarian interstitial tissue during regression following hypophysectomy have been described (Carithers and Green, 1972a) and these changes are reversed by administration of PMS (Carithers and Green, 1972b).

In the present study, a single injection of 5  $\mu$ g LH on Day 10, 20 or 30 posthypophysectomy resulted 3 h later in significantly increased serum P and ovarian P and T levels (Figs. 2, 3). It is noteworthy that the pattern of responsiveness of the ovary to exogenous LH was quite similar on Days 10, 20 and 30, although acid phosphatase activity increased in the interstitial gland cells during this period. These results suggest that in the hypophysectomized hamster, the increased steroidogenic response to exogenous LH is limited to the

production of P and T and most likely represents the interstitial compartment of the ovary. Histochemically, the interstitial gland in the ovaries of hamsters injected with LH on Day 10 or 20 showed a conspicuous reduction in the amount of sudanophilic lipid droplets. Treatment with LH on Day 20 of hypophysectomy also markedly increased 3 $\beta$ -HSDH activity in the interstitial gland cells.

The depletion of lipids from several interstitial gland cells following LH treatment on Day 10 was clearly seen in our ultrastructural studies. The atretic preantral follicles of various sizes and the degenerating interstitial gland cells, which were already present in the ovaries at the time of LH injection, did not show any change in either histochemical or ultrastructural studies with regard to their lipid content. The depletion of lipid droplets after LH injection in the hypophysectomized hamster suggests the formation of some steroids. Thus, the present histochemical and ultrastructural observations are in close agreement and correlate with the *in vivo* changes in serum and ovarian levels of steroid hormones.

Hilliard and Sawyer (1964) showed that rapid mobilization of interstitial tissue cholesterol in the rabbit following LH treatment was correlated with the synthesis and release of 20 $\alpha$ -hydroxypregn-4-en-3-one. Solod et al. (1966) also demonstrated in rabbit the *in vivo* and *in vitro* conversion of preformed cholesterol to 20 $\alpha$ -hydroxypregn-4-en-3-one by ovarian interstitial tissue following LH treatment.

Therefore, the present histochemical and ultrastructural data clearly demonstrate that LH can rapidly stimulate synthesis and secretion of P and T by the ovarian interstitial gland cells of long term hypophysectomized hamsters. Moreover, even in the absence of endogenous or exogenous gonadotropins, the interstitial cells are evidently the only ovarian

---

FIGS. 13–16. Sections of the ovary showing acid phosphatase activity in the hypophysectomized hamster. Scale lines indicate 50  $\mu$ m.

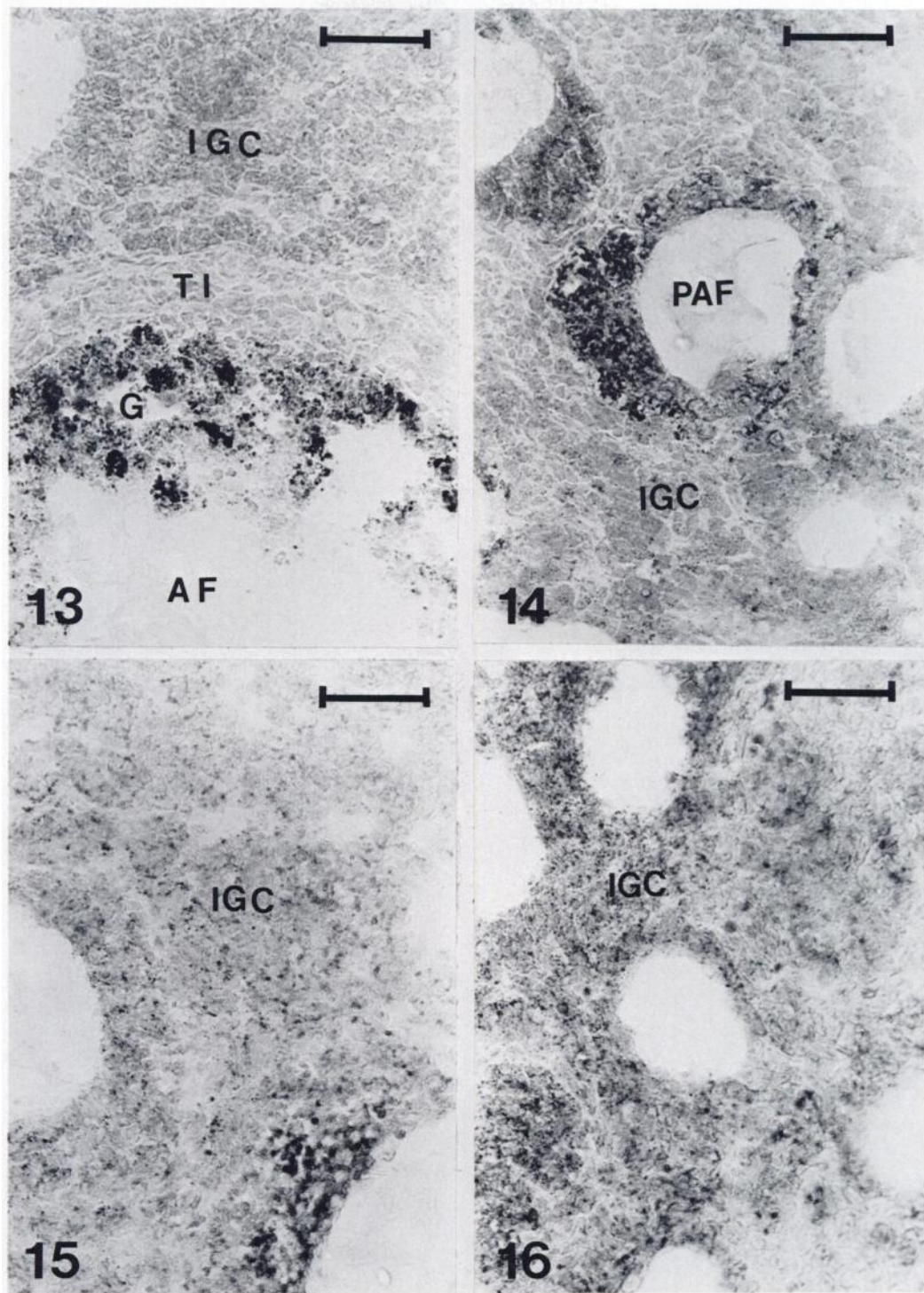
FIG. 13. Ovary on Day 2 of hypophysectomy showing an intense reaction for acid phosphatase in the granulosa cells (G) of an atretic antral follicle (AF) and its absence in the theca interna (TI) and the interstitial gland cells (IGC).

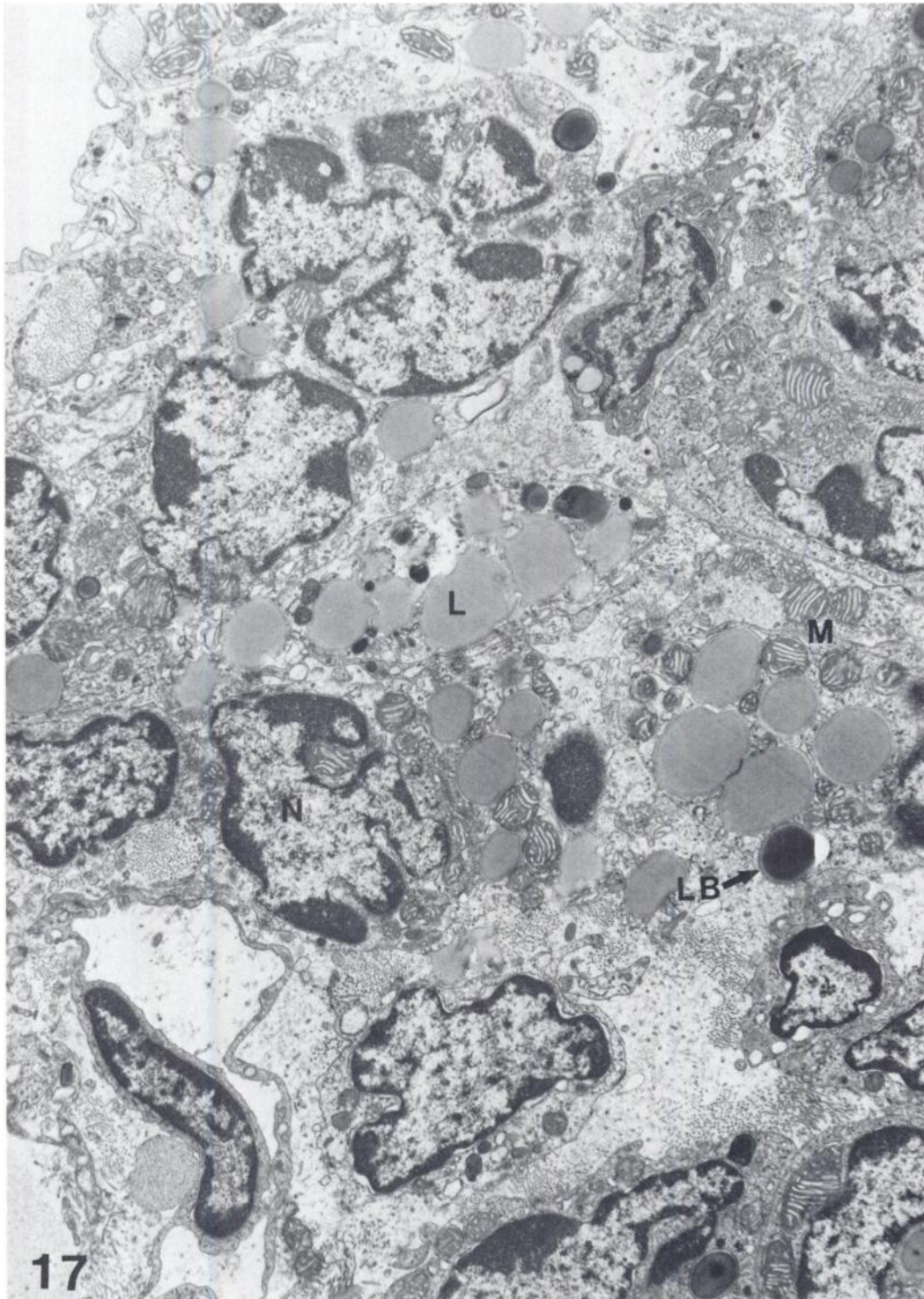
FIG. 14. Portion of ovary on Day 10 posthypophysectomy showing only traces of acid phosphatase in the interstitial gland cells (IGC). Acid phosphatase activity is strong in the granulosa of the atretic preantral follicle (PAF).

FIG. 15. Increase in acid phosphatase activity in the interstitial gland cells (IGC) on Day 20 of hypophysectomy.

FIG. 16. Ovary on Day 30 posthypophysectomy showing a further increase in acid phosphatase activity in the interstitial gland cells (IGC).

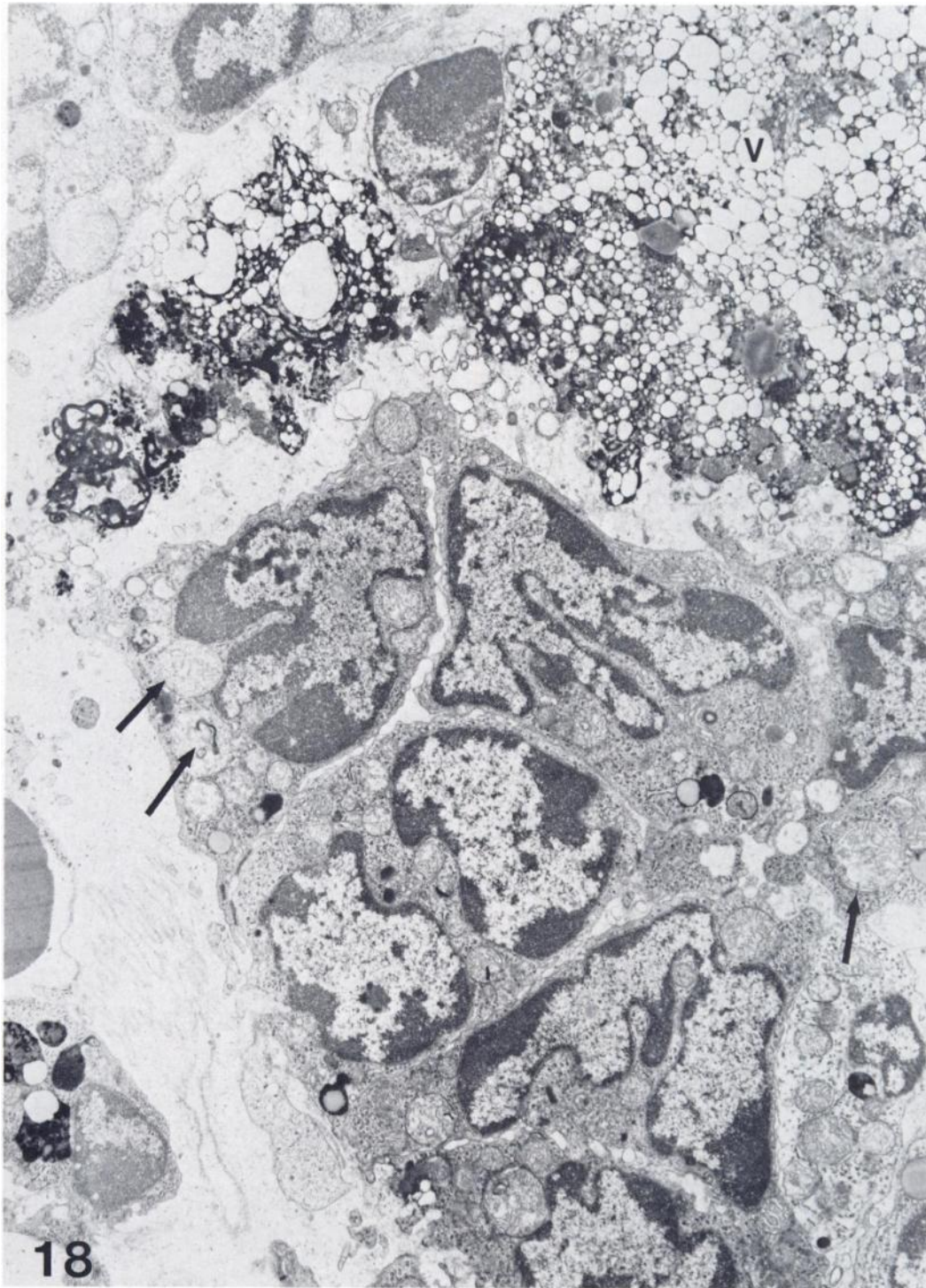






**17**  
**FIG. 17.** Interstitial gland cells on Day 10 of hypophysectomy (saline injected) showing large lipid droplets (L) and several lysosome-like bodies (LB). The mitochondria (M) show mainly lamellar and a few tubular cristae. X8400.





**FIG. 18.** Interstitial gland cells on Day 10 of hypophysectomy removed 3 h after administration of 5  $\mu$ g LH. The upper portion of the figure shows complete degeneration of some IGC. However, some IGC are still apparently healthy and respond to LH by depleting their lipid droplets. The mitochondria show mainly tubular cristae. A few mitochondria show myelin figures (arrows). V = vacuoles.  $\times 8400$ .

component that can account for the extensive *in vitro* production of progesterone in the long term hypophysectomized hamster.

#### ACKNOWLEDGMENTS

K. T. and S.K.S. were supported as Ford Foundation fellows in reproductive biology. The research was supported by a grant from NIH (HD00596). We thank the NIAMDD program of NIH for providing the ovine LH used in this study.

#### REFERENCES

- Baillie, A. H., Ferguson, M. M. and McKhart, D. (1966). *Developments in Steroid Histochemistry*. Academic Press, New York.
- Carithers, J. R. and Green, J. A. (1972a). Ultrastructure of rat ovarian interstitial cells. I. Normal structure and regressive changes following hypophysectomy. *J. Ultrastr. Res.* 39, 239–250.
- Carithers, J. R. and Green, J. A. (1972b). Ultrastructure of rat ovarian interstitial cells. II. Response to gonadotropin. *J. Ultrastr. Res.* 39, 251–261.
- Exley, D., Johnson, M. W. and Dean, P.D.G. (1971). Antisera highly specific for  $17\beta$ -estradiol. *Steroids* 18, 605–620.
- Foster, M. A., Foster, R. C. and Hisaw, F. L. (1937). The interrelationship of the pituitary sex hormones in ovulation, corpus luteum formation and corpus luteum secretion in the hypophysectomized rabbit. *Endocrinology* 21, 249–259.
- Hilliard, J. and Sawyer, C. H. (1964). Synthesis and release of progestin by rabbit ovary *in vivo*. *Proc. 1st International Congress Hormonal Steroids*. Vol. 1. New York, Academic Press. pp. 263–272.
- Levy, H., Deane, H. W. and Rubin, B. L. (1959). Visualization of steroid- $3\beta$ -ol-dehydrogenase activity in tissues of intact and hypophysectomized rats. *Endocrinology* 65, 932–943.
- Lobel, B. L., Rosenbaum, R. M. and Deane, H. W. (1961). Enzyme correlates of physiological regression of follicles and corpora lutea in ovaries of normal rats. *Endocrinology* 68, 232–247.
- Pang, C. N. and Johnson, D. C. (1974). A method for preparation of steroid-protein antigens for use in immunoassay of steroids. *Steroids* 23, 203–219.
- Pearse, A.G.E. (1972). *Histochemistry. Theoretical and Applied*. 3rd Ed. Vol. II. Churchill Livingstone, London.
- Saidapur, S. K. and Nadkarni, V. B. (1972).  $\Delta^5$ - $3\beta$ -Hydroxysteroid dehydrogenase and glucose-6-phosphate dehydrogenase in the testis of toad, *Bufo Melanostrictus* (Schneider). *Indian J. Exp. Biol.* 10, 425–427.
- Saidapur, S. K. and Greenwald, G. S. (1978a). Peripheral blood and ovarian levels of sex steroids in the cyclic hamster. *Biol. Reprod.* 18, 401–408.
- Saidapur, S. K. and Greenwald, G. S. (1978b). Sites of steroid synthesis in the ovary of the cyclic hamster: A histochemical study. *Am. J. Anat.* 151, 71–86.
- Smith, P. E. (1930). Hypophysectomy and replacement therapy in the rat. *Am. J. Anat.* 45, 205–273.
- Solod, E. A., Armstrong, D. T. and Greep, R. O. (1966). Action of luteinizing hormone on conversion of cholesterol stores to steroids secreted *in vivo* and synthesized *in vitro* by the pseudopregnant rabbit ovary. *Steroids* 7, 607–620.
- Surve, A. H., Barco, I., Brinckerhoff, J. H. and Kirsch, S. J. (1976). Plasma levels of progesterone in pseudopregnant rabbits actively immunized with a progesterone-protein conjugate. *Biol. Reprod.* 15, 343–349.
- Taya, K. and Greenwald, G. S. (1979a). Postovulatory steroidogenesis following ovulation induced by LH or FSH in hypophysectomized proestrous hamsters. *J. Reprod. Fert.* In Press.
- Taya, K. and Greenwald, G. S. (1979b). *In vitro* and *in vivo* ovarian steroidogenesis in the long-term hypophysectomized hamster. *Endocrinology*. In Press.
- Taylor, F. B. (1961). Histochemical changes in the ovaries of normal and experimentally treated rats. *Acta Endocrinologica* 36, 361–374.
- Terranova, P. F. and Greenwald, G. S. (1978). Steroid and gonadotropin levels during the luteal-follicular shift of the cyclic hamster. *Biol. Reprod.* 18, 170–175.
- Terranova, P. F., Connor, J. S. and Greenwald, G. S. (1978). *In vitro* steroidogenesis in corpora lutea and non-luteal ovarian tissues of the cyclic hamster. *Biol. Reprod.* 19, 249–255.