

THE JOURNAL OF BONE & JOINT SURGERY
J B & J S

This is an enhanced PDF from The Journal of Bone and Joint Surgery

The PDF of the article you requested follows this cover page.

Acute Guinea-Worm Synovitis of the Knee Joint

M. SIVARAMAPPA, C. R. R. M. REDDY, C. SITA DEVI, A. CHALMA REDDY, P. KANTHA REDDY and D. PRASANTHA MURTHY

J Bone Joint Surg Am. 1969;51:1324-1330.

This information is current as of May 23, 2011

Reprints and Permissions

Click here to [order reprints or request permission](#) to use material from this article, or locate the article citation on jbjs.org and click on the [Reprints and Permissions] link.

Publisher Information

The Journal of Bone and Joint Surgery
20 Pickering Street, Needham, MA 02492-3157
www.jbjs.org

Acute Guinea-Worm Synovitis of the Knee Joint

BY M. SIVARAMAPPA, M.S.*, C.R.R.M. REDDY, M.D.*, C. SITA DEVI, M.B.B.S., M. SC.*,
A. CHALMA REDDY, M.S.*, P. KANTHA REDDY*, AND D. PRASANTHA MURTHY*,
KURNOOL, ANDHRA PRADESH, INDIA

*From the Departments of Orthopedic Surgery, of Pathology, and of Biochemistry,
Kurnool Medical College, Kurnool*

In 1947 Stoll¹¹ estimated that more than fifty million people in the Middle East, Russia, Africa, South America, and India are infected with *Dracunculus medinensis*. Patnaik and Kapoor have shown that people in 240 of 329 districts in India have the infection. Reddy and co-workers, after an intensive survey in one district in South India, have shown that about one-half million people are at risk of getting the infection in the district⁸. The commonest manifestation of this worm is the formation of a bleb, on rupture of which the worm emerges from the base of the ulcer. The worm can also cause a sterile abscess by discharging its larvae into the tissues⁸. It can cause similar abscesses in ectopic sites such as the extradural space⁶. One other not uncommon manifestation is the entry of the worm into the knee joint, causing synovitis⁷. The knee joint might be involved by secondary infection along the track of a worm or by a mild synovitis due to allergy or mechanical effects due to the presence of a worm near the joint². Kothari and co-workers also described a mild synovitis without the presence of larvae in the aspirate of fluid from the joint. Johnson described cases in which she aspirated decomposing worms from grossly inflamed joints. In the present report we describe our experience with fourteen cases of acute synovitis of knee joint in which the larvae were shown in the joint aspirate and from which, in most, the worm was removed at arthrotomy. This type of synovitis is different from the septic arthritis or mild synovitis which occurs in guinea worm infection. If the condition is not recognized in the acute stages it might go on to chronic synovitis.

Clinical Findings

The main findings are summarized in Table I. All the patients who were seen with acute synovitis of the knee were men. The ages ranged from fourteen to forty. The patients came only during the summer months when the guinea-worm infestation is at its peak. The duration of the joint involvement ranged from two days to thirty days. The onset was always sudden. Six of fourteen patients did not have any allergic premonitory symptoms but five of them had local itching and rash. Three had generalized rash and itching. Thirteen men gave a previous history of repeated guinea-worm infection and only one did not give a previous history. This person had only a local not a generalized allergy. One patient felt the movement of the worm in the subcutaneous tissue near the suprapatellar region. On local examination there was no deformity in five patients. A flexion deformity ranging from 50 to 30 degrees was noted in the remaining nine patients. Signs of inflammation of the joint and effusion were present in all (Fig. 1). The synovial membrane was thickened in all. In most of the patients there was painful limitation of movement. Stability of the joint was good in all the patients. Weight-bearing intolerance was observed in four patients and the others were not able to stand or walk. Roentgenographic examina-

* Kurnool Medical College, Kurnool, Andhra Pradesh, India.

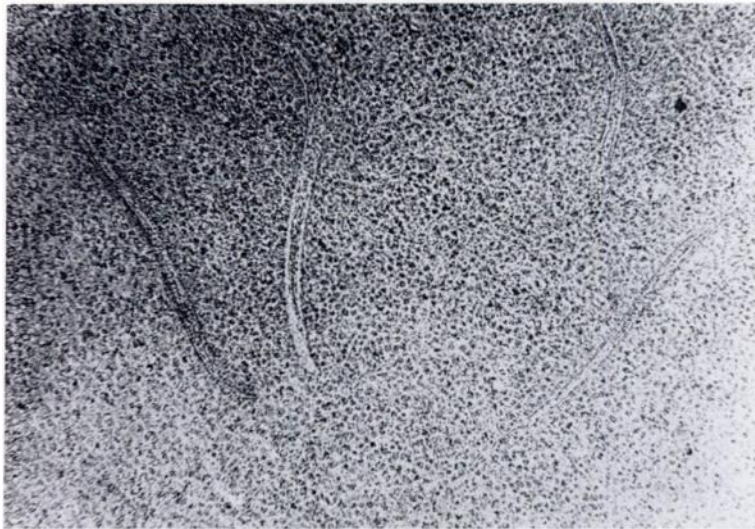


FIG. 1

Photomicrograph of guinea-worm larvae and cells from the synovial fluid ($\times 20$).

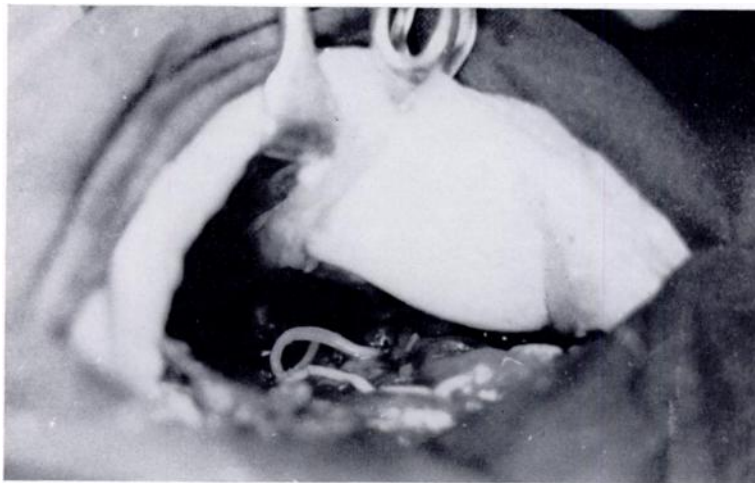


FIG. 2

Photograph of part of the coiled guinea worm in the suprapatellar pouch.

tion did not reveal any calcified worms in or around the knee joint in eleven of the fourteen. In two patients there was one calcified worm below the level of the knee joint; and, in one, two calcified guinea worms were present on the medial aspect of the joint. No changes were discovered in the bone or cartilage on skiagram.

Synovial Fluid

Aspiration of the fluid showed yellowish or yellowish turbid fluid in all patients. No fibrin threads were seen in the fluid in any of the patients. The turbidity was due to the cellular elements and larvae. Larvae were present in all. In three patients the larvae were alive and in the other cases they were dead (Fig. 1). The synovial fluid in all the patients cases was exudate and contained more than four grams of protein per 100 milliliters. In a few patients, in whom fibrinogen was sought, it was found to be absent in the synovial fluid. The differential count of the fluid and the blood of these patients and of the cells which were adherent to the larvae was published else-

where⁹. The eosinophilic leukocytes were increased in blood and also in the synovial fluid in patients having the infection for the first time. But on repeated infections elsewhere in the body the eosinophil count was reduced in both. White cells were adherent to larvae and the commonest cell adherent to the larvae was a macrophage—the other cells were neutrophils and eosinophils. Culture for any organisms was negative in all patients.

Diagnosis

Diagnosis was made by the demonstration of guinea-worm larvae in the synovial aspirate. In the absence of the larvae in the aspirate we did not make a diagnosis of acute guinea-worm synovitis.

Treatment

Conservative treatment in several patients with acute infection was not successful; repeated aspirations were undertaken with no improvement. In some patients the joint was irrigated with sterile saline solution through a wide bore needle. The joint could not be irrigated thoroughly because of the thick exudate which blocked the needle. The symptoms did not subside. In many patients the condition became chronic and was mistaken for other chronic specific conditions. Fluid in the joint, with chronic proliferation of synovial membrane, persisted for months. Surgery, undertaken late in these patients, was synovectomy or arthrodesis with consequent partial or complete stiffness of the knee after months of suffering.

Therefore, in the present series, operative treatment was undertaken soon after routine microscopy of the joint fluid in cases of acute synovitis disclosed guinea-worm larvae. In most patients arthrotomy was done within three days after the diagnosis was made. Arthrotomy was felt to be necessary, even though the synovitis was in the active state, for, the removal of the offending products of the worm and, if possible the worm itself, restored the joint to normal before irreversible changes had taken place.

Arthrotomy was done under tourniquet control. The joint was exposed through a short anterolateral or anteromedial incision. In all, the findings at operation were more or less similar. The fluid was turbid and yellow. In one patient, it resembled frank pus. The synovial membrane was thickened to two to four millimeters and thrown into folds; it was congested and edematous and was red in color; and it was covered by exudate. The amount of exudate varied with the duration of symptoms. In disease of long duration, the synovial membrane was covered with thick exudate; when the symptoms were of short duration, the exudate was thinner. The suprapatellar pouch was mainly involved. Surprisingly there were no adhesions even with long-standing disease. In the nine knee joints in which the worm was seen, it was seen on the femoral surface of the suprapatellar pouch (Fig. 2). In two, the worm was lying free and coiled up and could be removed easily; in the remaining knees part of the synovial membrane had to be excised to remove the worm which was partly embedded in the membrane. Irrigation of the joint cavity with normal saline solution revealed the shining surface of the synovial membrane, as the exudate could be easily separated from its surface. The wound was closed in layers. Compression bandage and plaster-of-Paris posterior slab were applied.

In many patients there was prompt relief from pain and swelling in the immediate postoperative period. In ten no antibiotic was given either preoperatively or postoperatively. Even in patients in whom the condition was acute and the aspirate resembled pus, no antibiotic was given as the cause of the synovitis is not bacterial but the uterine secretions of the worm. In the remaining four patients, penicillin was given as a precaution against secondary infection because of guinea-

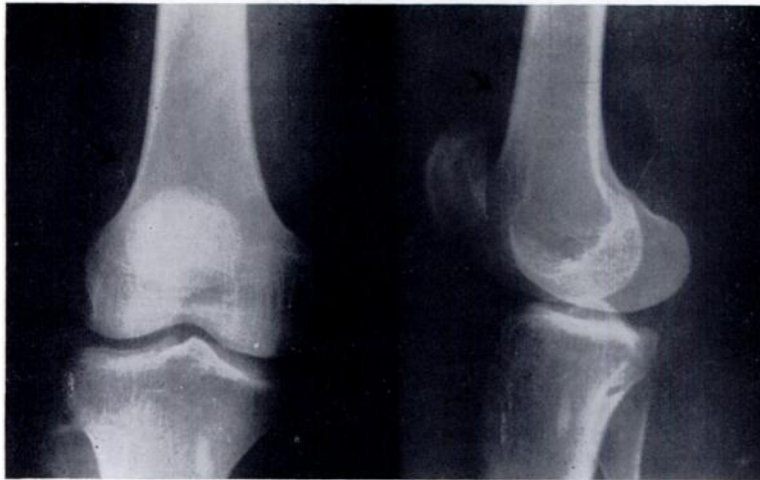

FIG. 3

Skiagram of the knee of Case 2 (anteroposterior and lateral views) four months after treatment showing a calcified worm in the suprapatellar pouch (arrows). The oval calcified guinea-worm which was already present a little below the knee is well seen in these pictures.

worm ulcers being present elsewhere on the leg. Quadriceps exercises were ordered in all patients soon after recovery from anesthesia. Sutures were removed on the tenth day. In most patients the effusion subsided by that time and the patients were allowed to walk with a compression bandage. Within a month, the effusion and thickening of synovial membrane had completely disappeared in all patients and the range of movement regained was more than 90 degrees. Within three months all the patients recovered a complete range of movement. All the patients went back to hard work, satisfied with the result at the end of three months.

The five knee joints from which the worm could not be removed, but in which larvae were present did not differ in any way, in the postoperative recovery, from the remaining nine knees in which the worm was detected and removed.

Pathology of the Synovial Membrane

Synovial membrane was thickened in all patients; the thickening was greater in the long standing disease and less in the disease of shorter duration. There was edema and cellular infiltration of the membrane. No fibrin was seen. In the early stages polymorphonuclear cells, eosinophils, plasma cells, and macrophages were seen, but in the later stages numerous giant cells were also seen.

Follow-Up

The patients were followed for periods ranging from eight months to two years and all of them were able to use their affected limbs normally and to do manual labor without any difficulty. There was no effusion, residual synovial membrane thickening, or limitation of movement.

In Case 2 (Table I) we were not able to find the worm at arthrotomy; however, on follow-up of the patient the worm was seen to be calcified four months after treatment (Fig. 3). It was in the suprapatellar pouch and it did not give any trouble to the patient. We saw this patient again two years after arthrotomy and he still has no complaint regarding the joint. He did not get another guinea worm infection in the two-year period which might have led us to think that the calcified worm was different from the previous one which had given rise to the acute synovitis.

Discussion

All of our patients were adult men who did active manual labor for their liveli-

TABLE I

No.	Age (Years)	Sex	Duration (Days)	Side	Allergic Symptoms	Previous History of Guinea-worm Infection	Flexion Deformity (Degrees)	Signs of Inflammation	Synovial Membrane	Larvae	Culture	Worm	Pain	Gait	Follow-up (Months)	Anti-biotics
1.	23	M	20	L	General	+	15	+	Thick	+	Negative	+	+	Limp	12	No
2.	20	M	4	R	None	+	80	+	Slightly thick	+	Negative	-	+	Notable	24	No
3.	20	M	15	R	None	+	None	+	Thick	+	Negative	+	+	Notable	26	+
4.	30	M	20	L	Local	-	+	+	Thick	+	Negative	-	+	Notable	12	+
5.	35	M	8	L	General	+	10	+	Thick	+	Negative	-	+	Notable	11	No
6.	40	M	5	R	Local	+	30	+	Thick	+	Negative	+	+	Limp	12	No
7.	35	M	10	L	General	+	10	+	Thick	+	Negative	+	+	Notable	20	No
8.	30	M	4	L	None	+	10	+	Slightly thick	+	Negative	+	+	Notable	1	No
9.	30	M	3	R	Local	+	30	+	Slightly thick	+	Negative	+	+	Notable	16	No
10.	30	M	4	L	Local	+	5	+	Thick	+	Negative	+	+	Notable	20	+
11.	14	M	30	R	None	+	None	+	Thick	+	Negative	+	+	Notable	18	No
12.	30	M	5	R	Local	+	None	+	Thick	+	Negative	-	+	Limp	18	No
13.	35	M	5	R	None	+	None	+	Thick	+	Negative	+	+	Limp	18	+
14.	18	M	30	R	None	+	80	+	Thick	+	Negative	-	-	Limp	18	No

hood. The onset was always sudden. All of them came from endemic areas. The first manifestation of guinea-worm infection could be an acute guinea-worm synovitis as it occurred in one of our patients.

Apart from septic arthritis or mild synovitis as a complication of guinea-worm infection close to the joint, true guinea-worm synovitis with the entry of the worm into the knee joint, discharging its uterine contents into the joint cavity, is a definite entity. The specific type of synovitis is not diagnosed in the absence of guinea-worm larvae in the joint. The cause of irritation of synovial membrane is a chemical one due to the uterine secretions of the worm, and the larvae probably do not have any role in the causation of the synovitis. The absence of fibrin or fibrinogen in the fluid aspirated from the joint cavity, the ease with which the synovial membrane could be washed free of the exudate, absence of adhesion formation in the joint, and the complete recovery following the washing of the joint by sterile saline solution and removal of the worm show that it is a chemical irritation. Even when the worm was not removed, the patients made an uneventful recovery. This again shows that the secretions of the live worm are the cause of the synovitis and not the dead empty shell of the worm. As in the case noted in follow-up a calcified worm does not give rise to any symptoms.

Fibrin and fibrinogen were present in the cases described by Kothari and co-workers. Greenwood described cases in which no larvae could be seen. These authors probably were discussing the cases of mild synovitis which might occur as a result of mechanical irritation of a large number of calcified guinea worms being present at the side of the joint or an allergic reaction due to the worm close to the joint. In none of our patients was fibrin present; and in a few patients fibrinogen was sought for and not found in the synovial fluid. Preliminary observations by Devi and co-workers showed that fibrinolytic enzymes and other proteolytic enzymes are present in the uterine secretions, without larvae, of the guinea worm. Therefore, the type of acute synovitis which we are describing is different from the mild synovitis described by others.

At arthrotomy a guinea worm was seen in the suprapatellar pouch of the knee-joint in nine patients. In the other five cases no worm was seen. The possibility of the worm lying in the posterior compartment of the joint could not be ruled out since only the anterior compartment of the joint was explored. The other possibility may be that the worm could have discharged some of its uterine contents into the joint cavity through the synovial membrane without the worm itself completely entering the joint. In either situation there is no chance of seeing the worm at arthrotomy.

Infra-red photography was tried to locate the worm when the worm was not present at arthrotomy, but we failed to demonstrate the worm.

Summary

Fourteen cases of acute guinea worm synovitis are described. The complete clinical picture, diagnosis, treatment, and follow-up are presented. That the guinea worm can cause a specific type of synovitis and that the causation of the synovitis is chemical in nature are demonstrated.

References

1. DEVI, C. S.; MURTHY, D. P.; LAKSHMI, S.; and REDDY, C. R. R. M.: Proteolytic and Fibrinolytic Activity of Guinea Worm (in press).
2. GREENWOOD, B. M.: Guinea-Worm Arthritis of Knee Joint. *British Med. J.*, 1: 314, 1968.
3. JOHNSON, M. F.: Guinea-Worm Arthritis of Knee Joint. *British Med. J.*, 1: 314, 1968.
4. KOTHARI, M. L.; PARDNANI, D. S.; MAHTA, L.; and ANAND, M. P.: Guinea-Worm Arthritis of Knee Joint. *British Med. J.*, 2: 435-456, 1968.
5. PATNAIK, K. C., and KAPOOR, P. N.: Incidence and Endemicity of Guinea-worm in India. *Indian J. Med. Res.*, 55: 1231-1242, 1967.

6. REDDY, C. R. R. M., and VALLI, V. V.: Extradural Guinea-Worm Abscess. Report of Two Cases. *Am. J. Trop. Med. and Hyg.*, **16**: 23-25, 1967.
7. REDDY, C. R. R. M.; and SIVARAMAPPA, M.: Guinea-worm Arthritis of Knee Joint. *British Med. J.*, **1**: 155-156, 1968.
8. REDDY, C. R. R. M.; REDDY, N. V.; REDDY, M.; and SULOCHANA, G.: Scrotal Dracunculosis. *J. Urol.* (in press).
9. REDDY, C. R. R. M.; PARVATHI, G.; and SIVARAMAPPA, M.: Adhesion of White Blood Cells to Guinea-worm Larvae. *Am. J. Trop. Med. and Hyg.*, **18**: 379-381, 1969.
10. REDDY, C. R. R. M.; NARASIAH, I. L.; and PARVATHI, G.: Epidemiology of Guinea Worm Infection. (accepted for publication by the Bulletin of the World Health Organization).
11. STOLL, N. R.: This Wormy World. *J. Parasitol.*, **33**: 1-18, 1947.