

Non-Hodgkin's Lymphoma Presenting with Prominent Splenomegaly

Clinicopathologic Diversity in Relationship to Immunophenotype

Sheila Nair, Jai Shukla and Mammen Chandy

From the Departments of Pathology (S. Nair; J. Shukla) and Haematology (M. Chandy) Christian Medical College and Hospital, Vellore, India

Correspondence to: Dr. Sheila Nair, Department of Pathology, Christian Medical College and Hospital, Vellore 632004, India

Acta Oncologica Vol. 36, No. 7, pp. 725–727, 1997

Splenomegaly is an uncommon presenting feature of non-Hodgkin's lymphoma. This is a study of 16 cases of non-Hodgkin's lymphoma presenting with prominent splenomegaly, which includes ten B-cell lymphomas and six T-cell lymphomas. There were distinct clinical and morphologic differences between these two immunologic types of splenic lymphomas, the B-cell types being predominantly low grade and occurring in older individuals whereas the T-cell lymphomas were predominantly high grade and occurred in adolescents and young adults.

Received 18 April 1997

Accepted 28 August 1997

Splenomegaly is not generally the presenting feature in patients with non-Hodgkin's lymphoma though it may be found during the course of the disease (1–5). Various criteria have been used for the diagnosis of primary malignant lymphoma of the spleen (6–9) and so the term 'lymphoma with prominent splenomegaly' is preferred (10, 11).

MATERIAL AND METHODS

We have studied 16 patients with non-Hodgkin's lymphoma who presented with prominent splenomegaly during a period of eleven and a half years (January 1985 to July 1996). All cases were principally confined to the spleen and its regional lymph nodes with or without involvement of liver and bone marrow but without peripheral lymphadenopathy.

Relevant clinical data were obtained from hospital and biopsy records. Tissue was processed routinely and 5 μ sections were stained with haematoxylin and eosin. Immunostaining was performed on paraffin sections by using the avidin–biotin–peroxidase technique and developed with diaminobenzidine. The antisera used included CD20 (L26) and CD79a as B-cell markers and CD45RO (UCHLI) and poly CD3 as T-cell markers. All markers were obtained from DAKO except for CD79a which was a gift from Professor D.Y. Mason, John Radcliffe Hospital,

Oxford. The cases were categorized according to the updated Kiel classification (12) and when possible entities described in the REAL scheme (13) were diagnosed.

In addition to spleens, lymph nodes were available for study in 8 cases, liver biopsies in 7 and bone marrow aspirates and/or biopsies in 13 cases.

RESULTS

Sixteen cases of non-Hodgkin's lymphoma presented with splenomegaly, constituting 1.04% of all non-Hodgkin's lymphomas during the study period. Based on immunohistochemical analysis they were categorized as B-cell lymphomas in 10 cases and T-cell lymphomas in 6 cases. These were separately analysed as they had distinct clinicopathologic features.

B-cell lymphoma:

All 10 cases were males with an age ranging from 45 to 70 years (mean 56.38 years). They presented with splenomegaly (10 cases), cytopaenias (8 cases) or 'B-symptoms' such as fever, weight loss, and fatigue (4 cases). The spleen was available for gross study in 9 cases. Moderate to massive splenomegaly with splenic weights ranging from 300 to 3700 g (mean 1430 g) was found. Cut sections showed uniformly distributed miliary nodules (Fig. 1). Bone marrow involvement was present in 5/8 cases and

regional lymph nodes were involved in another 5/8 cases (including small mesenteric nodes in 2 cases). There was no involvement of peripheral blood at presentation except for one case of marginal zone lymphoma.

Histologic classification according to Kiel classification showed 9 low-grade and one high-grade lymphoma (centroblastic lymphoma). The low-grade lymphomas included 8 centrocytic and one lymphoplasmacytic type. Of the centrocytic lymphomas, 7 were of the mantle cell type as described in the REAL scheme. In these cases there was a nodular pattern of involvement mainly confined to the white pulp with minimal involvement of red pulp (Fig. 2). They were composed of a monotonous population of small cells with irregular nuclei (Fig. 3). One case was of the marginal zone type, with widely spaced centrocytes intermixed with plasma cells and occasional centroblasts. This case was associated with abnormal lymphoid cells with hairy projections in the bone marrow smear and reactive lymphoid cells in the peripheral smear. The cells did not stain for tartarate resistant acid phosphatase. The single case of lymphoplasmacytic lymphoma showed diffuse infiltration of red as well as white pulp by tumour. One case of centroblastic lymphoma showed localized tumour with involvement of both white and red pulp by centroblasts.

T-cell lymphoma:

Of the 6 cases belonging to this category 5 were males with an age ranging from 12 to 30 years (mean 21.7 years). All presented with fever and splenomegaly and three with bleeding due to thrombocytopenia. Bone marrow and liver involvement was present in all 5 cases (in one case, an outside referral, these details were not recorded).

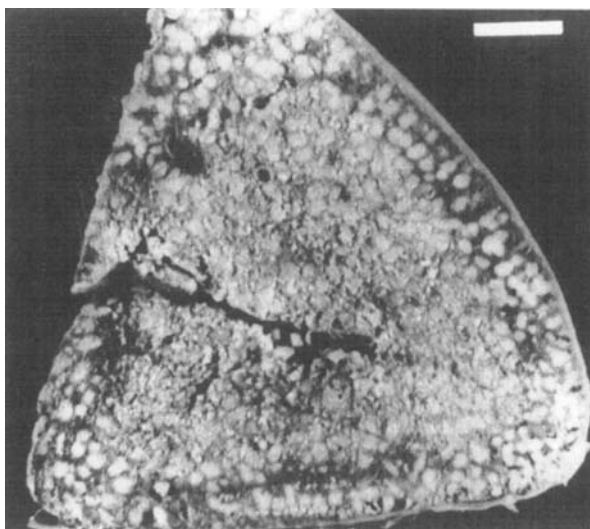


Fig. 1. Cut section of spleen showing uniformly distributed military nodules.

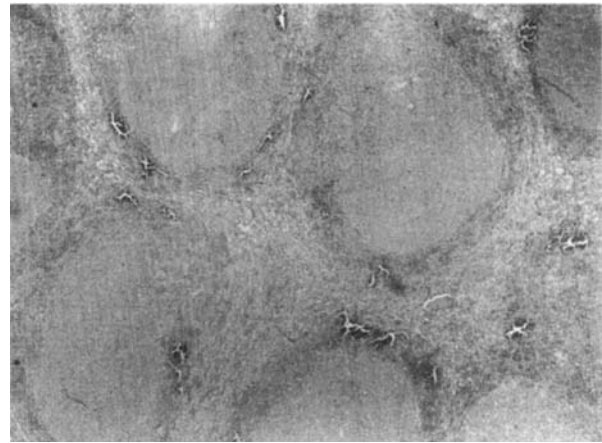


Fig. 2. Mantle cell lymphoma: nodular pattern due to confinement to the white pulp and minimal involvement of the red pulp (H&E $\times 20$).

The weights of the spleens ranged from 308 to 4100 g and their cut surfaces showed diffuse congestion. Histologically they were all peripheral T-cell lymphomas, 5 predominantly large cell type and one pleomorphic small cell type.

DISCUSSION

Non-Hodgkin's lymphomas presenting with splenomegaly are quite rare, only amounting to about 1–2% of all lymphomas (11). (It constituted only 1.04% of all lymphomas in our study). Non-Hodgkin's lymphomas arising primarily in the spleen remain principally confined to the spleen and its local lymph nodes. The disease may then spread from this area to more distant sites, such as other abdominal lymph nodes, liver or bone marrow. Peripheral adenopathy is either not existent or may represent a very late seeding from the spleen (6).

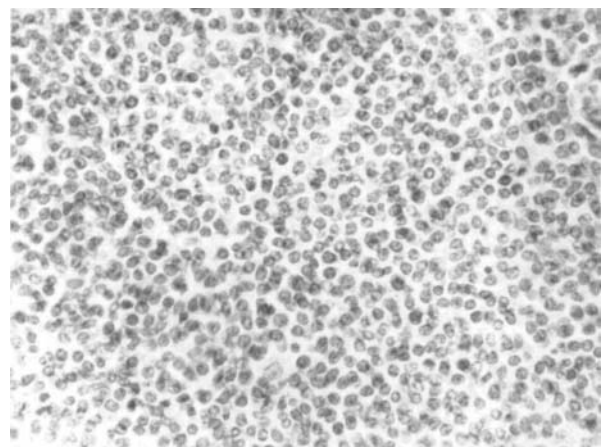


Fig. 3. Mantle cell lymphoma: monotonous population of small cells with irregular nuclei (H&E $\times 400$).

Most previous reports indicate predominance of low-grade B-cell lymphomas (8–11). A small number of T-cell lymphomas of the spleen have also been reported (8, 11, 14). This study also shows a predominance of low-grade B-cell lymphomas over T-cell types. Among the low-grade B-cell lymphomas a majority was of the mantle cell type as described in recent literature (10, 11). In one case of splenic marginal zone lymphoma villous lymphocytes were detected on bone marrow aspirate and imprints from the spleen. This was consistent with the entity SLVL (splenic lymphoma with villous lymphocytes) as described in literature (15).

Our study showed distinct clinical and morphologic differences between the two immunological types of splenic lymphomas. B-cell types were predominantly of low-grade and occurred in older individuals, whereas T-cell types, found in young adults and adolescents, were predominantly of high-grade and with liver involvement. These high-grade T-cell lymphomas probably represent the hepato-splenic gamma delta T-cell lymphomas as described in literature (16).

This material contains more aggressive lymphomas and more T-cell lymphomas than would be expected in industrialized countries. However, it fits in well with the pattern known from developing countries.

REFERENCES

- Ahmann DL, Keily JM, Harrison DG, Payne WS. Malignant lymphoma of spleen. *Cancer* 1966; 19: 461–9.
- Skarin T, Davey FR, Moloney WC. Lymphosarcoma of spleen. *Arch Intern Med* 1971; 127: 259–65.
- Davey FR, Skarin AT, Moloney WC. Pathology of splenic lymphoma. *Am J Clin Pathol* 1973; 59: 95–103.
- Long JC, Aisenberg AC. Malignant lymphoma diagnosed at splenectomy and idiopathic splenomegaly. A clinicopathologic comparison. *Cancer* 1974; 33: 1054–61.
- Kraemer BB, Osborne BM, Butler JJ. Primary splenic presentation of malignant lymphoma and related disorders: a study of 49 cases. *Cancer* 1985; 44: 1948–57.
- Kehoe J, Straus DJ. Primary lymphoma of spleen. Clinical features and outcome after splenectomy. *Cancer* 1988; 62: 1433–8.
- Audouin J, Diebold J, Schwartz H, Le-Tourneau A, Bernadou A, Zittoun R. Malignant lymphoplasmacytic lymphoma with prominent splenomegaly (primary malignant lymphoma of spleen). *J Pathol* 1988; 155: 17–33.
- Falk S, Stutte HJ. Primary malignant lymphoma of spleen: A morphologic and immunohistochemical analysis of 17 cases. *Cancer* 1990; 66: 2612–9.
- Brox A, Bishinsky JJ, Berry B. Primary non-Hodgkin's lymphoma of the spleen. *Am J Haematol* 1991; 38: 95–100.
- Narang S, Wolf BC, Neiman RS. Malignant lymphoma presenting with prominent splenomegaly. *Cancer* 1985; 55: 1948–57.
- Pittaluga S, Verhoef G, Criel A, et al. Small B-cell non-Hodgkin's lymphomas with splenomegaly at presentation are either mantle cell lymphoma or marginal zone cell lymphoma. *Am J Surg Pathol* 1996; 20: 211–23.
- Stansfeld A, Diebold J, Kapanci Y, et al. Updated Kiel classification for lymphoma. *Lancet* 1988; 1: 292.
- Harris NL, Jaffe ES, Stein J, et al. A revised European-American classification of lymphoid neoplasms: A proposal from the International lymphoma study group. *Blood* 1994; 84: 1361–92.
- Stroup RM, Burke JS, Sheibani K, BenEzra J, Brownell M, Winberg CD. Splenic involvement by aggressive malignant lymphomas of B cell and T cell types. *Cancer* 1992; 69: 413–20.
- Isaacson PG, Matutes E, Burke M, Catovsky D. The histopathology of splenic lymphoma with villous lymphocytes. *Blood* 1994; 84: 3828–34.
- Farcet JP, Gaulard P, Marolleau JP, et al. Hepatosplenic T-cell lymphoma: sinusal/sinusoidal localization of malignant cells expressing the T-cell receptor gamma delta. *Blood* 1990; 75: 2213–9.