



THE CENTRAL AFRICAN JOURNAL OF MEDICINE

Vol. 41, No. 9

CONTENTS

September, 1995

ORIGINAL ARTICLES

- Haemolytic uraemic syndrome following *Shigella dysenteriae* type 1 outbreak in Zimbabwe: a clinical experience KJ Nathoo, JA Sanders, S Siziya 267
- Neoplastic and non-neoplastic ovarian disease in Zimbabwean women G Stanczuk 274
- A community survey of traditional medical practitioners in high density suburbs of Harare CM Winston, V Patel, T Musonza, Z Nyathi 278
- Immunopharmacological aspects of praziquantel. NZ Nyazema, FF Mutamiri, I Mudiwa, A Chimuka, J Ndamba 284
- Schistosomiasis and hepatitis B infection in pregnancy: implications for vaccination against hepatitis B M Patana, NZ Nyazema, J Ndamba, A Munatsi, O Tobaiwa 288

CASE REPORTS

- Unusual presentation of abdominal pregnancy J Shava, P Kawesa, N Magula, E Theron 293
- Secondary post partum haemorrhage due to uterine wound dehiscence JV Larsen, K Janowski, A Krolikowski 294
- Branchiogenic carcinoma – a case for radiation induced carcinogenesis RN Visweswara, MH Patel 296
- Granular cell myoblastoma of the cervix in a 14-year-old girl A Haberal, F Turgut, B Ozbey, T Kuçukali, M Sapmaz 298

LETTERS TO THE EDITOR

- Case report: Fulminating *Pneumocystis carinii* pneumonia GDS Turner 300

NOTES AND NEWS

- 11th International Symposium on Bioengineering and the Skin P Elsner 302

EDITORIAL BOARD

EDITOR IN CHIEF

Dr. J.A. Matenga

ASSOCIATE EDITOR

Dr. J. Mufunda

EDITORIAL BOARD MEMBERS

<i>Professor C Chetsanga</i>	<i>(Zimbabwe)</i>
<i>Dr N J T Gwavava</i>	<i>(Zimbabwe)</i>
<i>Mr A C Harid</i>	<i>(Zimbabwe)</i>
<i>Professor M P Mandara</i>	<i>(Tanzania)</i>
<i>Professor K Mukelabayi</i>	<i>(Zambia)</i>
<i>Dr Jane Mutambirwa</i>	<i>(Zimbabwe)</i>
<i>Professor F K Nkrumah</i>	<i>(Ghana)</i>
<i>Professor C Olweny</i>	<i>(Australia)</i>
<i>Professor R Owor</i>	<i>(Uganda)</i>
<i>Professor A Petropoulos</i>	<i>(USA)</i>
<i>Professor J E P Thomas</i>	<i>(Zimbabwe)</i>

TECHNICAL EDITOR

Mrs L.M. Cooper

ADMINISTRATIVE MANAGER

Mr C B Mashavira

PAST EDITORS

<i>Professor M. Gelfand</i>	<i>(1953-1985)</i>
<i>Professor H M Chinyanga</i>	<i>(1985-1990)</i>

All manuscripts will be prepared in accordance with the International Committee of Medical Journal Editors — uniform requirements for manuscripts submitted to Biomedical Journals *Br Med J* 1982; 284: 1766-70.

Details of instructions to authors are published in the January and July issues of the Journal.

Manuscripts submitted for publication are accepted on the understanding that they are contributed exclusively to the *The Central African Journal of Medicine*. A statement to that effect should be included in the letter accompanying the manuscript.

Communications concerning editorial matter, advertising, subscription, change of address, etc., should be addressed to the Administrative Manager, P.O. Box A 195, Avondale, Harare, Zimbabwe.

The subscription rate (including surface postage) for 1995 is Z\$140.00 per annum locally; Europe US\$110.00, Africa US\$100.00 and US\$110.00 elsewhere. The subscription rate (including airmail postage) for 1995 in Africa is US\$175.00; Europe US\$195.00 and US\$210.00 elsewhere.

Owned and published by The Central African Journal of Medicine Company in conjunction with the University of Zimbabwe Faculty of Medicine.

Neoplastic and non-neoplastic ovarian disease in Zimbabwean women

G STANCZUK

SUMMARY

Diseases of the ovary are a significant cause of morbidity and mortality amongst Zimbabwean women. There is however, scanty data regarding the types and extent of these conditions. A retrospective review of histologically diagnosed ovarian disease was carried out in order to determine the types, prevalence and age distribution of ovarian pathology seen in Harare over a 22 month period. Pathological changes were reported in 368 ovarian samples. Forty four pc of the lesions were neoplastic and of that number, 28 pc were malignant. Non-neoplastic lesions were mainly functional cysts or sequellae of inflammation.

The mean age of the patients was 32 years (range four to 78 years). Patients with non-neoplastic lesions

Registrar in Obstetrics and Gynaecology

Harare Maternity and Central Hospitals

PO Box ST 14, Southerton

Harare, Zimbabwe

Current correspondence to:

25 Lockwood Road

Birmingham B31 1PT, England

Telephone +44 121 475 2894

Fax +44 121 694 5356

were between 10 and 60 years old. Neoplastic conditions occurred throughout the age spectrum and were the only lesions seen in patients under 10 or over 60 years old.

In the hospital population reviewed, the prevalence of symptomatic non-neoplastic ovarian lesions was found to be similar to that of neoplastic ovarian tumours. Functional cysts were commonest (33 pc), white epithelial and germ cell tumours accounted for 20 pc and 14 pc respectively. Granulosa cell tumours occurred more commonly than reported elsewhere. The age distribution was remarkable in that there was a 50 pc chance of neoplastic ovarian disease occurring in patients under 20 years old.

INTRODUCTION

In Zimbabwe, diseases of the ovary are commonly diagnosed in symptomatic patients, often with advanced diseases. The management of these diseases takes up a sizable component of the gynaecological work load. Our knowledge of the types and prevalence of these diseases is nevertheless scanty. In an attempt to shed some light on the problem, samples drawn from a self referred hospital population were reviewed. Since histological confirmation of clinical diagnoses was available, a review of the histological reports was deemed the most reliable way of documenting ovarian disease in this population.

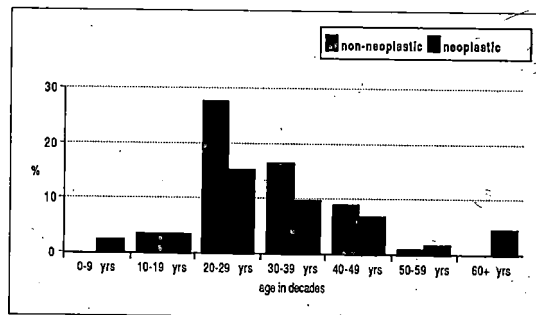
MATERIALS AND METHODS

Gynaecological surgery records for the 22 month period from 1 January 1992 to 31 October 1993 were searched for tissue samples submitted for histological examination as ovarian tissue. In order to access samples submitted by other surgical departments, the specimen receipt register of the Pathology Laboratory, Public Health Laboratories and Medical School, Harare, Zimbabwe was also searched for samples received as ovarian tissue. The searches identified a total of 382 such entries.

Specimen numbers and sample descriptions of all flagged entries were recorded anonymously. Reports were then traced through the manual filing system and the specimen numbers, age, referring centre and pathological diagnoses recorded.

The samples were then divided into non- neoplastic and neoplastic groups. Non neoplastic tumours were further subdivided into physiological enlargement

Figure 1: Age stratified distribution of all lesions encountered. Note that before the age of 10 years and after the age of 60 years all ovarian lesions were neoplastic.



(luteal and follicular cysts) and inflammatory lesions. Neoplastic changes included epithelial, germ cell, sex cord/stromal and metastatic tumours. The age was recorded in 67 pc cases, allowing the pathologic findings to be stratified by age.

RESULTS

Between January 1992 and October 1993 at least 348 ovarian tissue samples were submitted for histological examination at the Harare Public Health and Medical School Pathology Unit, Zimbabwe. The majority (81

Table 1: The types and frequency of all the pathological conditions of the ovary diagnosed in the reviewed cases.

	Number	pc
functional cysts*	122	33,0
inflammatory	71	19,0
other non-neoplastic**	13	3,5
epithelial tumours	74	20,0
germ cell tumours	52	14,0
sex cord/stromal	31	8,4
metastatic	4	1,1
anaplastic	1	0,3
Total	368	100

*Functional cysts included 70 (34 pc) luteal cysts and 52 (25 pc) follicular cysts.

**Other non-neoplastic ovarian lesions included schistosomiasis, congenital vestigial remnant and Stein Leventhal syndrome.

pc) of the patients had been operated upon at the Harare Central and Parirenyatwa Teaching Hospitals. The remaining samples were submitted from neighbouring district and provincial hospitals. The catchment population was approximately five million people.

Patients.

The samples were from a homogenous population of indigenous Zimbabwean women. Patient age was accurately recorded in 255 (67 pc) of the cases, in the remainder the age was entered only as "adult". The ages ranged from four to 78 (mean 32) years. Where the age was recorded, the relative frequency of all the conditions was then stratified by age (Figure I).

Diseases.

Pathological changes were identified in 354 (92,6 pc), the remainder being normal ovarian tissue. Dual, non neoplastic pathology was present in 4 pc of the samples. A breakdown of all the samples reviewed is shown in Table I.

Non-neoplastic: Functional cysts were the predominant non-neoplastic lesions (33 pc) (Table II). Inflammatory changes comprised 19 pc of the samples. Other changes (3,5 pc) included ovarian schistosomiasis (n = 11), congenital vestigial remnant (n = 2) and Stein-Leventhal Syndrome (n = 1).

Neoplastic: Forty four pc of all the ovarian lesions were neoplastic (Table III). The neoplastic changes were segregated into benign and malignant (Table IV). The commonest benign neoplasms were serous cystadenoma (n = 42) and cystic teratoma (n = 42). Sixteen of the 58 (27,6 pc) epithelial tumours were malignant.

Germ cell tumours were dominated by teratomata. We identified 47 teratomata, five (11 pc) were malignant, three (5 pc) were bilateral. One teratoma had the features of chorioncarcinoma (nine year old), another included a poorly differentiated squamous cell carcinoma (50 year old).

Two teenagers (both 14 years old) and a young adult (age 24), had malignant endodermal sinus tumours. Granulosa cell tumours were the commonest sex cord derived malignancy. The ovary was the site of metastasis in four (1 pc) cases.

Age stratification of the diseases.

Neoplastic changes were the singular diagnoses in patients under the age of 10 or over 60 years (Figure I). In the intervening ages, both neoplastic and non-neoplastic lesions occurred. Epithelial tumours constituted

Table II: Distribution of surgically excised non-neoplastic ovarian lesions.

	Number	pc
Functional cysts	122	59,0
inflammatory	71	34,0
other non-neoplastic	13	6,3
Total	206	100

Table III: Distribution of types of neoplastic tumours of the ovary.

	Number	pc
epithelial tumours	74	46,00
germ cell tumours	52	32,00
sex cord/stromal	31	19,00
metastatic	4	2,50
anoplastic	1	0,06
Total	162	100

Table IV: Types of benign and malignant neoplasms of the ovary. Metastatic lesions were few.

Tumour type	benign	malignant
epithelial		
serous	42	11
mucinous	8	3
endometrioid	7	2
Brenner	1	-
germ cell		
teratoma	42	5
yolk sac/dysgerminoma	-	5
sex cord/stromal		
thecoma/triboma	14	-
granulosa cell	-	9
sertoli/leydig	-	3
leiomyoma	3	-
gynandroblastoma	-	2
metastasis	-	4
anaplastic	-	1
Total	117 (72 pc)	45 (28 pc)

a third of all lesions. These were not diagnosed in patients under 20 years old. With the exception of one case of borderline serous adenocarcinoma, all epithelial tumours seen in patients aged between 20 and 40 years were benign. Beyond the age of 40 years, 73 pc of the epithelial tumours were malignant. Germ cell derived tumours, like sex cord/stromal tumours occurred in every age group. More than half the germ cell tumours (57 pc) occurred in patients aged 20 to 39 years. The youngest patient (four year old), had a benign teratoma.

DISCUSSION

We reviewed ovarian pathology in otherwise unselected, symptomatic population. Neoplastic and non-neoplastic conditions are almost equally frequent. With the former predominantly occurring in patients outside the child bearing age brackets.

Teenage patients (11 to 20 years) were, in this review shown to have a 50 pc chance of having neoplastic tumours of the ovary. Women aged over 40 years were more likely to have neoplastic ovarian tumours. After the age of 60 years all the neoplastic tumours were malignant. Like the teenage patients, post menopausal women, in our setting, tend to seek medical advice late in the disease process.

Functional cysts, which do not necessarily require surgical treatment, were the largest group of ovarian diseases (33 pc). In this review we have shown, that there is a 50 pc chance of an ovarian cyst being neoplastic. We are persuaded that a good case can be made for surgeons to perform oophorectomy if in any doubt.

A fifth of all specimens were epithelial tumours. These are the most commonly occurring ovarian carcinomas,^{1,2} with an incidence close to that of ovarian cancer in general.³ Ten of 16 malignant epithelial tumours in our material were of low malignancy potential/borderline epithelial tumours. We, like others,⁴ clasified these tumours as malignant, because despite histological appearances, their clinical behaviour resembled that of invasive disease.

In germ cell tumours, 32 pc of neoplastic changes were mainly teratomata. In some series they are the most common ovarian neoplasia,⁵⁻⁷ Walker *et al*⁸ observed that malignant teratomata in the female occurred on average 10 to 15 years earlier than benign teratomata. We did not observe such an age disparity.

Benign teratomata are often diagnosed incidentally in asymptomatic patients.^{6,8} All our patients, being self referred were symptomatic. Given the recognised high incidence of asymptomatic disease, it is likely that our figures underestimate the incidence of germ cell tumours in our population.

Sex cord/stromal tumours accounted for 18 pc of neoplasms, with a high incidence of granulosa cell tumours. In other series, the incidence of granulosa cell tumour ranges from 1,6 to 3 pc of all ovarian tumours and about 10 pc of ovarian cancers.⁹ This material included nine cases of pure granulosa cell tumour and two of gynandroblastoma with a predominant granulosa cell component.

All the patients with this condition were either under 25 or over 49 years old. Granulosa cell tumour was responsible for 5,5 pc of all neoplasms, and 20 pc of malignant tumours. The reasons for this high incidence in our series is unclear.

Metastatic tumours were detected in four cases. Three of the metastases were adenocarcinomata from the gastro-intestinal tract, the other was a squamous cell carcinoma of the uterine cervix. This small number of metastatic lesions may reflect the fact that patients who present with obvious advanced, metastatic disease may be inoperable. Even when operable, oophorectomy may not be indicated.

ACKNOWLEDGEMENTS

We wish to acknowledge, with thanks, the contribution of consultants, registrars and technical staff of the Medical School and Public Health laboratory services (headed by Drs NJ Gwavava and C Muronda respectively) in the processing and reporting of the clinical samples reviewed in this paper. Dr Chipato of the Department of Obstetrics and Gynaecology is thanked for encouraging the concept of this review and finally Dr EN Sibanda is thanked for his assistance in the preparation of the script.

REFERENCES

1. Wynder EL, Dodo H, Barber HRK. Epidemiology of cancer of the ovary. *Cancer* 1969;23:352-69.
2. Grech ES, Lewis MG. Ovarian tumours in Ugandan Africans. *E Afr Med J* 1967;44:487-92.
3. Heintz AP, Hacker NF, Lagasse LD. Epidemiology and etiology of ovarian cancer: a review. *Obstet Gynaecol* 1985;66:127-35.

CENTRAL AFRICAN
JOURNAL OF MEDICINE

4. Massad LS, Hunter VJ, *et al.* Epithelial ovarian tumours of low malignant potential. *Obstet Gynaecol* 1991;78:1027-32.
5. Beck PR, Latour JPA. A review of 1 019 benign ovarian neoplasms. *Obstet Gynaecol* 1960;14:470-82.
6. Westhoff C, Pike M, Vessey M. Benign ovarian teratomata: a population based case control study. *Br J Cancer* 1988;74:93-8.
7. Koonings PP, Campbell K, Mishell DR, Grimes DA. Relative frequency of primary ovarian neoplasms: a 10 year review. *Obstet Gynaecol* 1989;74:921-6
8. Walker A, Ross R, Pike M, Henderson B. A possible rising incidence of malignant germ cell tumours in young women. *Br J Cancer* 1984;49:669.
9. Willemsen W, Kruitwagen R, Bastiaans B, Hanselaar T, Rolland R. Ovarian stimulation and granulosa-cell tumour. *Lancet* 1993;341:986-8.



This work is licensed under a
Creative Commons
Attribution – NonCommercial - NoDerivs 3.0 License.

To view a copy of the license please see:
<http://creativecommons.org/licenses/by-nc-nd/3.0/>

This is a download from the BLDS Digital Library on OpenDocs
<http://opendocs.ids.ac.uk/opendocs/>