

## Case Report

# Impar Ganglion Block with Combination of Neurolysis Drugs and Radiofrequency Thermocoagulation for Perineal Pain

### Abstract

Since it was first introduced, a variety of modification techniques to block the impar ganglion appear such as transsacrococcygeal ligament technique, sacrococcygeal transdiscal approach, paramedian approach, and a two-needle technique using fluoroscopy or computed tomography scan. For therapeutic purposes, a combination of steroid and local anesthetic, neurolysis agents such as alcohol, phenol, cryolesioning, and heat lesioning using radiofrequency thermocoagulation could be used. Here, we reported a successful outcome in treating chronic perineal pain in a 65-year-old patient using combination of neurolysis agent which was alcohol 96% and radiofrequency thermocoagulation.

**Keywords:** Alcohol 96%, impar ganglion blocks, neurolysis, radiofrequency thermocoagulation

### Introduction

Impar ganglion (or commonly also referred to as ganglion Walther or sacrococcygeal ganglion) is the most caudal ganglion of the sympathetic ganglionic chain. Visceral afferent fibers originated from the perineum, distal rectum, anus, distal section of urethra, vulva, and vagina meet at the distal third of this ganglion. Impar ganglion marks the end of two sympathetic chains, in the form of a single ganglion which is a fusion of both ganglia of the two sides of the sympathetic chain. Therefore, this ganglion is usually located in the midline area but can also be located more laterally from the midline [Figure 1]. Anatomical studies indicate that this structure may be located up to 2 cm of sacrococcygeal joints.<sup>[1]</sup>

Report on the impar ganglion block to reduce perineal pain was documented for the first time in 1990.<sup>[2]</sup> Since its inception, various modifications of techniques to block ganglion impar ligament appear such as transsacrococcygeal technique, sacrococcygeal transdiscal approach, paramedian approach, and a two-needle technique using fluoroscopy or computed tomography scan have been performed. For therapeutic purposes, a combination of both steroid and local anesthetic, neurolysis agents such as phenol, cryolesioning, and

radiofrequency thermocoagulation could be used.<sup>[3]</sup>

Impar ganglion block is useful for the management and evaluation of pain mediated by sympathetic fibers of the perineum, rectum, and genitalia. Visceral pain or pain that is mediated by the sympathetic fibers in the perineal area associated with malignancy in the pelvis may be effectively treated with neurolysis of impar ganglion. Theoretically, this procedure could also be applied for nonmalignancy pain such as pain associated with endometriosis, complex regional pain syndrome, prostate pain, enteritis pain due to radiation, postherpetic neuralgia.<sup>[3]</sup> This procedure also had been reported successfully in treating excessive sweating disorders in the perineum, pain in the rectal area due to cramps, and coccydynia.<sup>[4-6]</sup> The use of percutaneous radiofrequency thermocoagulation for ablation of the sympathetic chain in intractable pain in the sacral-pelvic areas or for the management of visceral pain or complex regional pain syndrome differs from the use on the other targets such as the sensory nerve tissue because there is no limit on the acquired sensory sympathetic innervation.<sup>[7]</sup> Because of this reason and a wide variety of anatomical location of impar ganglion, we used a combination of radiofrequency thermocoagulation and neurolysis agent (alcohol 96%) carefully to increase the pain control effects.

**Agus Turchan,  
Achmad Fahmi,  
Heri Subianto**

*Department of Neurosurgery,  
Division of Stereotactic and  
Functional Neurosurgery,  
Faculty of Medicine, Airlangga  
University/Dr. Soetomo General  
Hospital, Surabaya, Indonesia*

### Address for correspondence:

*Dr. Heri Subianto,  
Department of Neurosurgery,  
Division of Stereotactic and  
Functional Neurosurgery,  
Faculty of Medicine, Airlangga  
University/Dr. Soetomo  
General Hospital, Gedung  
GDC Lantai 5, Jalan Prof.  
Dr. Moestopo 6-8 Surabaya,  
Indonesia.  
E-mail: heri.subianto@  
yahoo.com*

### Access this article online

**Website:** [www.asianjns.org](http://www.asianjns.org)

**DOI:** 10.4103/ajns.AJNS\_306\_16

### Quick Response Code:



**How to cite this article:** Turchan A, Fahmi A, Subianto H. Impar ganglion block with combination of neurolysis drugs and radiofrequency thermocoagulation for perineal pain. *Asian J Neurosurg* 2018;13:838-41.

This is an open access journal, and articles are distributed under the terms of the Creative Commons Attribution-NonCommercial-ShareAlike 4.0 License, which allows others to remix, tweak, and build upon the work non-commercially, as long as appropriate credit is given and the new creations are licensed under the identical terms.

**For reprints contact:** [reprints@medknow.com](mailto:reprints@medknow.com)

The purpose of this case report is to present a patient with chronic perineal pain (CPP) that did not improve with antipain medication but could be controlled after had been given impar ganglion block using alcohol 96% combined with radiofrequency thermocoagulation.

### Case Report

A 65-year-old female came to our clinic with a complaint of burning pain sensation in the perineal region. Pain in the perineal region increased progressively despite treatment with a combination of codeine, paracetamol, and tramadol. The pain did not radiate, no interference in defecation and urination. The patient had a history of backward fall, 1 year earlier. The pain sensation became worse despite the drugs combination added with pregabalin 300 mg/day. Her Visual Analog Score (VAS) score was 8–9. Daily activities were hampered because of the pain. Magnetic resonance imaging examination T2 sequence showed hypointense around the sacrococcygeal joint, suggestive of inflammation of the sacrococcygeal area, indicative of coccygeal hypermobility [Figure 2].

### Method

The patient was planned to be given impar ganglion block with neurolysis agent (alcohol 96%) in combination with radiofrequency thermocoagulation. The patient had been explained about the consent before the procedure and to be enrolled and have her data published. This study had also been approved by our institution for publication. Briefly, in the operating room, the patient was kept in a prone position; hemodynamic monitoring and sterilization were conducted at sacrococcygeal area and covered with sterile operating towel. A local anesthetic injection was performed with 2% lidocaine at sacrococcygeal joints, followed by a 22-gauge RF cannula needle insertion (100 mm, with 5 mm active tip, Cosman Medical, Inc., Burlington, USA) transdiscal, up to the retroperitoneal area at the anterior of sacrum under guidance of a C-arm. Two milliliters of iopamiro contrast agent was injected to ensure that the needle has entered in the retroperitoneum, anterior of sacrum; this was confirmed with C-arm at lateral view [Figure 3]. Radiofrequency electrode was inserted (TCD-10P, Cosman Medical, Inc., Burlington, USA) into the needle cannula. The electrodes were connected to the radiofrequency generator (Cosman G4, V2 RF Generator, Cosman Medical, Inc., Burlington, USA) showing the measured impedance of 320 Ohm. Sensory (50 Hz) and motor (2 Hz) stimulation were conducted, and they showed negative results. The thermocoagulation was performed for 90 s at 80°C. There were no complaints of heavy or spreading pain during and after the procedure. Vital signs were stable, no complications arised. Neurolysis was performed after thermocoagulation with a mixture of 2.5 mL of alcohol 96% and 0.25% bupivacaine.

One hour after the thermocoagulation procedure, the VAS score was 2–3, which showed significant pain reduction. Patient discharged on the same day. One week after

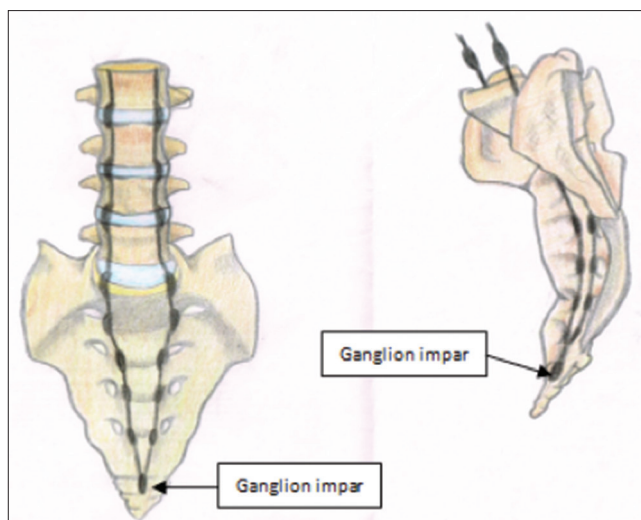


Figure 1: Anatomic location of impar ganglion

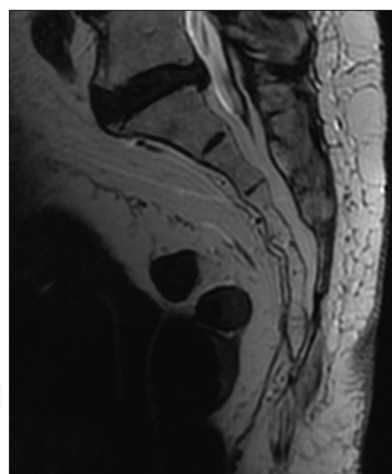


Figure 2: Magnetic resonance imaging T2 sequence shows hypointense around sacrococcygeal area, suggestive of inflammation and hypermobility

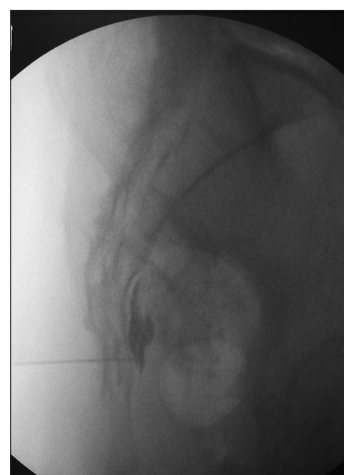

Figure 3: Fluoroscopy showed contrast injection at the retroperitoneal area

treatment, the patient came to our clinic again, and VAS score was 1–2. She resumed her normal daily activities, without taking any oral analgesics or opioids.

## Discussion

Perineal pain is a common problem, especially in women, with ratio “2:1” which produces a high degree of functional and emotional impairment as well as challenge for doctor. Manifestations can be either acute or chronic. CPP is a pain syndrome accompanied by somatic or sympathetic component. A proper history and physical examination can be useful tools to describe the sympathetic or somatic components of CPP. Perineal pain pathways mediated by sympathetic nerve (sympathetically mediated perineal pain) is a type of pain that does not have any particular location, yet a sensation of burning and urgency in the perineal area.<sup>[8]</sup>

Due to the variation of the anatomical location of impar ganglion, the success rate of impar ganglion block varies widely. Various techniques and drugs ranging from neurolysis, botulinum toxin to radiofrequency are used to perform impar ganglion block. Plancarte *et al.* were the first to perform impar ganglion block in 16 patients with localized perineal pain associated with cancer. After ganglion block, eight patients reported complete recovery, and the rest reported decreased pain sensation between 60% and 90%. Two patients received impar ganglion block procedures more than two times, and there were improvement of pain sensation. Follow-up varied from 14 to 120 days depending on the patient's survival.<sup>[2]</sup> Toshniwal *et al.* performed impar ganglion block in 16 patients with chronic pelvic pain due to cancer. They performed transsacrococcygeal technique with a 22-gauge needle. Neurolysis block was performed with phenol and therapeutic blocks with a combination of methylprednisolone and bupivacaine. A significant reduction of pain over 50% in the follow-up period of 8 weeks was found.<sup>[4]</sup> Malec-Milewska *et al.* performed neurolysis on the impar ganglion using 65% alcohol and lidocaine in nine patients with chronic pelvic pain due to cancer. A total of 16 neurolysis blocks resulted in a significant reduction in pain.<sup>[9]</sup>

Radiofrequency thermocoagulation of the impar ganglion has also been reported to decrease coccydynia pain in patients who did not respond to conservative treatment. Demircay *et al.* performed radiofrequency thermocoagulation for chronic coccydynia with the follow-up of 6 months and obtained satisfactory results in 90% of patients.<sup>[10]</sup> Gurses used impar ganglion percutaneous radiofrequency thermocoagulation in patients with a history of colon cancer with perineal pain, especially during defecation. There were decreasing pain sensation and reduction of antipain medication that had consumed by patients to only tramadol 200 mg/day at 4-week follow-up.<sup>[11]</sup> Lim *et al.* used botulinum toxin Type A to do impar ganglion block in patients with CPP which reappeared despite had been given neurolysis and radiofrequency. Follow-up for 13 months with three times ganglion impar block procedures with botulinum toxin Type A showed reduction in pain with VAS of 2/10.<sup>[12]</sup>

The spread of alcohol and phenol, which are generally used for neurolysis, cannot be accurately predicted. Therefore, those agents cannot block the nerves selectively. Furthermore, alcohols and phenols have been reported to induce novel pain.<sup>[13]</sup> In cases where the thermocoagulation radiofrequency ablation technique are used, special equipment such as electrostimulating tools and minute controller are required. Therefore, it may be possible to do the destruction of nerve fibers selectively. The possibility of complication is lower. The size and location of the lesion can be controlled. Among various methods for impar ganglion blocks, thermocoagulation radiofrequency ablation techniques are the best technique.<sup>[14]</sup>

Impar ganglion block with transsacrococcygeal technique is an easy and safe technique. This technique allows neurolysis or radiofrequency thermocoagulation ablation of the impar ganglion and can be used for diagnostic blocks, especially when the diagnosis and subsequent management plan depends on the response to the diagnostic blocks.<sup>[4]</sup>

We performed impar ganglion block in patient with CPP with neurolysis drugs and radiofrequency thermocoagulation through transsacrococcygeal approach. The existence of a wide variety of anatomical locations of impar ganglion and the nature and effectiveness of the neurolysis drugs and radiofrequency actions are put into consideration during procedure selection. The combination of impar ganglion block with neurolysis drugs (alcohol 96%) and radiofrequency thermocoagulation increases the success rate and reduces the frequency of repetition of the intervention procedure.

## Conclusion

Impar ganglion block with neurolysis drugs combined with radiofrequency thermocoagulation in cases of CPP may be a therapeutic option. This combination reduce the frequency of repetition of the procedure, a longer pain-free period and safe for the patient. For optimal effectiveness of this procedure, further research is required with more patients.

## Acknowledgment

The authors gratefully acknowledge Dr. Ema Shofiana Azkia for supplying the illustrative image used in this case report.

## Financial support and sponsorship

Nil.

## Conflicts of interest

There are no conflicts of interest.

## References

1. Oh CS, Chung IH, Ji HJ, Yoon DM. Clinical implications of topographic anatomy on the ganglion impar. *Anesthesiology* 2004;101:249-50.

2. Plancarte R, Amescua C, Patt RB, Allende S. Presacral blockade of the ganglion of Walther (ganglion impar). *Anesthesiology* 1990;73:A751.
3. Erdine S, Ozyakin S. Pelvic sympathetic blocks: Ganglion of impar block. In: Raj PP, editor. *Interventional Pain Management: Image-Guided Procedures*. 2<sup>nd</sup> ed. Philadelphia: Saunders; 2008. p. 400-4.
4. Toshniwal GR, Dureja GP, Prashanth SM. Transsacrococcygeal approach to ganglion impar block for management of chronic perineal pain: A prospective observational study. *Pain Physician* 2007;10:661-6.
5. Lee HK, Yang SK, Lee HJ, Lee SY, Kim SM, Kim BS, *et al.* The effect of ganglion impar block for excessive perianal sweating. *Korean J Pain* 1995;8:363-6.
6. Kim SK, Ahn CS, Cho YR, Lim SY, Shin KM, Hong SY, *et al.* Ganglion impar block in the management of rectal tenesmoid pain. *Korean J Pain* 1996;9:226-8.
7. Van Zundert J, Sluijter M, van Kleef M. Thermal and pulsed radiofrequency. In: Raj PP, editor. *Interventional Pain Management: Image-Guided Procedures*. 2<sup>nd</sup> ed. Philadelphia: Saunders; 2008. p. 56-65.
8. Wallace MS, Leung AY, McBeth MD. Malignant pain. In: Raj PP, editor. *Textbook of Regional Anesthesia*. Pennsylvania: Churchill Livingstone Publishers; 2002. p. 585.
9. Malec-Milewska M, Horosz B, Koleda I, Sekowska A, Kucia H, Kosson D, *et al.* Neurolytic block of ganglion of Walther for the management of chronic pelvic pain. *Wideochir Inne Tech Maloinwazyjne* 2014;9:458-62.
10. Demircay E, Kabatas S, Cansever T, Yilmaz C, Tuncay C, Altinors N. Radiofrequency thermocoagulation of ganglion impar in the management of coccydynia: Preliminary results. *Turk Neurosurg* 2010;20:328-33.
11. Gürses E. Impar ganglion radiofrequency application in successful management of oncologic perineal pain. *J Pak Med Assoc* 2014;64:697-9.
12. Lim SJ, Park HJ, Lee SH, Moon DE. Ganglion impar block with botulinum toxin type A for chronic perineal pain – A case report. *Korean J Pain* 2010;23:65-9.
13. Mailis A, Furlan A. Sympathectomy for neuropathic pain. *Cochrane Database Syst Rev* 2003;(2):CD002918.
14. Reig E, Abejón D, del Pozo C, Insausti J, Contreras R. Thermocoagulation of the ganglion impar or ganglion of Walther: Description of a modified approach. Preliminary results in chronic, nononcological pain. *Pain Pract* 2005;5:103-10.

