

PROCEEDINGS OF SPIE

SPIDigitalLibrary.org/conference-proceedings-of-spie

Analysis of visual search behaviour from experienced radiologists interpreting digital breast tomosynthesis (DBT) images: a pilot study

Leng Dong, Qiang Tang, Alastair Gale, Daniella Bernardi, Yan Chen

Leng Dong, Qiang Tang, Alastair Gale, Daniella Bernardi, Yan Chen, "Analysis of visual search behaviour from experienced radiologists interpreting digital breast tomosynthesis (DBT) images: a pilot study," Proc. SPIE 10577, Medical Imaging 2018: Image Perception, Observer Performance, and Technology Assessment, 1057707 (19 March 2018); doi: 10.1117/12.2293615

SPIE.

Event: SPIE Medical Imaging, 2018, Houston, Texas, United States

Analysis of visual search behaviour from experienced radiologists interpreting digital breast tomosynthesis (DBT) images: a pilot study

Leng Dong^a, Qiang Tang^a, Alastair Gale^a, Daniela Bernardi^b, Yan Chen^{a*}

^aApplied Vision Research Centre, Loughborough University, UK

^bDepartment of Radiology, Trento Hospital, Italy

ABSTRACT

Digital Breast Tomosynthesis has several advantages over traditional 2D mammography. However, the cost-effectiveness to implement DBT modality into breast screening programmes is still under investigation. The DBT modality has been integrated into a regional breast screening program in Italy for several years. The purpose of this study is to examine the experienced Italian DBT readers' visual search behaviour and summarise their visual inspection patterns. Seven experienced radiologists took part in the study, reading a set of DBT cases with a mixture of both normal and abnormal cases whilst their eye movements data were recorded. They read the cases through a fixed procedure starting with a 2D overview and then went through the DBT view of each side of the breasts. It was found that the experienced readers tended to perform a global-focal scan over the 2D view to detect the abnormality and then 'drilled' through the DBT slices, interpreting the details of the feature. The reading speed was also investigated to see if there was any difference in length of time when expert radiologists examine both normal and abnormal cases. The results showed that there was no significant difference in time between normal and abnormal cases. The eye movement patterns revealed that experienced DBT readers covered more areas on the 2D view and fixated longer and with more dwells inside the AOI in the 3D view. Based on these findings it is hoped that by understanding the visual search patterns of the experienced DBT radiologists, it could potentially help DBT trainees to develop more efficient interpretation approaches.

1. INTRODUCTION

Digital Breast Tomosynthesis (DBT) has been proven to be superior to 2D mammography in many respects. However, it is still under investigation whether it is cost-effective to implement DBT into breast screening programmes. It was reported by previous studies that the DBT reading time is normally twice as long as reading traditional 2D mammography (Skaane, et al., 2013). Although DBT takes longer to interpret, and so is a disadvantage to its implementation in a screening programme, a great advantage of its use is that fewer women are subsequently recalled for assessment which is a distinct advantage. DBT screening has been successfully implemented in Italy as a primary imaging modality in 2015 since the expected benefits were clinically validated from the results of STORM and STORM 2 trials (Ciatto, et al., 2013; Bernardi, et al., 2014). These Italian radiologists have taken part in the regional breast screening programme and managed to cope with the workload and deliver reliable diagnostic accuracy at the same time.

Examination of the visual search behaviour from such experienced DBT screening radiologists may then reveal insight into the most effective DBT interpretation strategy and so help formulate plans to aid DBT trainees improve their image inspection skills. In this study, seven experienced DBT radiologists from the Italian screening programme were invited to take part in an observer performance study while their visual search behaviour data were collected and analysed to explore the potential for an optimized DBT interpretation pattern.

2. METHOD

Participants

Trento hospital had started routine DBT screening in 2015. The seven radiologist observers had an average of 13 years' experience reading FFDM cases (minimum of seven years) and an average of seven years' experience with DBT screening (minimum of two years). The estimated numbers of DBT screening cases read every month by these radiologists varied from 600 to 2,000 cases per month. Their typical DBT reading session was 4 hours long with breaks of every 30 minutes. The overall reading speed is about 20-25 cases in 30 minutes. The radiologists were recruited from Trento Hospital in Italy

* y.chen@lboro.ac.uk

and they all signed participation consent forms before taking part. The experimental ethical process and risk assessment were approved by Loughborough University.

Experimental Design

40 digital breast tomosynthesis cases with a mixture of 18 normal cases, 5 benign cases and 17 malignant cases were collected as a training case set. All the cases had prior images and consisted of both 2D (FFDM) or C-view (synthetic 2D views) together with DBT images. The case set was pre-loaded onto the Hologic DBT workstation. The 40 cases were divided into two sets of 20 DBT cases and shuffled to provide a random order for each participant. The participants took breaks between the two sessions. Before the participants started examining the cases, they were briefed with a participant's information sheet informing them that they were going to be presented with a set of DBT cases and that the task was detect any abnormal lesions and report the details of such mammographic features.

A Smart Eye remote eye tracker was positioned underneath the DBT workstation to record the participants eye movements which mapped the observer's x and y eye fixation positions according to the workstation monitor co-ordinate system at a sample rate of 120Hz. A scene camera was additionally fixed on top of the monitor to track the participants' hand movements during the experiment (Figure 1 Left). For each participant the eye tracking system was first calibrated through a fast 4-point calibration process.

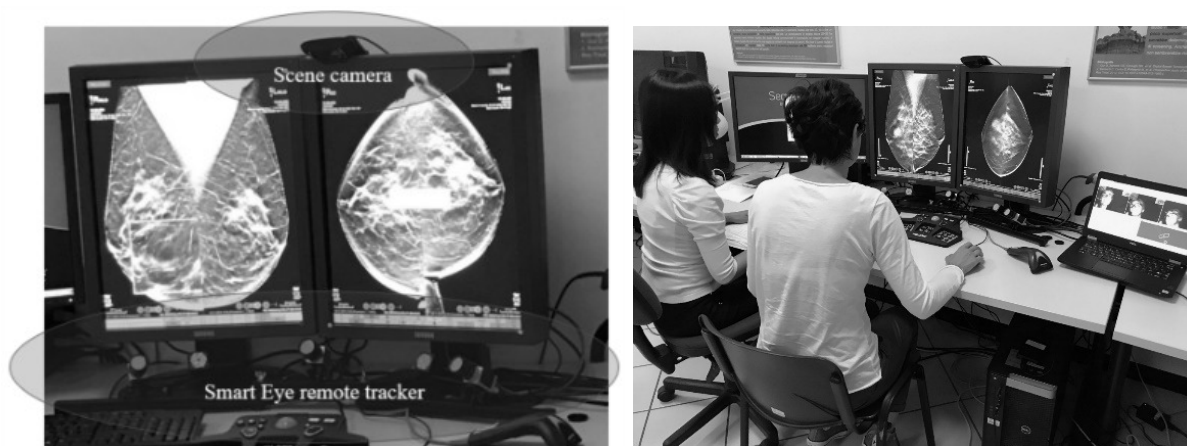


Figure 1 Left: Set up of eye tracking devices on the dual screen mammography workstation. Right: The participant is reading a DBT case while her eye movement data are collected.

Participants read the DBT cases on a Hologic SecurView DX workstation which consisted of dual 5MP LCD monitors. The workflow of the DBT reading procedure was pre-set as the same as what was used during the Italian screening programme which permitted participants to read the 2D/C-view first with prior images and then examine each breast with the DBT view. Two training cases were also provided to help the participants become familiar with the experimental set up. During the examination process, they were instructed that they should examine cases as they usually did during the screening process except that when they made any decision, they needed to report the results verbally, when one of the experimental investigators recorded their decisions by marking the relevant results on reporting sheets.

The participants were asked to give each case a rating, based on 5-point confidence level: Normal, Benign, Indeterminate, Suspicious and Highly suspicious. Also, they needed to report the location of any abnormality and specify various types of features (well defined mass, ill Defined mass, spiculate mass, architectural distortion, asymmetry, suspicious calcification, benign calcification or other features). After each participant finished the test, they were asked to fill in a questionnaire requesting brief information about their years of experience of reading DBT images, how many DBT cases they read per month and any issues about the specific cases they had just examined.

The data analysis was planned to examine the participants' reading speed, scrolling behaviour and their eye movement patterns. An initial task was to define an area of interest (AOI) around any abnormal feature in those cases where there was an abnormality. Due to the dynamic nature of the DBT cases, which means participants were performing the perception task over a stack of breast slices instead of examining a static 2D image, the Area of Interest (AOI) needed to be defined dynamically. This was achieved by first identifying the key recorded video frames, which showed the abnormality and the participants' fixation locations, and then defining these key frames of the recorded eye movement data using the

MAPPS eye tracking analytics software. For instance, the radiologist may have shown in-depth scrolling behaviour with the inspected feature being magnified on the workstation (Figure 2). In this case, the dynamic AOI would be defined by drawing AOIs right before and after the key frames when the magnifying function was triggered.

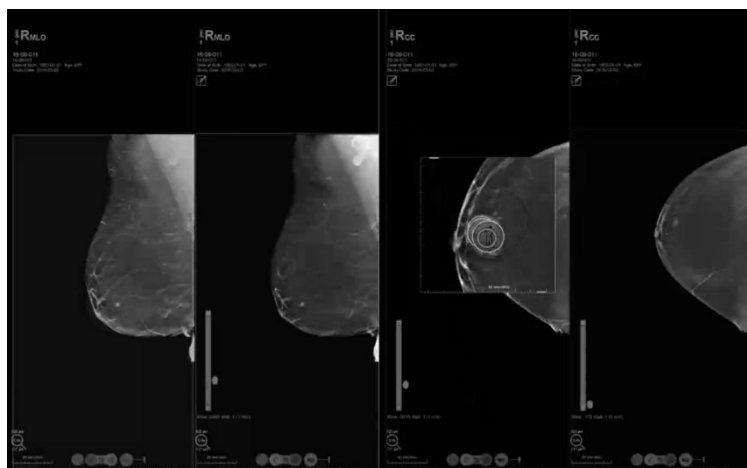


Figure 2 Dynamic AOI defined on the magnified view on the DBT slice

3. RESULTS

Results showed that, excluding any reporting time, an average of 65 seconds of reading time was spent on each case across all seven participants. On average, they spent 14 seconds reading the initial 2D overview and then 51 seconds examining the DBT view (Figure 3A). The reading time was significantly longer for examining DBT than the 2D view ($p=0.001$). When comparing the reading time between normal and abnormal cases, the participants spent slightly less time reading a normal case (63s) than an abnormal case (67s) as shown in Figure 3B. However, this result is not significant ($p=0.53$). Additionally, little difference was spotted in the reading time for the 2D overview between normal (15s) and abnormal cases (13s, $p=0.1335$) and also for the DBT view (normal: 48s; abnormal: 54s, $p=0.3411$).

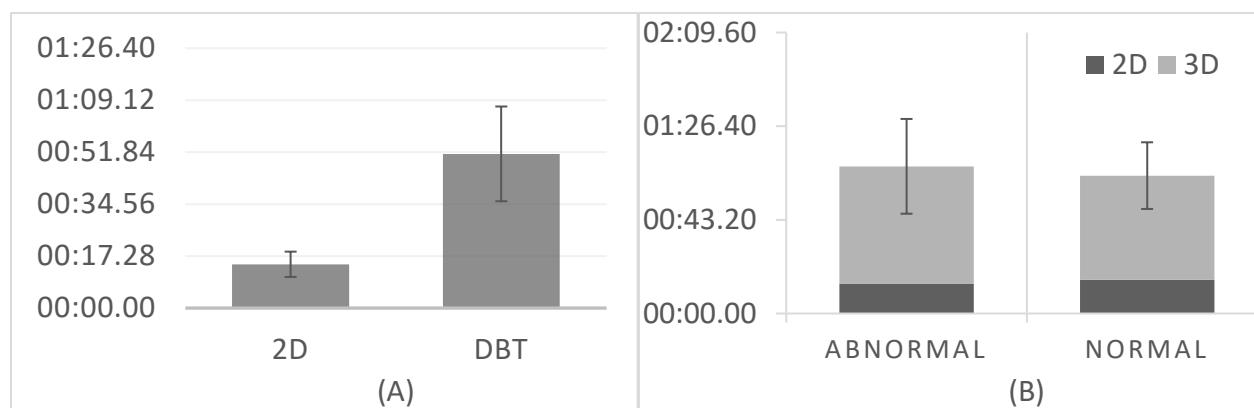


Figure 3 Comparison of reading time between 2D and 3D view, abnormal and normal cases

The participants read the cases as an initial 2D overview followed by DBT views. The working flow of the DBT examination consists of a comprehensive hanging protocol of each breast with the following order (left to right as viewed by the participant) of the breast images: 2D-MLO/DBT-MLO/DBT-CC/2D-CC. These are shown in figure 4. Figure 4 shows a sample case with a pathology proven malignant lesion on the right side of the breast which is marked by highlighted circles on the different views. The participant's eye movements are overlaid with lines depicting the participant's gaze trail (saccadic eye movements) and the heat map with brighter areas represents image areas which received longer visual attention (eye fixations). It can be seen that this participant tended to perform an overall scanning over the 2D overview and managed to locate the abnormality area (Figure 4.a). Participants' eye movements then switched to the DBT view to examine the details of the abnormality on the right side of the breast (Figure 4.b). Moreover, on the

left breast, which does not have a malignant lesion, the participant also visually examined large areas to determine if any suspicious abnormality exists (Figure 4.c).

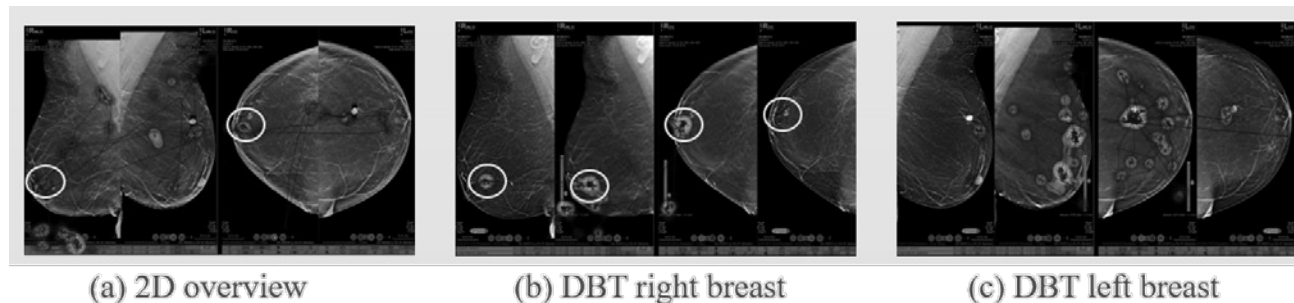


Figure 4 Visualization of eye tracking data overlaying on a sample case with pathology known lesion on the right side of the breast (marked by highlighted circle)

Figure 5 shows a sample normal case which one of the participants also spent more than one-minute examining. It can be seen that even though no known abnormality existed on this normal case, the participant still carefully examined large areas of the breasts before finally deciding not to recall this case.

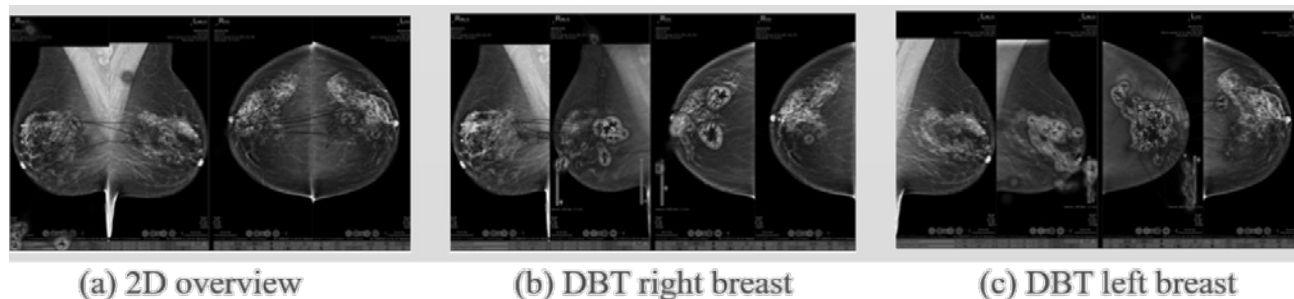


Figure 5 Visualization of eye tracking data overlaying on a normal case

As the screen content was captured at the same time as when the participant was examining the DBT cases, the DBT slice scrolling behaviour was extracted in order to inspect the relationship between the visually examined slices and the actual abnormality ‘thickness’ range over the slices. Figure 6 demonstrates the behaviour of DBT slice scrolling over the case reading time for an example case. The dashed line shows the known abnormality boundary within the total case slice range. The shadowed areas depict the period of time when a particular view was visually examined. It can be seen that after the abnormality range was scrolled through for the first time, the participant spent most of the time examining within the range of the abnormality boundaries.

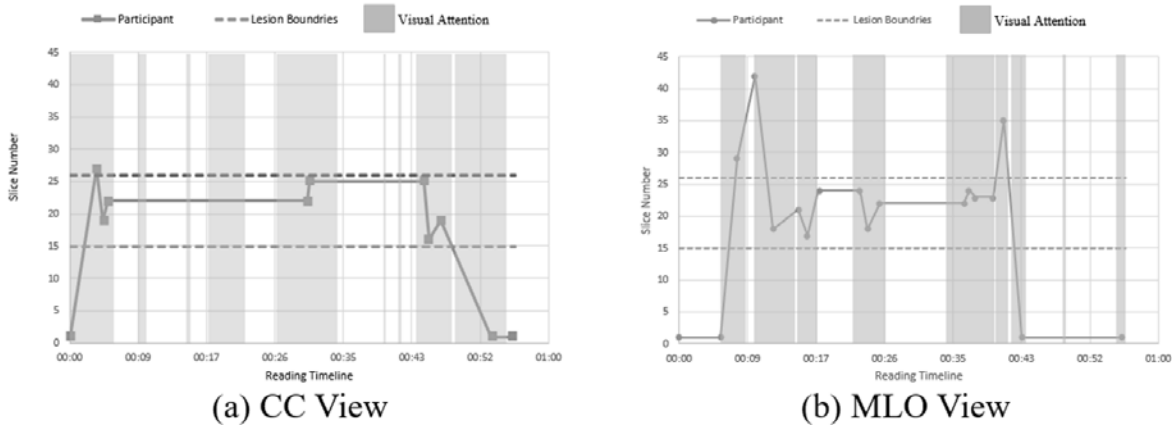


Figure 6 Participant's slice scrolling behaviour over reading time when a case with a lesion range of slices 15-26 was examined.

To further examine any differences in the visual search behaviour between 2D and DBT reading behaviour, the eye movement data with the dynamic AOI information were analysed together. Several eye movement measurements were investigated to examine how best to summarise the visual search patterns.

Figure 7 shows an example from one of the participants, recorded on another occasion undertaking a similar task, who spent longer time on the 3D views (86.47%) than the 2D views (13.53%) (Figure 7.a). For each case, the participant switched an average of 3.75 times between 2D and 3D views and 2.25 times between MLO and CC views (Figure 7. b). The abnormality area of interest (AOI) analysis shows that for the 2D views, the participant spent an average of 6.6% of their time inspecting inside the AOIs with 93.4% of the time examining areas outside the AOIs. In contrast, for the DBT views, the participant spent an average of 68.5% of time inside the AOIs compared to 31.5% outside the AOIs (Figure 7. c).

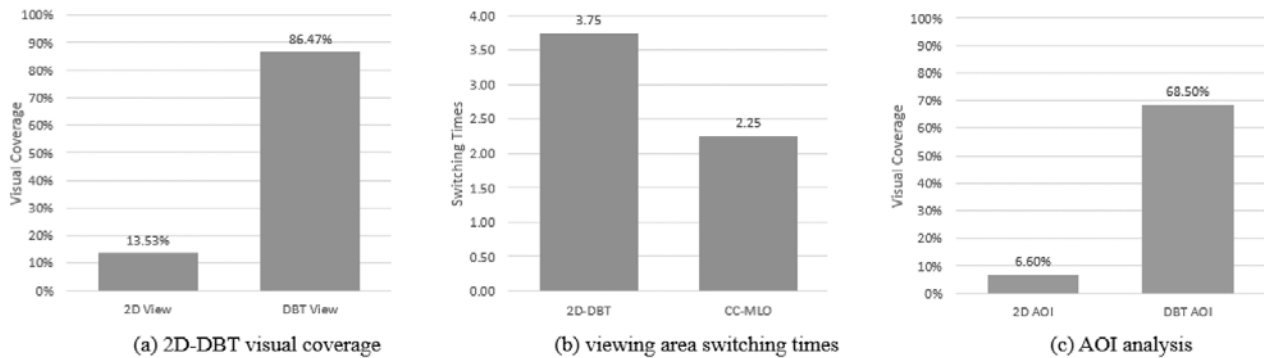


Figure 7 Eye movement parameters analyses

4. CONCLUSIONS

How to reduce the examination time is one of the key challenges to successful implementation of DBT into a breast screening programme. Given that in breast screening, most cases are normal with a very few abnormal cases worthy of recall for assessment it was anticipated that a faster reading speed on normal images would be found by these DBT experienced readers. If so, then it could be argued that this would act in favour of the use of DBT in screening. However, the results in this study did not show much significance. When the case reporting time was excluded from the case inspection time, then a similar image inspection time was found, irrespective of whether a case was normal or abnormal. More detailed examination of the visual search patterns reveals that the experienced radiologists tended to visually scan the 2D view to locate potential suspicious areas and then used the DBT view to examine these particular image sites in detail. This finding may help DBT trainees to learn a more effective reading strategy.

This pilot study examined several approaches to both visualize and analyze DBT interpretation behavior by experienced DBT radiologists. More analyses of these data are currently ongoing to determine the most worthwhile, and semi-automatic, data examination processes as a major UK study into DBT usage in screening is currently also underway in which the visual search behavior of many radiologists will be recorded and analysed.

5. ACKNOWLEDGEMENT

This work was supported by Hologic. The views expressed here are those of the authors. We are grateful to the radiologists who took part in the studies.

REFERENCE

- [1] Skaane, P., Bandos, A. I., Gullien, R., Eben, E. B., Ekseth, U., Haakenaasen, U., & Niklason, L. T. (2013). Comparison of digital mammography alone and digital mammography plus tomosynthesis in a population-based screening program. *Radiology*, 267(1), 47-56.
- [2] Ciatto, S., Houssami, N., Bernardi, D., Caumo, F., Pellegrini, M., Brunelli, S., ... & Montemezzi, S. (2013). Integration of 3D digital mammography with tomosynthesis for population breast-cancer screening (STORM): a prospective comparison study. *The lancet oncology*, 14(7), 583-589.
- [3] Bernardi, D, Pellegrini, M, Valentini, M, Fanto, C, Houssami, N, The STORM II (Screening with Tomosynthesis or Mammography II) Trial: Interim Comparison of Screen-reading Strategies in Population Breast Screening. Radiological Society of North America 2014 Scientific Assembly and Annual Meeting, - ,Chicago IL.