

# Prosthetic Management Following Mandibular Resection- A Clinical Report

S.P. Singh,<sup>1</sup> Rashi Jolly,<sup>2</sup> Rishabh Garg<sup>3</sup>

## ABOUT THE AUTHORS

**1. Dr. S.P.Singh** BDS, MDS,  
Professor, HOD,  
Department of  
Prosthodontics,  
Subharti Dental College,  
Meerut, Uttar Pradesh,  
India.

**2. Dr. Rashi Jolly** BDS,  
PG Student,  
Department of  
Prosthodontics,  
Subharti Dental College,  
Meerut, Uttar Pradesh,  
India.

**3. Dr. Rishabh Garg** BDS  
PG Student,  
Department of  
Prosthodontics,  
Subharti Dental College,  
Meerut, Uttar Pradesh,  
India

## Corresponding Author:

### Dr. Rishabh Garg

Department of  
Prosthodontics,  
Subharti Dental College,  
Meerut, Uttar Pradesh,  
India.

Email id:

[Rishabh\\_ssd22@yahoo.com](mailto:Rishabh_ssd22@yahoo.com)

Telephone : +91-8979520748

## Abstract

Mandibular resection leads to altered mandibular movements, disfigurement, difficult in swallowing, impaired speech and articulation, and deviation of the mandible towards the resected site. Numerous prosthetic methods employed to reduce or minimize deviation and improve function include maxillomandibular fixation, implant supported prosthesis, removable mandibular guide flange prosthesis, and palatal based guidance restoration. Management of patients who require mandibular resection without bony reconstruction is difficult. This article describes the prosthetic management of a patient following segmental mandibular resection.

**KEYWORDS:** Flange prosthesis, Mandibular defects, Mandibular resection

## Introduction

Loss of continuity of the mandible destroys the balance and symmetry of mandibular function, leading to altered mandibular movements and deviation of the residual fragment towards the surgical site. In general, patients suffering extensive soft tissue loss resulting from tight wound closure, radiation therapy and those requiring a classical neck dissection exhibit the most severe mandibular deviation and dysfunction. Conversely patients with mandibular resections resulting in little soft tissue loss have less mandibular deviation<sup>1</sup>. A classification of mandibular defects has been described by Cantor and Curtis. Although the classification system is suggested primarily for edentulous patients, it is also applicable to partially edentulous patients. This system classifies defects based on remaining structures.<sup>2</sup>

### Cantor and Curtis Classification<sup>2</sup> (Figure 1)

Class I: Mandibular resection involving alveolar defect with preservation of mandibular continuity (Fig 1a). Class II: Resection defects involve loss of mandibular continuity distal to the canine area (Fig. 1b). Class III: Resection defect involves loss up to the mandibular midline region. (Fig. 1c) Class IV: Resection defect involves the lateral aspect of the mandible, but are augmented to maintain pseudo articulation of bone and soft tissues in the region of the ascending ramus. (Fig. 1d) Class V: Resection defect involves the symphysis and parasymphysis region only, augmented to preserve bilateral temporomandibular articulations. (Fig. 1e) Class VI: Similar to class V, except that the mandibular continuity is not restored. (Fig. 1f)

Robinson et al. (1964)<sup>3</sup> stated that fabrication of a provisional guide plane facilitates the fabrication of a definitive restoration. Implant supported fixed prosthesis can be an optional treatment modality for functional and esthetic rehabilitation<sup>4</sup>. Intermaxillary fixation and as a guiding appliance for edentulous patient following hemisection of the mandible using a two piece gunning splint have been reported<sup>5</sup>. Mandibular resection prosthesis should be provided to restore the mastication within the unique movement capabilities of the residual function in the mandible. A common feature

Fig 1 - Cantor and Curtis classification of mandibular defects

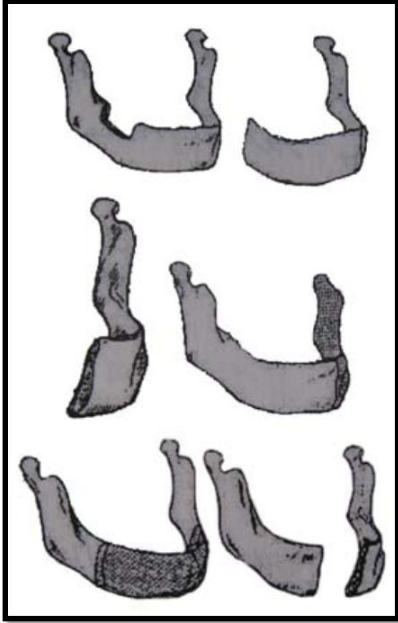


Figure 2- Extra oral view of patient

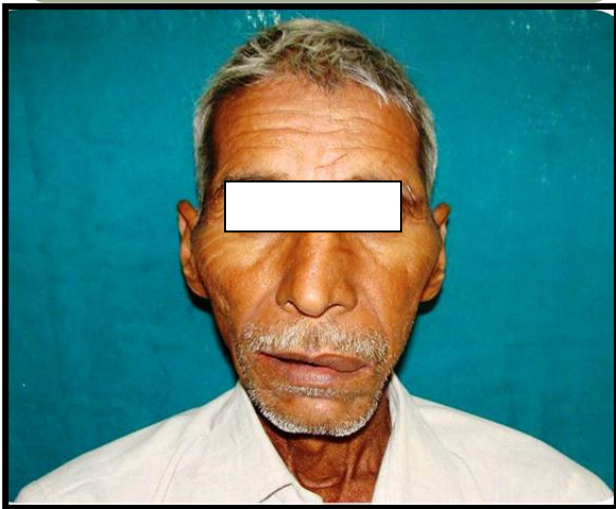


Figure 3- OPG of patient

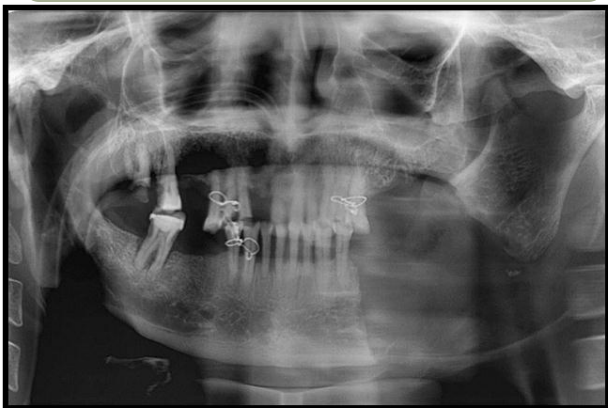


Figure 4- Try in stage

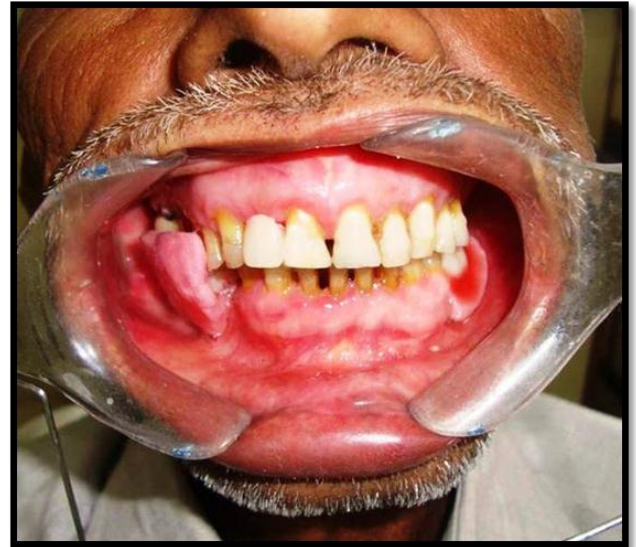

Figure 5- polished prosthesis in occlusion

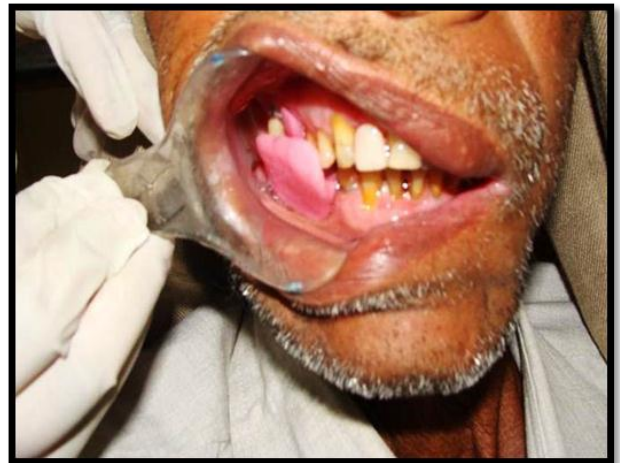
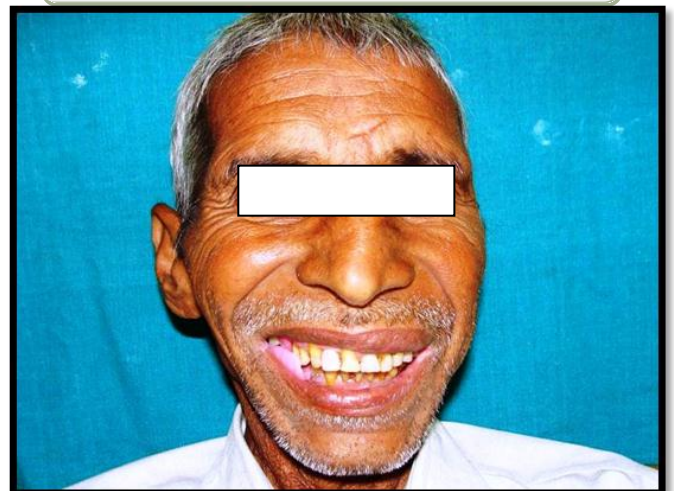
Figure 6- post operative extraoral view



among all removable resection prosthesis is that all framework designs should be detected by basic prosthodontic design. These include broad stress distribution, cross arch stabilization using a rigid major connector stabilizing and retaining components at locations within the arch to minimize dislodgement and replacement of tooth position that optimize prosthesis. Stability and functional needs modification to these principles are determined on an evidence basis and greatly influenced by unique residual tissue characteristics and mandibular movement dynamics<sup>6</sup>.

### Clinical report

This clinical report describes the prosthetic rehabilitation of the patient who underwent mandibular resection. A 45 year old male patient was referred to The Department of Prosthodontics, Subharti Dental College, Meerut after surgery and radiation for squamous cell carcinoma involving left retromolar trigone. Clinical examination revealed missing left mandible from the midline to the condyle. There was evidence of reconstruction of the soft tissue with left temporalis muscle flap. An extraoral examination showed an asymmetrical face, concave profile and ovoid face [Figure 2]. Clinical examination revealed severe deviation of the mandible towards the resected site with lack of proper contact between maxillary and mandibular teeth. An orthopantomogram(OPG) revealed resection of the mandible [Figure 3]. The tissue bed in the edentulous area was restored with temporalis muscle flap which was easily displaceable and quite yielding. The denture foundation was not ideal for support.

Based on the clinical situation, a palatal based guiding prosthesis and subsequently a removable partial denture with a buccal guiding flange was planned, since most mandibulectomy patients are not dependent on their prosthesis for oral function. The patient suffered severe deviation of the mandible and therefore palatal based guidance prosthesis was fabricated as a training appliance. A palatal acrylic flange of sufficient length was attached on the unaffected side to serve as a guiding plane. The size and shape of the flange is determined by the degree of deviation of the mandible. Initially the mandible was manipulated by guiding and moving it away from the surgical site. Acrylic resin was added little by little to the guiding plane of the flange so that the mandible could be guided to a correct occlusal position. Within 3 weeks the mandible was guided to the correct occlusal position. The patient was evaluated for the fabrication of a tooth supported removable partial denture with flange prosthesis. Impressions were made and diagnostic casts were prepared. The designs included a removable partial denture with a guiding flange on the non-defect side and retentive meshwork for acrylic support on the defect side.<sup>2</sup> Freedom of movement and lack of cuspal intercuspation was checked before denture insertion. The dentures were evaluated intraorally and the mandible was manipulated to the static centric position area [Figure 4, 5]. Any interference in normal movements was corrected. The patient was given routine post insertion instructions

and was motivated to make efforts to learn to adapt to the new dentures. Simple exercises were suggested to the patient such as repeated opening and closing of mandible. This helped the patient learn to manipulate the lower denture into the proper position. Within a week, the patient expressed satisfaction in mastication and phonetics [Figure 6].

### Discussion

This clinical report illustrates the prosthetic management of a patient who underwent mandibular resection. Since a considerable period of time had elapsed after the surgical procedure, guidance procedure was much more difficult for the patient. The earlier the mandibular guidance therapy is initiated in the course of treatment the more successful the patients definitive occlusal relationship restoration<sup>1</sup>. It has been reported that fabrication of a provisional guide plane facilitates the fabrication of a definitive restoration<sup>3</sup>. A guidance plane with a palatal acrylic flange of sufficient size and shape was useful in guiding the mandible to a correct occlusal position. With most mandibulectomy patients the primary determinant usually is related to occlusion. In these patients definitive partial denture restoration are deferred until acceptable maxillomandibular relationship are obtained or an end point in mandibular guidance therapy has reached. An implant supported fixed prosthesis or a removable cast partial denture are the two main treatment options to restore partially edentulous arches in patients who had undergone mandibular resection. Implant supported prosthesis was not considered since no bone graft was used. Many mandibulectomy patients are not dependent on this prosthesis for oral function. In many mandibulectomy patients it may not be possible to design a framework since the location of the fulcrum line is not easily determined making it more difficult to predict movement patterns of the prosthesis during function<sup>1</sup>.

### Conclusion

Currently, most lateral segmental mandibulectomy are also reconstructed surgically. When the mandible is not stabilized following resection and discontinuity defect results mandibular resection prosthesis should be provided to restore mastication within the unique movement capabilities of the residual functioning mandible.

### References

1. Beumer. J III, Curtis T.A, Marunick MT. Maxillofacial Rehabilitation. Prosthodontic and surgical consideration. St. Louis: Ishiyaku. Euro America. 1996 p184 – 188
2. Fonsica R.J, Davis W.H, Reconstruction preprosthetic oral and maxillofacial surgery, 2nd ed. WB Saunders Company: p1063 -1067

3. Robinson JE, Rubright W.C. Use of a guide plane for maintaining the residual fragment in partial or hemimandibulectomy J Prosthet Dent 1964;14:992 -999.
4. Oelgissa D, Levin L, Barak S, Arad Schwartz D. Rehabilitation of an irradiated mandible after mandibular resection using implant/ tooth supported fixed prosthesis : A clinical report. J Prosthet Dent 2004;91:310- 314.
5. Fallore L, Marchmont – Robinson H, Crinzi RA, Edmonds DC. Use of a two piece Gunning splint as a Mandibular guide appliance for a patient treated for Ameloblastoma. Oral Surgery Oral Med Oral Patho. 1988;66:662-665.
6. Carr AB, Mc Givney GP, Brown D.T: Mc Crackens Removable Partial Prosthodontics, 11th ed, India, MOSBY Inc. p 414.