

Case Report

Morvan syndrome: An interesting case of a rare disease

Amita Bhargava¹, Subhakaran Khichar², Arvind Kumar Lakesar³, Akanksha Chaudhary³, Aditya Duggal³

From ¹Senior Professor; ²Professor; ³Senior Resident, Department of Neurology, Dr. S.N. Medical College, Jodhpur, Rajasthan, India.

Correspondence to: Dr. Arvind Kumar Lakesar, 27 A/55, C/o Mr. Motilal Bhansali, Adarsh Society, Shastri Circle, Near MDM Hospital Jodhpur - 342003, Rajasthan, India. E-mail: alarvindlakesar@gmail.com

Received - 25 December 2019

Initial Review - 10 January 2020

Accepted - 21 January 2020

ABSTRACT

Morvan syndrome is a rare disorder of peripheral nerve hyperexcitability, autonomic and central nervous system hyperactivity. It is considered autoimmune and paraneoplastic in nature. The most common associated antibodies are voltage-gated potassium channel (VGKC) complex antibodies which target leucine-rich glioma inactivated 1 (LGI-1) and contactin-associated protein 2 (CASPR-2). It is characterized by myokymia, burning pain, cramps, stiffness, weakness, hyperhidrosis, weight loss, insomnia, and hallucinations. Thymectomy, long-term immunosuppression, plasmapheresis, intravenous immunoglobulin (IVIG), steroids are the treatment options. Carbamazepine, phenytoin, amitriptyline, and benzodiazepine are useful in relieving symptoms. We report a rare case of this disease from western Rajasthan who presented with bilateral diffuse burning pain, cramps, insomnia, weight loss, hyperhidrosis, visual hallucinations, and continuous muscle twitching and rippling activity over the lower back paraspinal muscles. His serum VGKC antibodies were positive. He was treated with IV methylprednisolone (MPS) and IVIG and had a good response to therapy. We should look for rippling muscle movement in a high index of suspicion and should not be missed.

Keywords: Autoimmunity, Morvan syndrome, Myokymia, VGKC-complex antibodies.

Morvan syndrome is a rare disease discovered in 1890 by Augustin Marie Morvan [1,2]. There have been approximately 60 cases published in the French and other literature but only a few in the English literature [3]. It is considered as a part of Neuromyotonia or syndrome of continuous muscle fiber activity. It is characterized by subacute onset muscle stiffness, continuous twitching, and quivering of muscles, cramps, anxiety, confusion, decreased sleep, hallucinations, excess sweating, memory disturbance, sense of burning and weight loss. Distal muscles are more commonly involved in contrast to axial involvement as contrast to stiff-person syndrome. It is associated with voltage-gated potassium channel antibodies and paraneoplastic disorders. Systemic lupus erythematosus (SLE) association is also reported. Abnormal continuous muscle rippling movement is a clue to the diagnosis. Spontaneous remission was seen over time and around 10% of cases can lead to death [4]. Immunosuppression in the form of steroids, intravenous immunoglobulin (IVIG) and plasma exchange are the mainstay of therapy along with drugs like carbamazepine, phenytoin, amitriptyline and benzodiazepine which are useful in relieving symptoms.

We report this case considering the rarity of this disease and a very high index of suspicion is required to suspect such syndrome. Detail history along with a search for rippling muscle movement in the examination should be carefully looked for the diagnosis.

CASE REPORT

A 34-year old male presented with a history of sub-acute onset progressive symptoms in the form of diffuse burning sensation in all the 4 limbs, myalgia, and cramps in legs, polyarthralgia, insomnia, weight loss, hyperhidrosis, agitation, anxiety, palpitation, visual hallucinations, constipation and backache for the last 5 months. No significant past and family history was present. There was no history of seizures, abnormal movement, headache, and memory loss.

General examination suggested cachexia. Vitals were normal. His central nervous system examination was normal except continuous rippling muscle movement over the lower back and flanks (video 1). On the basis of his typical clinical features and myokymia, Morvan syndrome was suspected.

His routine investigations including complete blood counts, biochemistry, electrolytes, erythrocyte sedimentation rate (ESR) and creatine phosphokinase (CPK-NAC) were normal. He was strongly positive for CASPR-2 and LGI-1 antibodies. His Magnetic resonance imaging (MRI) brain and spinal cord screening, Contrast-enhanced computed tomography (CECT) chest and abdomen were normal. The cerebrospinal fluid study was normal. His nerve conduction studies (NCV) and electroencephalogram (EEG) were unremarkable. Electromyography (EMG) was suggestive of rhythmic grouped repetitive doublets and triplets suggestive of myokymic discharges (Fig. 1).

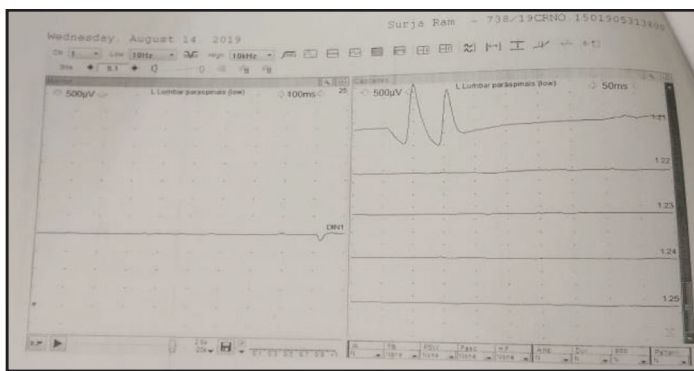


Figure 1: EMG of the patient showed doublets and triplets in groups (above recording showing one doublet recorded at rest).

The patient was started on intravenous (IV) methylprednisolone 1gm/day, phenytoin 300 mg/day, carbamazepine 600 mg/day, amitriptyline 50 mg/day and lorazepam 10 mg/day. After 5 days, IVIG (2gm/kg over 5 days) was added as the patient did not have a good response. After the 3rd cycle of IVIG (1gm/kg over 3 days, 3 weeks apart), he responded nicely. In follow-up after 2 months of therapy, the patient got relieved with his all symptoms and his quivering over back muscles disappeared (video 2).

DISCUSSION

Morvan's syndrome is a rare autoimmune or paraneoplastic disorder which manifests as peripheral nerve hyperexcitability with dysautonomic features, cognitive, behavioral abnormalities, insomnia and agrypnia excitation [5]. Male predominance has been seen in the reported cases [6]. The association of disease with thymoma, prostate adenoma, in-situ carcinoma of the sigmoid colon, autoimmune diseases, and autoantibodies suggests autoimmune or paraneoplastic pathogenesis [7].

Association with some heavy metals like gold, mercury, or manganese poisoning has also been reported [8]. Association with SLE also described [9]. One study reported Morvan syndrome cases after scrotal sac drainage and chemical instillation in hydrocele [10]. Antibodies against voltage-gated potassium channels (VGKC), acetylcholine receptor antibody, titin, and N-type calcium channels have been described in the pathophysiology of this disease [5].

The affection of these antibodies to the hippocampus can also cause CNS dysfunction [5,6]. One case report from India reported extensive neurological manifestations affecting the peripheral nervous system in form of quivering of muscles, neuromyotonia, autonomic features in form of tachycardia, low blood pressure, increased sweating, bladder symptoms and central nervous system involvement in form of decreased sleep, altered behavior in sleep, generalized hyperreflexia [11]. Isaac's syndrome also presents as continuous muscle fiber activity with myokymia, at rest muscle stiffness, cramps but additional above-mentioned features are found in Morvan's syndrome apart from Isaac's syndrome [12]. Close differential

diagnosis of Morvan's syndrome includes limbic encephalitis, acquired neuromyotonia (Isaac syndrome), and fatal familial insomnia [1,3].

EEG, NCV, brain MRI and CSF findings are not much helpful in diagnosis and may have non-specific results. The electrophysiological hallmark is the spontaneous firing of single motor units as a doublet, triplet or multiplet discharges that have a high intra burst frequency (usually 150 to 300 Hz) suggestive of myokymia [13].

No common consensus and guidelines regarding treatment are available yet. Phenytoin, carbamazepine, amitriptyline, and benzodiazepine may be useful [5,14]. Immunosuppressive therapies, encompassing corticosteroids, IVIG, plasmapheresis, azathioprine, methotrexate and more recently, rituximab, are the mainstay of therapy [14]. A thymectomy is an option in thymoma associated cases. One Indian case report suggested that plasma exchange as a treatment modality should always be considered in the absence of established guidelines [15]. One more case report of a 48-year-old female with Morvan syndrome also reported from India [16].

In our case, on the basis of his typical clinical features and myokymia, we suspected Morvan syndrome. He was strongly positive for CASPR-2 and LGI-1 antibodies and EMG was also supportive. The patient was started on carbamazepine, phenytoin, amitriptyline, lorazepam, and steroids. IVIG was also added as the patient did not have a good response. After 3rd cycle of IVIG 3 weeks apart, he responded nicely.

CONCLUSION

Morvan syndrome is a rare disease of autoimmune and paraneoplastic etiology. A detail examination should be done to look for rippling muscle movement in a high index of suspicion and should not be missed. As the awareness and knowledge are increasing about this rare disease more case reports are being published and guideline is yet to be made regarding treatment.

REFERENCES

1. Josephs KA, Silber MH, Fealey RD, Nippoldt TB, Auger RG, Vernino S. Neurophysiologic studies in Morvan syndrome. *J Clin Neurophysiol.* 2004;21:440-5.
2. Walusinski O, Honnorat J. Augustin Morvan (1819-1897), a little-known rural physician and neurologist. *Rev. Neurol. (Paris).* 2013;169:2-8.
3. Masood W, Sitammagari KK. Morvan Syndrome (Morvan Fibrillary Chorea, MFC): Florida: StatPearls Publisher, Inc. 2019
4. Plazzi G, Montagna P, Meletti S, Lugaresi E. Polysomnographic study of sleeplessness and oneiricisms in the alcohol withdrawal syndrome. *Sleep Medicine.* 2001;3:279-82.
5. Liguori R, Vincent A, Clover L, Avoni P, Plazzi G, Cortelli P, *et al.* Morvan's syndrome: Peripheral and central nervous system and cardiac involvement with antibodies to voltage-gated potassium channels. *Brain.* 2001;124: 2417-26.
6. Irani SR, Pettingill P, Kleopa KA, Schiza N, Waters P, Mazia C, *et al.* Morvan syndrome: clinical and serological observations in 29 cases. *Ann Neurol.* 2012;72:241-55.

7. Lee EK, Maselli RA, Ellis WG, Agius MA. Morvan's fibrillary chorea: a paraneoplastic manifestation of thymoma. *J Neurol Neurosurg Psychiatry*. 1998;65:857-62.
8. Haug BA, Schoenle PW, Karch BJ, Bardosi A, Holzgraefe M. Morvan's fibrillary chorea. A case with possible manganese poisoning. *Clin Neurol Neurosurg*. 1989;91:53-9.
9. Macaron G, Rassy EE, Koussa S. Morvan Syndrome Secondary to Thymic Carcinoma in a Patient with Systemic Lupus Erythematosus. *Case Report Neurolog Med*. Volume 2016, Article ID 9142486.
10. Sharma S, Sharma P. Morvan syndrome: After scrotal sac drainage and chemical instillation in hydrocele. *Neurol India*. 2013;61:300-2.
11. Bajaj BK, Shrestha S. An interesting case report of Morvan syndrome from Indian subcontinent. *Neurol India*. 2007;55:67-9
12. Issacs H. A syndrome of continuous muscle fiber activity. *J Neurol Neurosurg Psychiatry*. 1964;24:319-25.
13. American Association of Electrodiagnostic Medicine glossary of terms in electrodiagnostic medicine. *Muscle Nerve Suppl*. 2001;10:S1-50.
14. Abou-Zeid E, Boursoulian LJ, Metzger WS, Gundogdu B. Morvan syndrome: a case report and review of the literature. *J Clin Neuromusc Dis*. 2012;13:214-27.
15. Dubey R, Mallhi RS, Asthana B, Kushwaha N, Yadav A. Successful therapeutic plasma exchange in a patient with Morvan syndrome. *Asian J Transfus Sci*. 2019;13:73-5
16. Sreeni, Zackariah NM, Lakshmi R'A Case Report: Morvan's Syndrome Research *J. Pharm. and Tech*. 2017;10:1174-8

Funding: None; Conflict of Interest: None Stated.

How to cite this article: Bhargava A, Khichar S, Lakesar AK, Chaudhary A, Duggal A. Morvan syndrome: An interesting case of a rare disease. *Indian J Case Reports*. 2020;6(1):30-32.

Doi: 10.32677/IJCR.2020.v06.i01.010