

## Multiple jejunal perforations due to enteric fever: A case report from a rural tertiary care hospital india

Apurva R Shah<sup>1</sup>, Chintan A Godhani<sup>1</sup>, Abhi R Dalsania<sup>2</sup>

From <sup>1</sup>Residents, <sup>2</sup>Assistant Professor, Department of General Surgery, C.U.Shah Medical College and Hospital (CUSMCH), Surendranagar, Gujarat, India.

**Correspondence to:** Dr. Apurva R Shah, Department of General Surgery, C U Shah Medical College and Hospital, Surendranagar - 363001, Gujarat, India. E-mail: [ars.1992@yahoo.co.in](mailto:ars.1992@yahoo.co.in)

Received - 29 December 2019

Initial Review - 14 January 2020

Accepted - 23 January 2020

### ABSTRACT

Intestinal perforation is one of the most dreaded and common complications of the typhoid fever remarkably seen in developing countries which lead to diffuse peritonitis needing early surgical intervention. This is a case report of a 45-year-old male from a rural village of India presented to the emergency room with features of acute abdomen and intestinal obstruction. He underwent exploratory laparotomy and the findings were suggestive of multiple perforations due to enteric fever causing adhesive obstruction of the bowel due to peritonitis. Resection and jejunojejunal anastomosis were done as a part of the treatment. Thus, perforation occurring due to enteric fever should always be considered as a differential diagnosis in the patient presenting with an acute abdomen in rural areas where sanitary facilities are scanty.

**Keywords:** *Enteric fever, Multiple jejunal perforations, Rural india.*

Enteric fever is a major public health problem with an estimated incidence of 11.9 to 26.9 million cases worldwide each year [1]. It is one of the main health challenges in impoverished overcrowded areas of developing countries related to lack of safe drinking water. It is generally transmitted by the fecal-oral route and is often endemic [2]. Being one of the most common enteric infections in the developing world, the infection starts with a febrile episode and if untreated, eventually involves almost every system of the body with abdominal complications developing first [3]. Although intestinal hemorrhage is the most common complication of typhoid fever, yet intestinal perforation continues to be the most frequent cause of its high morbidity and mortality. The frequency of perforation varies between 0.8 to 18%. Total mortality rates of typhoid intestinal perforation (TIP) cases are reported to be between 5 to 62%. While early surgical procedures are regarded as definitive treatment along with preoperative resuscitation and postoperative intensive care, the methods that should be used in surgery are still contentious [4,5].

In the present case report, we present a rare case of multiple jejunal perforations due to enteric fever that presented as an acute abdomen with obstruction of the small bowel. The current paper aims to report a common case of enteric perforation but the unusual presentation of sealed-off perforation of a 45-year-old male from a rural village of India who was successfully managed with one-step surgery comprising bowel resection and jejunojejunal anastomosis in rural tertiary care hospital. The clinical challenges presented by this rare and critical case in a resource-limited setting are also highlighted.

### CASE REPORT

A 45-year-old male from a remote village presented to the emergency room with complaints of low-grade fever for a week, generalized abdominal pain and distension with multiple episodes of gastric vomiting for 5 days and melena for 2 days. He did not receive any treatment during this week. He did not have a history of similar episodes in the past or any co-morbid conditions or history of analgesic abuse but he had a history of occasional alcohol intake for the past 20 years.

On physical examination, he was vitally stable but the abdomen was tense, tender, distended and bowel sounds were absent. Guarding and rigidity both were present. His per rectal examination revealed ballooning of the intestine and blackish soft stool stained finger. On proctoscopy, there was no sign of internal hemorrhoids or fissures.

Laboratory Examinations were as follows. Hemoglobin: 12.7 gm%, total leukocyte count 8500/mm<sup>3</sup> (neutrophils 63%, lymphocytes 31%). Platelet count was 166,000/mm<sup>3</sup>. Serum glutamic pyruvic transaminase (SGPT) 45U/L. Total protein was 4.20 g/dl, albumin was 1.48 gm/dl and potassium was 2.75mEq/L. His Widal test was negative for *Salmonella typhi*. His ultrasound of the abdomen revealed acute intestinal obstruction with minimal free fluid in Morrison's pouch. His plain radiograph of the abdomen revealed multiple air-fluid levels suggestive of intestinal obstruction (Fig. 1). Plain radiograph and ultrasound of thorax revealed bilateral pleural effusion.

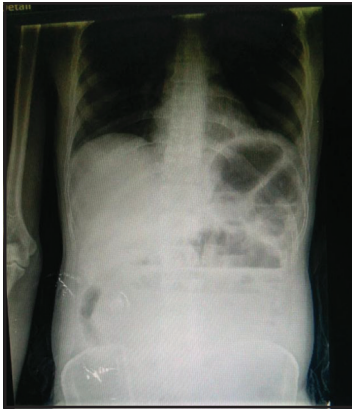


Figure 1: Plain radiograph of the abdomen (standing).

After proper resuscitation and nasogastric tube insertion, which aspirated around 150 ml of gastric and bilious liquid, he was operated for the emergency exploratory laparotomy where the findings were multiple patchy impending perforations (Fig. 2) with purulent slough extending 10cm away from the duodenojejunal flexure and involving approximately 50cm of jejunum. There was also a single perforation at the antimesenteric border (Fig. 3) of approximately 3 cm diameter and 15cm away from duodenojejunal flexure. There were flimsy interbowel adhesions that were wrapped by the omentum and there was the presence of purulent discharge in the peritoneal cavity.

The affected portion of jejunum was resected and anastomosis of the remaining portion of the jejunum with ileum was done. Abdominal drain number 32 French in the sub-hepatic area and 28French in the pelvic region was put and the abdomen was primarily closed layer after layer. The patient was kept nil orally for 3days and was started on injectable Piperacillin (4.5gm, 8 hourly) and Metronidazole (500mg, 8 hourly) for 7 days. His stool routine microscopic examination was inconclusive but stool culture was positive for *S. typhi*. His blood culture was sent which was found negative.

The resected specimen sent for histopathological examination revealed grossly 7 lymph nodes over the mesenteric border and 1x1 cm and 1cm deep ulcers over the surface. On microscopic examination, the area was infiltrated with neutrophils lymphocytes and histiocytes with areas of necrosis and hemorrhage suggestive

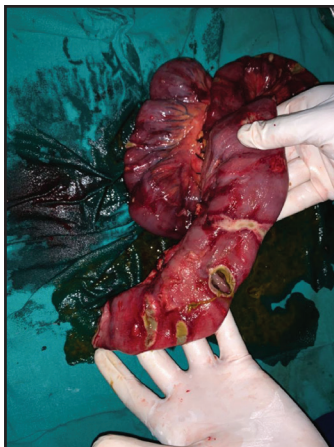


Figure 3: Antimesenteric border perforation.

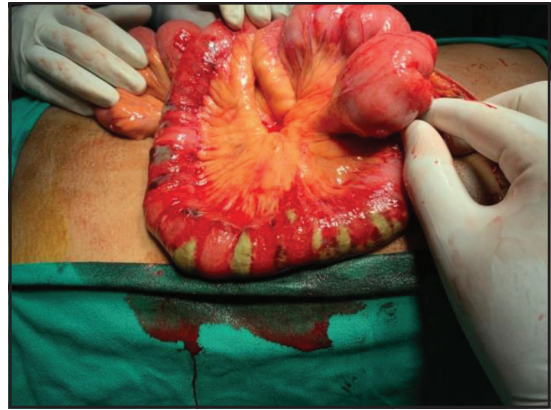


Figure 2: Multiple jejunal perforations.

of “bacterial enteritis”. *S. typhi* could not be isolated from the specimen.

We were unable to perform Polymerase chain reaction (PCR) for the isolation of *S. typhi* and other serotypes responsible for typhoid induced perforation due to scarcity of resources at our centre. But these findings were consistent with typhoid induced perforation and so the diagnosis was confirmed. He also had superficial surgical site infection on the 4<sup>th</sup> postoperative day whose culture was positive for Klebsiella species.

The condition of the patient improved and the nasogastric tube was removed on the 4<sup>th</sup> postoperative day. The patient was started on a soft diet on the 5<sup>th</sup> day postoperatively and secondary closure of the surgical site done on the 12<sup>th</sup> postoperative day while he was discharged with oral medication on the 14<sup>th</sup> day postoperatively. He came for regular follow-up and is healthy.

## DISCUSSION

Typhoid Fever remains a global health problem and the exact incidence is difficult to estimate as the myriad of clinical features resembles many other diseases [6]. One of the complications of typhoid fever is intestinal hemorrhage and perforation. Typhoid fever with perforation is best managed by early surgical intervention. Various surgical options available are simple primary closure, primary closure with an omental patch, resection and anastomosis, and closure with ileo-transverse colostomy [7].

In our case report, the patient was a middle-aged man from a rural village of India. Traditionally, the diagnosis is made mainly on the basis of clinical history and examination. X-ray abdomen and ultrasound abdomen also supported the diagnosis. According to a study done in1984 [7], a history of fever followed by the abdominal pain and features of peritonitis are suggestive of typhoid perforation which is consistent with our case. The blood culture was negative and it is quoted that blood cultures are positive only in 3% to 34% cases of typhoid perforation but to support the case, the stool culture was positive for *S. typhi*.

On exploration, the peritoneal cavity was studded with purulent material and small intestine particularly jejunum had multiple impending perforations involving approximately 50 cm

of jejunum while the rest of the bowel was normal but edematous. So, we decided to perform resection of the affected part of the jejunum and anastomose rest of the jejunum with the proximal part of the ileum by an end to end anastomosis.

Histopathological examination revealed areas of necrosis with hemorrhage with infiltration of plenty of neutrophils, lymphocytes and plasma cells along with enlarged groups of lymph nodes over the mesenteric border. These findings are consistent with typhoid induced perforation. Sharma AK et al also recommend performing resection and anastomosis in multiple perforations with the relatively healthy gut as was carried out in this case [4].

## CONCLUSION

Typhoid fever and its complications continue to be a great health problem in the developing countries. Thus, small intestinal perforation due to enteric fever must be kept as a differential diagnosis in an area where sanitary facilities are scanty. Proper resuscitation and preoperative and postoperative care are one of the most important aspects that determine the morbidity and mortality.

## REFERENCES

1. Divyashree S, Nabarro LE, Veeraraghavan B, Rupali P. Enteric Fever in India: current scenario and future directions. *Trop Med Int Health*. 2016;21:1255-62.
2. Contini S. Typhoid Intestinal perforation in developing countries: still unavoidable deaths. *World J Gastroenterol*. 2017;23:1925-31.
3. Vagholkar K, Mirani J, Jain U, Iyenger M, Chavan RK. Abdominal Complications of Typhoid Fever. *J Surg (Journal de Chirurgie)*. 2015;11:359-361 doi:10.7438/1584-9341-11-2-1.
4. AK Sharma, RK Sharma, SK Sharma, A Sharma, D Soni. Typhoid Intestinal Perforation: 24 Perforations in One Patient. *Ann Med Health Sci Res*. 2013;3: S41-3. doi:10.4103/2141-9248.121220.
5. Anupama Pujar K, Ashok AC, Rudresh HK, Srikantaiah HC, Girish KS, Suhas KR Mortality in typhoid intestinal perforation-a declining trend. *J Clin Diagn Res*. 2013;7:1946-8. doi: 10.7860/JCDR/2013/6632.3366
6. Dr. (Colonel) Gurmeet Singh Sarla. Enteric Perforation – a case report. *Asian J Scie & Tech*. 2018;9:8315-7.
7. Khanna AK, Misra MK. Typhoid perforation of the gut. *Postgrad Med J* 1984;60:523-5.

*Funding: None; Conflict of Interest: None Stated.*

**How to cite this article:** Shah AR, Godhani CA, Dalsania AR. Multiple jejunal perforations due to enteric fever: A case report from a rural tertiary care hospital india. *Indian J Case Reports*. 2020;6(1):38-40.

**Doi:** 10.32677/IJCR.2020.v06.i01.013