

Case Report

Primary neuroendocrine carcinoma of the breast: A rare entity

Aravinth Subramaniam, Divya Gnanasekaran, Saravanakumar Suruliraj, Palanivelu Chinnusamy

From Consultant, Department of Pathology, Department of Surgery, Department of Gastrointestinal surgery, GEM Hospital & Research Centre, Coimbatore, Tamil Nadu, India.

Correspondence to: Dr. Divya Gnanasekaran, Department of Pathology, GEM Hospital and Research Centre, Palaniappa Nagar, Sowripalayam Pirivu, Ramanathapuram, Coimbatore - 641045, Tamil Nadu, India. E-mail: divyajayamurugan@yahoo.in

Received - 22 November 2019

Initial Review - 07 December 2019

Accepted - 22 January 2020

ABSTRACT

Neuroendocrine carcinomas of the breast are a rare and distinct entity that is not routinely encountered in clinical practice. The diagnosis of primary neuroendocrine breast carcinoma is mainly a diagnosis of exclusion as the metastatic disease is more common a possibility. The algorithmic approach in the evaluation of such tumors includes the clinical and radiological examination of the breast lumps followed by correlation with Histopathological study and Immunohistochemistry tests. We report a case of primary neuroendocrine carcinoma of the breast in a 64-year-old female who presented with breast lump for one month duration.

Keywords: Breast, Immunohistochemistry, Metastasis, Neuroendocrine carcinomas.

Primary Neuroendocrine carcinoma (NEC) of the breast is a great diagnostic challenge as it lacks the characteristic clinical and radiological features. This under-recognized entity constitutes less than 0.1 % of all breast cancers and less than 1% of all neuroendocrine tumors [1]. These tumor cells have characteristic salt and pepper chromatin. The diagnosis of NEC requires confirmation by an ancillary method of immunohistochemistry (IHC) which demonstrates the presence of neuroendocrine differentiation by using markers such as synaptophysin, chromogranin [2]. However, before diagnosis, the possibility of a metastatic tumor should be ruled out by appropriate imaging studies along with a thorough clinical history correlation to avoid misdiagnosis and overtreatment. Optimal treatment strategy in such tumors is not standardized as only a few cases of primary neuroendocrine carcinomas have been documented in the literature. Hence due to the rarity and to increase the literature evidence, we report a case of neuroendocrine carcinoma of the breast in a sexagenarian woman.

CASE REPORT

A 64-year-old post-menopausal multiparous woman presented to the surgery outpatient department with a lump in the left breast for one month. It was insidious in onset and progressively increased in size. There was no significant past medical, family or surgical history.

Her vitals were stable. On physical examination, a 3x3x2 cm lump was present in the lower inner quadrant which was firm to hard in consistency and not freely mobile. The overlying skin and nipple-areola were unremarkable. There was no significant axillary lymphadenopathy. The right breast was normal. Other systemic examination was normal.

Ultrasound of both breasts showed an echo poor lesion with irregular margins in the left breast and Breast Imaging-Reporting and Data System (BI-RADS) assessment category 5 was given which is highly suggestive of malignancy. Fine needle aspiration cytology (FNAC) of the left breast lump was performed yielding scant material which showed a few macrophages and adipose tissue against a hemorrhagic background. There were no atypical cells in the smears studied. Hence, a biopsy was suggested if clinically suspicious of malignancy. Later Trucut biopsy of the left breast lump was done which was reported as carcinoma with neuroendocrine differentiation. IHC did show positivity for chromogranin, synaptophysin and CK 7. Needle core biopsy and IHC findings were consistent with the diagnosis of small cell neuroendocrine carcinoma. With the aid of the Positron Emission Tomography (PET) scan, the possibility of metastatic disease was ruled out.

The patient underwent left modified radical mastectomy. Gross examination revealed a circumscribed lesion within the breast measuring 3x2.5x2 cm which had a grey-white cut surface (Fig. 1a and 1b). Microscopy showed a neoplasm composed of cells arranged in nests and trabeculae separated by fibrous septa. No mucinous areas or solid papillary growth were seen. Albeit the morphology strongly favored the neuroendocrine differentiation, we still ruled out the possible other differentials having a similar picture like in invasive lobular carcinoma with alveolar pattern and endocrine Ductal carcinoma in situ.

Hence based on morphology and IHC confirmation, the diagnosis of invasive carcinoma with neuroendocrine features was given (Fig. 1c and 1d). The postoperative period was uneventful. The patient was comfortable at the time of discharge and discharged with a drain in situ. The patient received

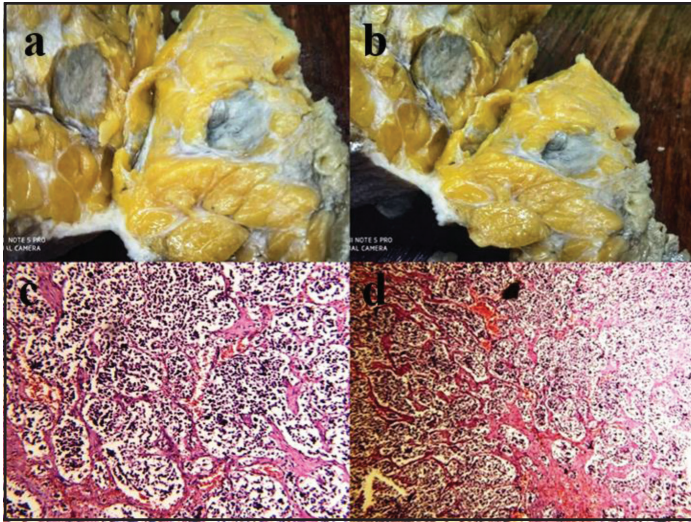


Figure 1: (a and b) Gross picture of the tumour; (c and d) The neoplastic cells are small arranged in nests with dispersed chromatin; H&E- 40x.

adjuvant chemotherapy (Epirubicin, Endoxan, and Fluorouracil), radiotherapy, and hormonal therapy. At one-year imaging and clinical follow-up, the patient had no evidence of metastasis.

DISCUSSION

Neuroendocrine differentiation in breast carcinomas was first described by Feyrter and Hartmann in 1963, based on positive silver staining in mucinous carcinomas of the breast [3]. The primary NEC of the breast is under-recognized owing to the lack of established consensus on the degree of neuroendocrine differentiation required for the diagnosis. Two histogenesis theories such as arising from pre-existing endocrine cells and differentiation processes within the breast have been postulated regarding the origin of such tumors in the breast [3]. An association of these tumors with mucinous histology, solid papillary growth pattern and invasive lobular carcinoma has been reported in the literature [4].

The diagnosis is complex due to the absence of characteristic clinical and image findings [4]. The most common sites include the lungs and gastrointestinal tract, however, occurrence in the breast is rare. The first case series on carcinoid tumors of the breast was published by Cubilla and Woodruff in 1977 [5]. There is no significant difference in clinical presentation and usually occurs in the elderly age group [6]. Tang *et al* reported that neuroendocrine differentiation was missed in up to 69% (51 of 74) of breast carcinomas [7]. The radiological findings are not typical and may look similar to one of the other types of breast tumors. Neuroendocrine differentiation in breast carcinomas is often overlooked in routine practice.

The presence of ductal carcinoma in situ adjacent to the tumor can strongly establish and reconfirm the primary origin of the breast. Before designating a case as NEC of the breast, utmost care must be taken to rule out the possibility of metastatic cancer from the lung, gastrointestinal tract (GIT), pancreas, and cervix as histomorphology of both primary and metastasis remain similar [8].

ER and PR can be positive in both primary and metastatic disease. IHC markers such as mammaglobin and GCDFP help in specifically identifying primary carcinoma of the breast [9]. GATA3, mammaglobin, and GCDFP15 serve as the most specific markers in establishing the primary origin of the breast [10]. Based on the size of the tumor and lymph nodal status, the management of such an entity is usually surgery [11]. The benefits of adjuvant therapy have not been demonstrated in the literature because of the low occurrence of the disease but invariably all the patients with primary NEC of the breast are treated with routine chemotherapy cycles.

CONCLUSION

In the era of evolving clinical perspectives, a pathologist occupies the forefront of inactive patient management. It's really important to be borne in mind that neuroendocrine carcinomas do occur in breast and even if subtle changes of neuroendocrine differentiation exist it must be confirmed with Immunohistochemistry analysis. Additionally, it is critical to distinguish primary and metastatic neuroendocrine carcinomas as the former is still very rare than the latter.

REFERENCES

- Ogawa H, Nishio A, Satake H, Naganawa S, Imai T, Sawaki M, *et al.* Neuroendocrine tumor in the breast. *Radiat Med.* 2008;26:28-32.
- Duan K, Mete O. Algorithmic approach to neuroendocrine tumors in targeted biopsies: practical applications of immunohistochemical markers. *Cancer Cytopathol.* 2016;124:871-84.
- Feyrter F, Hartmann G. Uber die carcinoide Wuchsform der Carcinoma mammae, insbesondere das Carcinoma Solidum (gelatinosum) mammae. *Frankf Z Pathol.* 1963;73:24-39
- Rosen LE, Gattuso P. Neuroendocrine Tumors of the Breast. *Arch Pathol Lab Med.* 2017;141:1577-81.
- Cubilla AL, Woodruff JM. Primary carcinoid tumor of the breast. A report of 8 patients. *Am J Surg Pathol.* 1977;1:283-92
- Inno A, Bogina G, Turazza M, Bortesi L, Duranti S, Massocco A, *et al.* *Oncologist.* 2016;21:28-32. doi: 10.1634/theoncologist.2015-0309
- Tang F, Wei B, Tian Z, Gilcrease MZ, Huo L, Albarracín CT, *et al.* Invasive mammary carcinoma with neuroendocrine differentiation: histological features and diagnostic challenges. *Histopathology.* 2011;59:106-15.
- Banu KJ, Ballal CR, Pai N, Permi H. Primary Neuroendocrine Carcinoma of Breast. *Indian J Surg Oncol.* 2015;6:110-2. doi: 10.1007/s13193-014-0370-z.
- Huo L, Zhang J, Gilcrease MZ, Gong Y, Wu Y, Zhang H, *et al.* Gross cystic disease fluid protein-15 and mammaglobin A expression determined by immunohistochemistry is of limited utility in triple-negative breast cancer. *Histopathology.* 2013;62:267-74. doi: 10.1111/j.1365-2559.2012.04344.x.
- Ni YB, Tsang JYS, Shao MM, Chan SK, Cheung SY, Tong J, *et al.* GATA-3 is superior to GCDFP-15 and mammaglobin to identify primary and metastatic breast cancer. *Breast Cancer Res Treat.* 2018;169:25-32. doi: 10.1007/s10549-017-4645-2.
- Sopik V, Narod SA. The relationship between tumor size, nodal status, and distant metastases: on the origins of breast cancer. *Breast Cancer Res Treat.* 2018;170:647-56. doi: 10.1007/s10549-018-4796-9.

Funding: None; Conflict of Interest: None Stated.

How to cite this article: Subramaniam A, Gnanasekaran D, Suruliraj S, Chinnusamy P. Primary neuroendocrine carcinoma of the breast: A rare entity. *Indian J Case Reports.* 2020;6(1):33-34.

Doi: 10.32677/IJCR.2020.v06.i01.011