
the Potency of Formalin in Atenuation of Pathogenicity in Eimeria Tenella at the Caecum of Broiler Chicken

by Muchammad Yunus

Submission date: 19-Dec-2019 03:44PM (UTC+0800)

Submission ID: 1236919328

File name: Bukti_C_09._The_Potency_of_Formalin_in_Atenuation....pdf (448.6K)

Word count: 3161

Character count: 17208

The Potency of Formalin in Atenuation of Pathogenicity in *Eimeria Tenella* at the Caecum of Broiler Chicken

Enik Setyowati¹, Muchammad Yunus², Dadik Rahardjo¹

¹Faculty of Veterinary, Airlangga University, ²Departement of Parasitology Veterinary, Faculty of Veterinary, Airlangga University, Kampus C, Mulyorejo, Kec. Mulyorejo, Kota Surabaya, Jawa Timur

ABSTRACT

Background: Coccidiosis is a parasitic disease that disrupts digestive tract, especially in caecum. It causes a lot of harm to chicken farms. Formalin, can be a new invention as an alternative for *Eimeria tenella* protozoa attenuation in vaccines.

Aim: To determine formalin effect and optimum concentration for formalin attenuation of pathogenicity to cecum lesions inoculated score in boiler chickens.

Method: This study was an experimental study using completely randomized design (CRD) with five treatments. Treatment variation is formaldehyde with a concentration of 0%, 0.15%, 0.3%, 0.6%, 1.2%

Results: Results of the study showed that formalin with different concentrations resulted in a significant decrease. Decreasing microscopic cecum lesions inoculated score in boiler chickens in each treatment 0%, 0.15%, 0.3%, 0.6% and 1.2% were 10.32; 9.86; 7.00; 5.14; 4.98 respectively. The largest decrease in lesion score was at 1.2%.

Conclusion: Formalin with 1.2% concentration could reduce cecum lesions inoculated score in boiler chickens

Keywords: Formalin, *E. tenella*, Caecum of boiler chicken, Attenuation

Introduction

Chicken could get diseases caused by protozoa with high morbidity and mortality. Coccidiosis is one parasitic that cause disease especially in caecum of digestive tract, resulting almost 80-90% morbidity and mortality¹. In addition, this disease could also cause decreasing egg production, body weight and increasing in medical expenses². Economic losses due to coccidiosis in United States between 450 million dollars to 1.5 billion US dollars³. Coccidiosis is one among all diseases always occurs in every period of chicken maintenance⁴.

Various ways to control coccidiosis have been carried out, but not yet fully successful. Maintenance with good sanitation can break *Eimeria* development cycle, but this method is still not fully able to prevent occurrence of coccidiosis. It is caused by the small size of the oocyst can contaminate water, feed, and cage equipment. Residue in meat also could endanger consumers⁶. One effective action is using a vaccine that induce immunity. Live vaccine is giving immunity in a certain range of time and protecting against infection with pathogenic agents⁷. In coccidiosis, the best type of vaccine to use is an active vaccine, where vaccine functions got protection in live vaccines form⁸.

Formalin is a 37% formaldehyde gas solution and contains methanol as a stabilizer⁹. Coccidiosis vaccine development needs to be explored to prevent infection through various immersion concentrations of *E. tenella* with formalin as a live vaccine in chickens¹⁰. Exploration of optimum immersion time to produce attenuation could induce the most effective protective immunity in chickens. This study aim was to determine formalin

Correspondece Author:

Muchammad Yunus
Departement of Parasitology Veterinary,
Faculty of Veterinary, Airlangga University
Kampus C, Mulyorejo, Kec. Mulyorejo,
Kota Surabaya, Jawa Timur, 60115
Email: muchammadyunusfkunair@yahoo.com

effect and its attenuation optimum concentration on pathogenicity against cecum lesion scores inoculated in boiler chickens.

Method

This study was located in experimental cages, parasitology laboratories and pathology laboratories at the Faculty of Veterinary, Universitas Airlangga, Surabaya. Method used in this study as follow (i) Animals subject used in this study were 25 broiler strains of CP 707 produced by Chaeron Pokphand and aged 21 days. Two-week-old chickens were kept in a battery-powered coop, fed ad libitum and did not contain coccidiostat. Saturated sugar solution, chlorine, distilled water, formalin with concentrations of 0.15%, 0.3%, 0.6% and 1.2%. (iii) Research tools used were battery-powered chicken coop, feed-drink containers, microscope, object glass, cover glass, lab optics, surgical scissors, tweezers, scalpel, centrifuge tube, centrifuge, tray, pot ointment, paper label, tissue paper, stapler, and pipette, micropipette and white chip

Study was an experimental study using complete randomized design (CRD), consist of four treatments. The treatment given is ¹⁾:

Treatment 0: As a control, oocysts was not soaked in formalin and inoculated with 10,000 oocysts.

Treatment 1: *E. tenella* was soaked in formalin with a concentration of 0.15% for 96 hours, then oral inoculated with 10,000 oocysts.

Treatment II: *E. tenella* was soaked in formalin with a concentration of 0.3% for 96 hours, then oral inoculated with 10,000 oocysts orally.

Treatment III: *E. tenella* was soaked in formalin with a concentration of 0.6% for 96 hours, then oral inoculated with 10,000 oocysts.

Treatment IV: *E. tenella* was soaked in formalin with a concentration of 1.2% for 96 hours, then oral inoculated with 10,000 oocysts.

Macroscopic and microscopic scoring was performed on 5th day after inoculation with scoring done macroscopically, cecal abnormalities were noted and degree of damage to mucosal surface of chicken cecum was calculated based on a score of 0-4 ¹² :

Table 1: The Degree of cecal damage in chicken that infected with *E. tenella*

Lesion Score	Description
0	Normal conditions do not indicate a presence of lesion.
+1	Mild lesions, there is a presence of blood patch (ptechie) which spreads slightly on the mucosal surface accompanied by cecum discoloration or the contents of the digestive tract.
+2	Medium level lesions, more bleeding and lesions with a slight thickening of the cecum wall.
+3	Severe lesions, characterized by severe bleeding and blood clots.
+4	Very severe lesions, characterized by very intense and widespread bleeding, the presence of bluish red clot in the cecum that indicates the presence of blood clots.

Histopathological observations were based on total values A and B, where A represents the distribution of *E. tenella* presences found in the cecum mucosa in the histopathological preparation as described below ^{13,14}:

Table 2: The Distribution of *E. tenella* presence found in the cecum mucosa in histopathological preparations

Lesion Score	Description
0	There are no parasites in the sub epithelial part.
+1	If in 10 visual fields in the sub-epithelium there are 1 parasite.
+2	If in 10 visual fields in the sub-epithelium there are 2 parasites.
+3	If in 10 fields of view in the sub-epithelium there are 3 parasites.
+4	If in 10 fields of view in the sub epithelium there are 4 parasites.

While B represents cecal damage severity caused by *E. tenella* as described below ¹³:

Table 3: The Severity damaged villi in caecum caused by *E. tenella*

Lesion Score	Description
0	If the severity due to parasitic infection in the villi is 0% at 10 fields of view.
+1	If the severity due to parasite infection in the villi is <25% at 10 fields of view.
+2	If the severity due to parasitic infection in the villi is 25-50% at 10 fields of view.
+3	If the severity due to parasitic infection in the villi is 51-75% at 10 fields of view.
+4	If the severity of infection of the villi parasites is > 75% at 10 fields of view.

Quantitative analysis was used in this study from scores and statistically analyzed using Spearman correlation test

Result

Based on macroscopic and microscopic observations, score data of cecal damage in *E. tenella* inoculation were different between treatment groups. Calculation score lesion on boiler chicken caecum, based on average results of macroscopic and microscopic scoring on each treatment.

Table 4: Scores of chicken caecum lesions that inoculated with *E.tenella* and were soaked using several formalin concentrations and infected with each group of chicken with a dose of 1×10^4 oocyst of *E. tenella*

Treatment group	Cecum score based on Macroscopic observation $X \pm SD$	Cecum Lesion score based on Macroscopic observation $X \pm SD$
P ₀	1,8 ^a ± 0,447	10,32 ^a ± 0,487
P ₁	1,8 ^b ± 0,447	9,86 ^b ± 0,182
P ₂	1 ^c ± 0	7,00 ^c ± 0,339
P ₃	0,6 ^d ± 0,547	5,14 ^d ± 0,207
P ₄	0,6 ^d ± 0,547	4,98 ^d ± 0,239

Description: Different letter transcripts show significant differences

Macroscopic and microscopic mean value of boiler chicken caecum lesions score showed a significant difference. In macroscopic scoring, caecum lesion score decreased with increasing formalin concentration. However, treatment concentration of 0.6% and 1.2% did not show a significant result of 0.547. The biggest decrease in the lesion score was in treatment group of 0.6% and 1.2% with value of 0.6.

Microscopic observation scoring showed a significant decreasing in lesion scores between treatments on boiler chicken caecum along with increasing in formalin concentration. Decreasing in lesion scores in treatment concentration of 0%, 0.15%, 0.3%, 0.6% and 1.2% were 10.32; 9.86; 7.00; 5.14; 4.98 respectively. The biggest decrease in lesion score was in the addition treatment concentration of 1.2%

Results of chicken caecum obtained from image observation macroscopically. Picture showed degree of image of each treatment due to *E.tenella* inoculation can be seen in Figure 1.

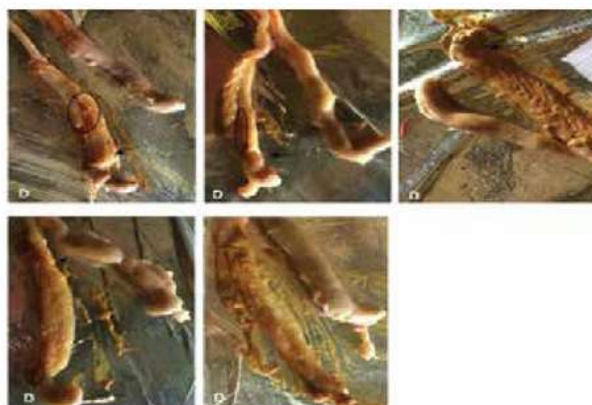


Figure 1: Macroscopic image of chicken caecum inoculated with *E. tenella* soaked using several formalin concentrations [0% (P0); 0.15% (P1); 0.3% (P2); 0.6% (P3); 1.2% (P4)]

Intensity of pteciae was reduced by immersion in formalin with higher concentrations. Circle showed bleeding in the mucosa and arrows for thickening of the mucous cecum. Picture was taken using an iPhone 5s camera.

Histopathological picture showed degree 3 damage of each treatment due to *E.tenella* inoculation can be seen in Figure 2.

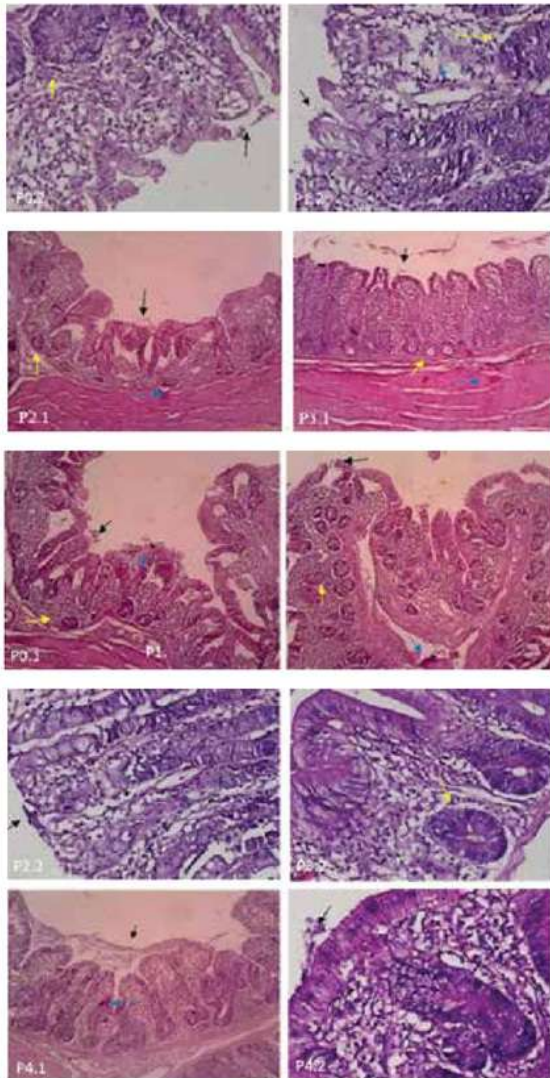


Figure 2: Histopathological description of chicken cecum inoculated with *E. tenella* and soaked using several formalin concentrations [0% (P0); 0.15% (P1); 0.3% (P2); 0.6% (P3); 1.2% (P4)]

Description: ↑ showing ruptured cecum villi, ↓ showing bleeding, ♀ showing *E. tenella* oocyst; (0.1 - 4.1, 100x magnification; 0.2 - 4.2, 400x magnification).

Discussion

Chemicals for *E.tenella* attenuation in vaccines usually using chemicals that can cause antigen changing responsible for stimulating protective immunity. Formalin reacts with amino and amide groups in proteins. Amino bonds are bound to non-water substances with basic ingredients of purine nucleic acids and pyrimidines forming cross-bonds and provide structural rigidity in the organism. Structural rigidity of organism will result in cell death, could reduce virulence of the organism. Organism could lives but not potent enough to cause disease and has large influence to improve antibodies¹⁵. Formalin will react chemically with almost all substances in cell thereby suppressing cell function and causing cell death¹⁶. Formalin is also a source of reactive oxygen compounds (ROS) and oxygen free radicals¹⁷. Safe threshold of formalin in chicken bodies according to International Program on Chemical Safety (IPCS) in liquid form is 1 mg/l¹⁸.

E. tenella infection phase in the cecum is at sporozoite stage penetrates epithelial cells in cecum villi and crypta. After in cecal epithelium, parasite develops asexually and sexually. This development results in damage to cecal epithelial cells due to schizont ruptured which liberated merozoites. Larger size and increasing amount of *E. tenella* that infects cecum could increase cecal epithelial erosion, and vice versa¹⁹. In previous study, it was resulting a decrease in number and precocious lines²⁰. It caused a decrease in the cecal epithelial erosion score in each treatment group. Formalin could denaturate protein enzymes, and causing enzyme structures changing. It inhibits enzyme activity and unable to catalyze metabolic processes in cells, causing microorganisms weaken and inhibit schizont process²¹. Inhibition of schizont process results in decreased opportunities for reproduction and lesions will decrease. Formalin is able to react with *E. tenella* oocysts because its outer layer wall consists of protein and inner layer consists of fat, related to protein. Formalin could easily binds to protein²², able to make organism cell dehydrated and resulting in structural rigidity²³

Macroscopic observation of the cecum at P0 showed a moderate damage, characterized by more bleeding and lesions with a slight thickening of cecum wall. This was supported by clinical symptoms as chickens look limp, tangled chicken feathers, decreased appetite. P1 showed moderate level cecal lesions, characterized by more bleeding and lesions with a slight thickening of the cecum

wall. P2 showed mild cecal lesions, some bleeding that spreads to mucosal surface of cecum with slight changes in wall color or digestive tract content. P3 showed mild cecal lesion, some bleeding that spreads to mucosal surface of cecum with slight changes in wall color or contents of digestive tract. P4 showed mild cecal lesions, some bleeding spreads to mucosal surface of cecum with slight changes in wall color or contents of digestive tract¹². Conclusion of above discussion shows that optimal formalin concentration for attenuating *E. tenella* in terms of macroscopic aspect was 1.2%. It showed a mild degree damage to cecum mucosa. Inoculation at doses of 1000-3000 Oocysts of *E.tenella* could cause bleeding and other characteristics caused by infection²⁴. *E. tenella* infection causes lesions in cecum that cause bleeding and diarrhea²⁵. Inoculation at treatment with 1.2% formalin, there were several bleeding spreads to mucosal surface of cecum with slight discoloration wall or contents of the digestive tract¹².

Histopathological observations in microscope on the cecum, based on P0 image, there was a lot of damage to the cecum mucosa and development of parasites, cecal epithelium was not compact, and many ruptured cecum villi were found. P1 showed histopathological abnormalities with mucosal damage and discovery of clear parasites development in several parts. Cecal epithelium did not appear to be compact, and cecum villi that rupture was found in several parts. P2 values indicate histopathological abnormalities with mild degrees damage to mucosal cecum. Cecal epithelium appeared to be compact, rupture of cecum villi was rarely found and development of parasites also minimum. Value of the microscopic scoring on P3 showed almost no abnormalities in the histopathology of cecum. Cecal epithelium appeared to be compact and ruptured cecum villi was rarely found. P4 shows cecum cell tend to be normal, cecal epithelium appeared patchy and almost did not show any villi rupture¹⁴. Other studies have obtained results on microscopic examination of chicken cecum infected with 5000 oocysts that shows cell necrosis, degeneration, thickening of the muscularis layer, inflammatory cell infiltration, presence of parasites surrounded by inflammatory cells and bleeding²⁶.

Conclusion

Based this result study, we can conclude that formalin can attenuate *E. tenella* in cecum of broiler

chicken. There was a difference in the attenuation degree of *E. tenella* in each formalin concentration. The optimal formalin concentration for attenuate *E. tenella* in terms of macroscopic and microscopic features of broiler chickens was 1.2%.

Ethical Clearance: This study procedure used test animals were approved with the principles of ethical research based on research ethics committee rules. This study applied the basic principles of replacement, reduction and refinement.

Conflict of Interest: The author reports no conflict of interest of this work.

Source of Funding: This study is done with individual funding.

REFERENCES

1. Retno, FD.,Jahja, J., Suryani T. Penyakit Penting Pada Ayam. 4th ed. Bandung, Indonesia: Medion; 1998.
2. Kabbay M. Coccidiosis in Poultry. Veterinary Pathologist Animal Health Laboratories. Western Australia; 2006.
3. Kim M-K, Lee J-A, Jo M-R, Kim M-K, Kim H-M, Oh J-M, et al. Cytotoxicity, Uptake Behaviors, and Oral Absorption of Food Grade Calcium Carbonate Nanomaterials. *Nanomaterials* [Internet]. 2015;5(4):1938–54. Available from: <http://www.mdpi.com/2079-4991/5/4/1938/>
4. Tabbu C. Penyakit Ayam dan Penanggulangannya. 6, editor. Yogyakarta, Indonesia: Kanisius; 2006. 3-25 p.
5. Juandi. Patogenitas Infeksi Sporokista Eimeria tenella Ditinjau dari Skor perlakuan sekum ayam. Universitas Airlangga Indonesia; 2002.
6. Harismah A. Pengaruh Pemberian Ekstrak Sambilotto Dengan Pelarut Air Dosis Bertingkat Terhadap Jumlah Skizon, Makrogamet, Mikrogamet Dan Ookista Eimeria Tenella Pada Sekum Ayam. Intitut Pertanian Bogor Indonesia; 2006.
7. Meeusen ENT, Walker J, Peters A, Pastoret PP, Jungersen G. Current status of veterinary vaccines. *Clin Microbiol Rev.* 2007;20(3):489–510.

8. Yunus M. Pengaruh Berbagai Dosis Infeksi Sporokista *Eimeria tenella* Terhadap Gambaran Sekum, Leuosit dan Produksi Ookista Pada Ayam Pedaging. Universitas Airlangga Indonesia; 2001.
9. Pelczar, M.J. dan Chan ECS. Dasar-dasar Mikrobiologi Jilid 2. Jakarta, Indonesia: UI Press; 2006.
10. Proyowidodo D. Efektifitas Pemberian Vaksin Koksidiosis Melalui Air Minum Dan Pakan Terhadap Infeksi Tantangan *Eimeria tenella*. *J Sains Vet*. 2005;1:1-2.
11. Kadhim LI. Histopathological Changes of Broilers Immunized With Sonicated Oocyst Against *Eimeria tenella*. *Int J Adv Biol Res*. 2014;4(1):31-5.
12. Raman M, Banu S., Gomathinayagam S, Raj GD. Lesion scoring technique for assessing the virulence and pathogenicity of Indian field isolates of avian *Eimeria* species. *Vetrinarski Arh*. 2011;81(2):259-71.
13. Goodwin, MA, JB and DI. Use of Microscopic lesion score, gross lesion score and oocyst count score to detect *Eimeria maxima* in Chickens. England; 2012. 405-408 p.
14. J.Orengo, A.J.Buendía, M.R.Ruiz-Ibáñez, J.Madrid, L.Del Río, P.Catalá-Gregori, V.García FH. Evaluating the efficacy of cinnamaldehyde and *Echinacea purpurea* plant extract in broilers against *Eimeria acervulina*. *Vet Parasitol*. 2012;185(2-4):158-63.
15. Tizard. *Veterinary Immunologi an Introduction*. 7th ed. USA: Saunders; 2004.
16. Cahyadi. W. Analisis dan Aspek Kesehatan Bahan Tambahan Pangan. 2nd ed. Jakarta, Indonesia: Bumi Aksara; 2009. 134 p.
17. Mahdi, C., & Mubarak AS. Uji kandungan Formalin, Borak dan Pewarna Rhodamin pada Produk Perikanan dengan Metode Spot Test. *Berk Ilm Perikan*. 2008;62-6.
18. Wisnu C. Analisis dan Aspek Kesehatan Bahan Tambahan Pangan. Jakarta, Indonesia: Bumi Aksara; 2006. 202-205 p.
19. Quiroz-Castañeda RE, Dantán-González E. Control of avian coccidiosis: Future and present natural alternatives. *Biomed Res Int*. 2015;2015.
20. Shirley MW, Bedrník P. Live Attenuated Vaccines against Avian Coccidiosis. *Parasitol Today*. 1997;13(12):481-4.
21. Perkins J. *Principles and Methods Sterilization in Health Sciences* Publisher. 2nd ed. Charles C. Thomas, editor. Springfield, USA: Illinois; 1980.
22. Kusumawati I. Penetapan Kadar Formalin. Surakarta, Indonesia: Universitas Muhammadiyah Surakarta; 2006. 163 p.
23. Kausyar A. Pengaruh Pemberian Infus Daun Andong (*Cordyline Friticosa* L) Terhadap Jumlah Skizon, Mikrogamet, Makrogamet Dan Ookista Pada Ayam Setelah Diinfeksi *E. tenella*. Institut Pertanian Bogor Indonesia; 2002.
24. Hofstad, MS., BW. Calnek., CF., Helmboldt., WM. Reid and H yod J. *Disease of Poultry*. 7th ed. London: Barllere Tidal; 1978. 759-805 p.
25. Ugurhart, GM., J. Armour. JD and FJ. *Veterinary Parasitology*. Schotland: Logman Scientific and Technical; 1990.
26. Suprihati, E. M dan R. W. Kajian Histopatologis pada Sekum Anak Ayam Akibat Pemberian Sporokista *Eimeria tenella*. *J Univ Airlangga [Internet]*. 2000; Available from: <http://journal.unair.ac.id/filerPDF/Endang.pdf>

the Potency of Formalin in Atenuation of Pathogenicity in Eimeria Tenella at the Caecum of Broiler Chicken

ORIGINALITY REPORT

5%

SIMILARITY INDEX

5%

INTERNET SOURCES

2%

PUBLICATIONS

3%

STUDENT PAPERS

PRIMARY SOURCES

1

Submitted to Universitas Airlangga

Student Paper

2%

2

repository.unair.ac.id

Internet Source

1%

3

docplayer.net

Internet Source

1%

4

bbs.civilcn.com

Internet Source

1%

5

journal.unair.ac.id

Internet Source

<1%

Exclude quotes Off

Exclude matches Off

Exclude bibliography On