

## Case Report

### Exploring unusual metastasis in carcinoma breast: Divulging vulval metastasis

Kanyadhara Lohita Krishna<sup>1</sup>, B.S. Srinath<sup>1</sup>, M. S. N. Prasad<sup>2</sup>, M.S. Sulakshana<sup>2</sup>, Sariya Mohammadi J<sup>1</sup>, Vishnu Kurpad<sup>1</sup>, Sanjeev Kulkarni<sup>1</sup>, Prabhat Yaji<sup>1</sup>, Sandeep Goud<sup>1</sup>, Subhashini Dhanireddy<sup>1</sup>

From <sup>1</sup>Department of Breast Surgery, <sup>2</sup>Department of Pathology, Sri Shankara Cancer Hospital and Research Centre, 1<sup>st</sup> Cross Shankarapuram, Basavangudi, Bangalore, Karnataka, India.

**Correspondence to:** Dr. Kanyadhara Lohita Krishna, Department of Breast Surgery, Sri Shankara Cancer Hospital and Research Centre, 1<sup>st</sup> Cross Shankarapuram, Basavangudi, Bangalore - 560004, Karnataka, India. E-mail: lohitaklkc@gmail.com

Received - 14 October 2019

Initial Review - 30 October 2019

Accepted - 12 December 2019

#### ABSTRACT

Regional lymph nodes, bones, brain, lung, and liver are the most common sites of the breast carcinoma metastases. Nodular or ulcerated lesions over the vulva are ignored for a long time as benign lesions by the patient and there is a lot of hesitance to undergo the examination. Here, we report the case of a 41-year-old female with an isolated, asymptomatic vulval metastasis of Invasive ductal carcinoma of the breast. The purpose of reporting this case is to make the clinicians aware of this rare site of metastasis of breast cancer and the importance of pelvic examination in follow-up patients.

**Keywords:** Breast cancer, Ductal carcinoma, Lobular carcinoma, Recurrence, Vulval metastasis.

Breast carcinoma is the most commonly diagnosed malignancy among females and it is one of the leading causes of death [1]. Invasive duct breast carcinoma and invasive lobular breast carcinoma are the two most common histological subtypes. Invasive ductal carcinoma (IDC) accounts for 60–75% of all tumors, while invasive lobular carcinoma (ILC) accounts for 10–15% of all tumors [2]. M Harris et al. in 1984 studied the metastatic pattern of these two histological subtypes and concluded that IDC commonly metastasizes to lung parenchyma while ILC metastasizes to peritoneum/retroperitoneum [3]. Based on molecular subtypes, luminal A commonly metastasizes to viscera followed by bone and luminal B to bone followed by viscera [4].

Primary carcinoma of the vulva is the 4<sup>th</sup> most common gynaecological malignancy and 95% of them are squamous cell carcinoma [5]. Metastatic disease to the vulva is even less common [6]. We present the case of a 41-year-old female with an isolated, asymptomatic vulval metastasis of IDC of the breast.

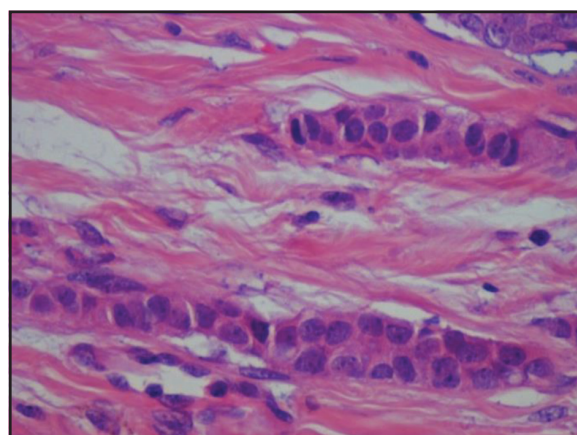
#### CASE REPORT

A 41-year-old female underwent the right breast conservation surgery in January 2014 at the age of 36 years. Histopathological examination of the lesion revealed a grade 2, 3.5x3.0cm invasive ductal carcinoma with perineural tumour invasion and 4 of 23 axillary lymph nodes were positive for the disease (Fig. 1). Estrogen and progesterone-receptor positive, Her 2 neu negative and high Ki-67%. She underwent adjuvant chemotherapy in the form of doxorubicin and cyclophosphamide for four cycles followed by four cycles of docetaxel. She also received adjuvant

radiation therapy of 45 Gray in 25 fractions over 5 weeks to the chest wall along with a booster dose of 20 Gray in 10 fractions followed by hormone therapy (20mg tamoxifen OD). She had no evidence of the disease for nearly 4 years with regular surveillance. The patient being young, pre-menopausal was offered BRCA 1/2 testing at the time of her primary breast cancer but declined due to economic constraints.

In December 2017, the patient presented with complaints of irregular bleeding per vagina. The clinical examination revealed an approximately 1cm nodule over the right labium majora which was kept under observation. Further follow-up physical examination revealed multiple nodules over labium majora and labium minora (Fig. 2).

The patient underwent an incisional biopsy of the right labial nodules showing tumour arranged in singles, cords and small



**Figure 1:** Histopathological examination of the right breast (in 2014).

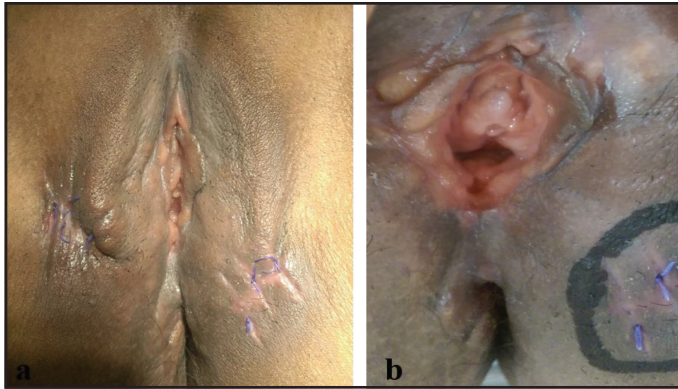


Figure 2: (a) and (b) Multiple Nodules over Labia Majora and Minora.

dyscohesive clusters composed of cells with a moderate amount of eosinophilic cytoplasm. Immunohistochemistry (IHC) markers Pan CK, GCDFP 15 and CK 7 were positive and Mammoglobin and CK 20 were negative in tumour cells. A whole-body F Fluoro-deoxyglucose positron emission tomography-computed tomography (PET-CT) revealed multiple hypermetabolic lesions in the right vulva with no evidence of regional or distant metastases.

The patient then underwent right hemivulvectomy with wide excision of the left labia majora and minora nodules. Final surgical pathology was consistent with metastasis from a known breast primary (Fig. 3). Estrogen and progesterone-receptor were strongly positive and Her 2 neu was negative. Postoperatively since the patient had progressive disease on hormone therapy, she was initiated on second-line chemotherapy with 4 cycles of vinorelbine (40mg/m<sup>2</sup>) and Cisplatin (60mg/m<sup>2</sup>) followed by local radiotherapy after discussing with the multidisciplinary tumour board.

## DISCUSSION

The precise route of spread of the breast carcinoma to the vulva is unclear; however, during the 5<sup>th</sup> week of embryological development, there is a formation of primitive milk streak which shortly forms the mammary ridge which extends from the axilla to the groin and later regresses after the formation of the breasts [7].

There are cases of primary breast carcinoma of the vulva (presence of in-situ or normal breast tissue in vulva specimen) reported and these should be distinguished from the vulvar metastasis of the breast cancer (identical histological and hormone receptor patterns between the breast and vulvar lesion) [8]. Ectopic breast tissue is often seen along this milk line and there have been cases of breast carcinoma arising from the ectopic breast tissue. Valenzano et al in 2003 reported a case of the breast cancer vulvar metastasis and loco-regional recurrence after rectus abdominis myocutaneous flap reconstruction and hypothesized that this pattern of spread is due to the newly formed lymphatics after surgery [9].

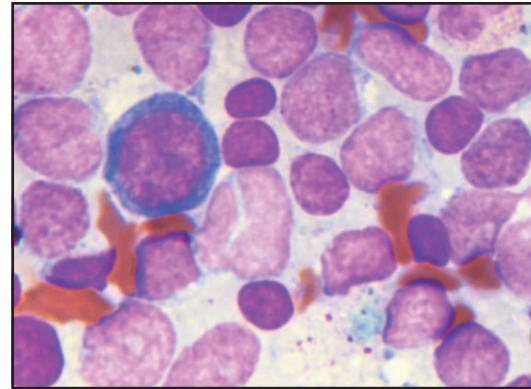


Figure 3: Vulva lesion pathology.

The vulva is an unusual site of metastasis in a known case of breast carcinoma. The most common presentation is a nodular or ulcerated mass lesion over the vulva. Pathological analysis, in this case, confirmed it to be the case of metastases from the breast by the same histology and hormone receptor pattern. Local radiotherapy helps in controlling the disease locally.

Women with this uncommon site of metastasis remain undiagnosed for a long time as they are unaware and feel shy to report it to the doctors. Clinicians should also be aware of this rare site of metastases and make it a point to examine the external genitals on the follow-up of the patient. Once the patient presents with a nodular or ulcerated lesion, she should be asked to be on close follow up, self-examine with the help of a mirror and if there is an increase in size or number, it can be biopsied. In the past 2 years, there were 3 women found to have nodular lesions on routine examination and are on close follow-up.

## CONCLUSION

Gynecological surveillance is recommended in patients with breast carcinoma during follow-up. Also, patients should be educated about this unusual site of metastasis. Along with the self-examination of the breast, any suspicious lesions present on the skin and vulva should be looked for and reported to the clinician.

## REFERENCES

1. Siegel RL, Miller KD, Jemal A. Cancer statistics, 2019. *CA: A Cancer Journal for Clinicians*. 2019;69:7-34.
2. Alligood-Percoco NR, Kessler MS, Willis G. Breast cancer metastasis to the vulva 20 years remote from initial diagnosis: a case report and literature review. *Gynecol Oncol Rep*. 2015;13:33-5.
3. Harris M, Howell A, Chrissohou M, Swindell RI, Hudson M, Sellwood R. A comparison of the metastatic pattern of infiltrating lobular carcinoma and infiltrating duct carcinoma of the breast. *Br J Cancer*. 1984;50:23-30.
4. Savci-Heijink CD, Halfwerk H, Hooijer GK, Horlings HM, Wesseling J, van de Vijver MJ. Retrospective analysis of metastatic behaviour of breast cancer subtypes. *Breast Cancer Res Treat*. 2015;150:547-57.
5. Alkatout I, Schubert M, Garbrecht N, Weigel MT, Jonat W, Mundhenke C, *et al.* Vulvar cancer: epidemiology, clinical presentation, and management options. *Int J Womens Health*. 2015;7:305-13.

6. Neto AG, Deavers MT, Silva EG, Malpica A. Metastatic tumors of the vulva: a clinicopathologic study of 66 cases. *Am J Surg Pathol.* 2003;27:799-804.
7. Sadler TW: Integumentary System. In: Langman's Medical Embryology, 10th ed. Lippincott Williams & Wilkins. Baltimore, MD, pp. 337-338, 1969.
8. Perrone G, Altomare V, Zagami M, Vulcano E, Muzii L, Battista C, *et al.* Breast-like vulvar lesion with concurrent breast cancer: a case report and critical literature review. *In Vivo.* 2009;23:629-34.
9. Valenzano MM, Papadia A, Lorenzi P, Fulcheri E, Ragni N. Breast cancer metastatic to the vulva after local recurrence occurring on a rectus abdominis

myocutaneous flap: a case report and review of the literature. *Eur J Gynaecol Oncol.* 2003;24:577-9.

*Funding: None; Conflict of Interest: None Stated.*

**How to cite this article:** Krishna KL, Srinath BS, Prasad MSN, Sulakshana M.S. Mohammadi JS, Kurpad V, *et al.* Exploring unusual metastasis in carcinoma breast: divulging vulval metastasis. *Indian J Case Reports.* 2019;5(6):579-581.

Doi: 10.32677/IJCR.2019.v05.i06.025