

Expression of p53 protein in Barrett's adenocarcinoma and adenocarcinoma of the gastric cardia and antrum

Ivan Jovanović*, Vera Todorović^{||}, Tomica Milosavljević*, Marjan Micev^{†||}, Predrag Pesko[‡], Miloš Bjelović[‡], Yoannis Mouzas[§], Maria Tzardi[§]

Clinical Center of Serbia, Institute of Digestive Diseases, *Clinic of Gastroenterology and Hepatology, [†]Department of Histopathology, [‡]Department of Esophagogastric Surgery, Belgrade; Institute of Medical Research, ^{||}Department of Experimental Pathology and Cytology, Laboratory for Immunohistochemistry and Electron Microscopy; Belgrade, Serbia and Montenegro; University of Crete, [§]Medical School, Heraclion, Crete, Greece

Background/Aim. Most studies of esophageal and gastric adenocarcinomas have shown a very high rate of p53 gene mutation and/or protein overexpression, but the influence of the tumour site upon the frequency of p53 protein expression has not been evaluated (gastroesophageal junction, Barrett's esophagus, and antrum). The aim of our study was to analyze the correlation between the selected clinico-pathological parameters, and p53 protein overexpression in regards to the particular tumour location. **Methods.** The material comprised 66 surgical specimens; 10 were Barrett's carcinomas, 25 adenocarcinomas of the gastric cardia (type II adenocarcinoma of the esophagogastric junction – EGJ), and 31 adenocarcinomas of the antrum. Immunostaining for p53 protein was performed on formalin-fixed, paraffin-embedded tissue sections, using the alkaline phosphatase – antialkaline phosphatase (APAAP) method. The cases were considered positive for p53 if at least 5% of the tumour cells expressed this protein by immunostaining. **Results.** There was no significant difference observed between the studied groups in regards to age, sex, Lauren's classification and tumour differentiation. There was, however, a significant difference observed in the depth of tumour invasion between Barrett's adenocarcinoma and adenocarcinoma of the cardia compared with the adenocarcinoma of the antrum. Namely, at the time of surgery, both Barrett's adenocarcinomas and adenocarcinomas of the cardia, were significantly more advanced comparing with the adenocarcinomas of the antrum. Overexpression of p53 was found in 40% (4/10) of Barrett's adenocarcinomas, 72% (18/25) of adenocarcinoma of the cardia and 65% (20/31) of adenocarcinoma of the antrum. No significant differences in p53 expression in relation to sex, type (Lauren) of tumour, depth of invasion, lymph node involvement, or tumour differentiation were observed in any of the analyzed groups of tumours. Patients with more advanced Barrett's adenocarcinoma and in the cases of lymph node invasion revealed tendency for the greater p53 positivity compared with the early forms and lymph node-negative cases; however, this difference was not significant according to the statistical analysis. With regard to adenocarcinoma of the cardia, higher rates of p53 positivity were recorded in poorly differentiated, more advanced cases with lymph node invasion. Nevertheless, none of these differences was statistically significant. On the contrary, in the patients with adenocarcinoma of the antrum, greater p53 positivity was revealed in early forms without lymph node involvement, but the observed difference was not statistically significant. **Conclusion.** No significant differences in p53 protein expression in terms of sex, type (Lauren) of tumour, depth of invasion, lymph node involvement, or tumour differentiation were observed in any of the analyzed groups of tumours (Barrett's adenocarcinoma, adenocarcinoma of the cardia and adenocarcinoma of the antrum).

Key words: adenocarcinoma; barrett esophagus cardia; pyloric antrum; protein p53; immunohistochemistry; neoplasm invasiveness, pathology, clinical.

Introduction

Gastric adenocarcinomas comprise a heterogeneous group of tumours. They can occur in the antrum, in the gastric body, and at the esophagogastric junction (EGJ). Adenocarcinomas of the gastroesophageal junction have many features in common with adenocarcinomas of the esophagus. They show a rapidly increasing incidence in most Western countries, a time trend different from those in the distal stomach (1, 2). Both are more common in white males. The ratio of males to females appears to be a little higher for esophageal than for cardia adenocarcinoma, but the difference is of no statistical significance. The age of diagnosis is similar (60–65 years), with a tendency for adenocarcinoma of the EGJ to be diagnosed at a later age. Some authors have reported differences in risk factors, between patients with adenocarcinoma of the EGJ and esophageal adenocarcinoma. There may be a stronger history of smoking and alcohol consumption in patients with adenocarcinoma of the cardia (3). Most of these tumours are diagnosed in advanced stages, and the prognosis is worse than that for carcinomas located in the middle or distal third of the stomach (4, 5).

Esophageal adenocarcinoma develops most often on Barrett's metaplastic mucosa, a condition that arises in about 10% of patients with chronic gastro-esophageal reflux disease. This cancer develops through a histological and biological sequence from metaplasia to dysplasia and eventually through carcinoma (6). While the relationship of the specialized intestinal metaplasia and esophageal adenocarcinoma is well recognized (7, 8), the pathogenesis of specialized intestinal metaplasia in the cardia and its importance in cancerogenesis is still not well defined.

Among the registered genetic abnormalities in oesophageal and gastric adenocarcinomas, allelic losses on chromosome 17p and mutation of the p53 gene have been documented to be frequent events (9–11). p53 is a the tumour-suppressor gene that encodes p53 protein, which allows necessary DNA repairs by slowing down the cell cycle at the G1-S transition, and suppresses tumour growth by inducing apoptosis (12). Among the oncogenes and tumour suppressor genes, p53 is an important one since the mutations of this gene are the most frequent genetic alterations so far identified in human tumours (12, 13). p53 protein expression, either secondary to mutation or adhesion to other cellular or viral proteins, can be detected by immunohistochemistry, and therefore, is an indirect way of analyzing the functional status of p53 gene. As such, the accumulation of p53 protein may be considered an indicator of p53 mutation (14). The nuclear accumulation of p53 protein has been detected in a variety of malignant tumours including Barrett's adenocarcinoma and gastric cancer and the relationship between p53 overexpression and poor prognosis has been reported (9–11, 14).

Most studies of esophageal and gastric adenocarcinomas have shown a very high rate of p53 gene mutation

and/or protein overexpression, but the influence of the tumour site upon the frequency of p53 protein expression has not been evaluated in most of the published studies. The aim of our study was to analyze the correlation between the selected clinico-pathological parameters and p53 protein overexpression in regards to particular tumour location.

Methods

Patients and tissues

The material comprised 66 surgical specimens which were retrieved from the files of the Department of Histopathology of the First Surgical Clinic of Clinical Center of Serbia, Belgrade, during a 4-year period (1997–2000). Ten surgical specimens were collected from the patients with Barrett's carcinoma, 25 from the patients operated for adenocarcinoma of the gastric cardia (type II adenocarcinoma of the EGJ), and 31 surgical specimen from the patients operated for adenocarcinoma of the antrum. Adenocarcinoma of the cardia was defined as a tumour with a center located within 2 cm of the esophagogastric junction, with no surrounding metaplastic mucosa detected preoperatively or on gross examination of the surgical specimen (15). The Lauren's histological classification of gastric carcinoma (16), as well as the evaluation of tumour differentiation were performed.

Immunohistochemistry

Immunostaining was performed on formalin-fixed, paraffin-embedded 5 μ m tissue sections, using the alkaline phosphatase – antialkaline phosphatase (APAAP) method. The anti-p53 monoclonal antibody (M 7001, DAKO A/S, Glostrup, Denmark), (dilution 1/10) were also used. The bridging rabbit antimouse (Z259) (dilution 1/50) and APAAP complexes (D651) (dilution 1/50) were obtain also from Dako. A stage of microwave heating in a solution of sodium citrate (0.1M, pH = 6) was performed prior to incubation with primary antibody.

For negative controls the primary antibody was omitted and for positive controls a Barrett's adenocarcinoma with positive immunostaining as well as gastric cardia and antrum adenocarcinoma were included with each batch.

The cases were considered positive for p53 if at least 5% of the tumour cells expressed this protein by immunostaining. Nuclear expression was considered positive for p53 and protein immunoeexpression was counted in 20 randomly selected fields at $\times 40$ magnification.

Statistical analysis

Statistical analysis was performed with the SPSS program for Windows (6.0, 1993), using the χ^2 test. The Fisher's test was used when there were fewer than five cases in one group included in the table for statistical evaluation. The results were considered statistically significant when $p < 0.05$.

Results

Table 1 shows the major pathological features of resected tumours. There was no significant difference ob-

clear staining of 5% or more of tumour cells) was found in 40% (4/10) of Barrett's adenocarcinomas (Figure 1), 72% (18/25) of cases of adenocarcinoma of the cardia, and 65% (20/31) of adenocarcinoma of the antrum.

Table 1

Major pathological features of the resected tumours			
	Barrett's adenocarcinoma (n = 10)	Adenocarcinoma of the cardia (n = 25)	Adenocarcinoma of the antrum (n = 31)
Age	58.89 (44–80)	61.4 (39–72)	56 (31–77)
Sex			
Male	9	18	18
Female	1	7	13
Lauren			
Intestinal	9	18	22
Diffuse	1	2	7
Mixed	0	5	2
Depth			
T1, T2	4	11	24
T3, T4	6*	14*	7*
Lymph nodes			
Negative	2	5	4
Positive	8	20	27
Grade			
Well	0	1	3
Moderate	8	10	9
Poor	2	14	19

*Barrett vs. Antrum $p < 0.03$; Cardia vs. Antrum $p < 0.01$

served between studied groups in regards to age, sex, Lauren's classification and tumour differentiation. There was a significant difference observed in the depth of tumour invasion between Barrett's adenocarcinoma and adenocarcinoma of the cardia compared to the adenocarcinoma of the antrum. Namely, at the time of surgery, both Barrett's adenocarcinomas and adenocarcinomas of the cardia, were significantly more advanced comparing to adenocarcinomas of the antrum.

Table 2 presents the correlation between p53 immunopositivity and the different clinico-pathological characteristics in regards to tumour location. p53 overexpression (nu-

No significant differences in p53 expression in relation to sex, type (Lauren) of tumour, the depth of invasion, the lymph node involvement, or the tumour differentiation were observed in any of the analyzed groups of tumours. Patients with the more advanced Barrett's adenocarcinoma and in the cases of lymph node invasion revealed the tendency for greater p53 positivity compared with the early forms and lymph node-negative cases; however, this difference was not significant according to the statistical analysis. With regard to adenocarcinoma of the cardia, the higher rates of p53 positivity were recorded in the poorly differentiated, more advanced cases with lymph node invasion. Neverthe-

Table 2

Correlation between p53 positivity and the different clinico-pathological characteristics in regards to the tumour location

	Barrett's adenocarcinoma		Adenocarcinoma of the cardia		Adenocarcinoma of the antrum	
	No. of cases	p53 positive (%)	No. of cases	p53 positive (%)	No. of cases	p53 positive (%)
Sex						
Male	9	33.3	18	66.6	18	77.7
Female	1	10.0	7	85.7	13	46.2
Lauren						
Intestinal	9	44.4	18	61.1	22	72.7
Diffuse	1	0.0	2	100.0	7	57.1
Mixed	–	–	5	100.0	2	0.0
Depth of invasion						
T1, T2	4	25.0	11	63.6	24	66.7
T3, T4	6	50.0	14	78.6	7	57.1
Lymph nodes						
Negative	2	0.0	5	60.0	4	75.0
Positive	8	50.0	20	75.0	27	62.9
Grade						
Well	–	–	1	0.0	3	66.7
Moderate	8	50.0	10	60.0	9	77.7
Poor	2	0.0	14	85.7	19	57.9

less, none of these differences was statistically significant. On the contrary, in the patients suffering from adenocarcinoma of the antrum, greater p53 positivity was revealed in early forms without lymph node involvement, but the observed difference was not statistically significant.

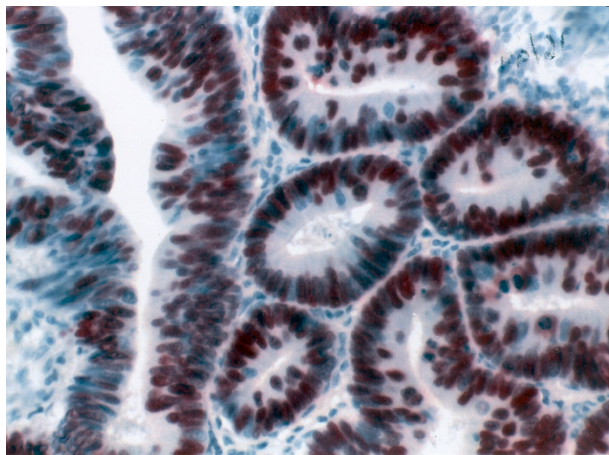


Fig 1. – Overexpression of p53 protein in the well-differentiated Barrett's adenocarcinoma (intestinal type) APAAP, x20

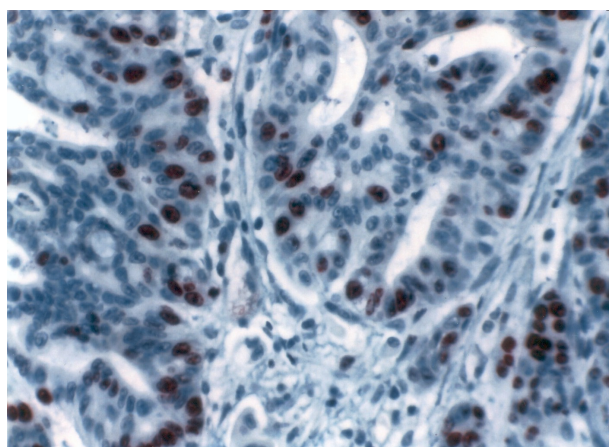


Fig 2 – Overexpression of p53 protein in the moderately differentiated adenocarcinoma of the cardia. APAAP, x20

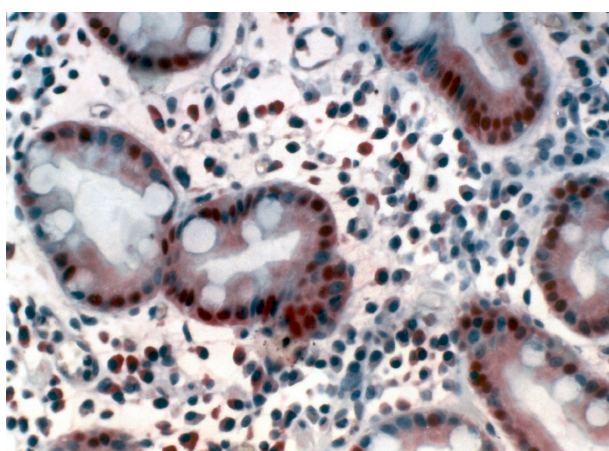


Fig. 3 – Overexpression of p53 protein in the well-differentiated adenocarcinoma of the antrum. APAAP, x20

Discussion

Over the recent decades, there has been an alarming rise in the incidence and prevalence of adenocarcinoma of the esophagogastric junction in the Western world, in contrast with the decreasing prevalence of gastric cancer. It is the consequence, primarily of an increase in rate of adenocarcinoma of the distal esophagus. Nevertheless, the incidence of gastric tumours is shifting from the distal portion of the stomach to the proximal stomach and the gastric cardia. Adenocarcinomas of the esophagus and gastric cardia share similar epidemiological and pathological features (1, 17).

Some investigators believe that carditis and subsequently intestinal metaplasia of the cardiac mucosa are the consequences of repeated injury of the cardiac epithelium by gastric and duodenal content, with duodenal components as the crucial agent (18, 19). The reason why the process is limited to the cardia in some patients while, in others, it involves the esophagus, is due to the competence of the lower esophageal sphincter. On the other hand, histologically and functionally, the antrum and the cardia share similar epithelium (20) with mucus secreting cells and similar local pH that determines the growth behavior of *Helicobacter pylori* (21). So, it is not unreasonable to believe that the inflammatory changes on those sites can have similar consequences regarding the *Helicobacter pylori* infection.

Intestinal metaplasia was found in several studies in the peritumorous mucosa of the gastric cardia tumors, although, it was not always clear whether it has its origin in esophagus or the proximal stomach (8, 22). Thus, it is believed that intestinal metaplasia may have a premalignant potential (23). The pathogenesis of both esophageal and gastric cardia adenocarcinomas is likely to be associated with the specialized intestinal metaplasia. While the relationship of the specialized intestinal metaplasia and esophageal adenocarcinoma is well recognized (7, 8), the pathogenesis of specialized intestinal metaplasia in the cardia and its importance in the cancerogenesis is still not well defined.

Stein et al. have defined adenocarcinoma of the esophagogastric junction as tumours which have their center within 2 cm proximal or distal to the *anatomical cardia* and have differentiated three distinct tumour entities within this area. Barrett's esophagus with the subsequently developed dysplastic changes is the main precursor lesion for adenocarcinoma in the distal esophagus. Type II and III tumours may also rise from the so-called short segments of intestinal metaplasia at or below the cardia, but it happens in less than 40% of patients with carcinoma of the cardia and in less than 10% of those with subcardial carcinoma. These tumours maybe associated with *Helicobacter pylori* and intestinal metaplasia at or below the gastric cardia contrary to the specialized intestinal metaplasia in the distal esophagus that is reflux related (15).

Overexpression of p53 protein is frequently observed in the dysplastic areas and cancer in Barrett's esophagus. It

has been suggested that this is an early event in the dysplasia-carcinoma sequence (6). A number of descriptive molecular studies in esophageal adenocarcinoma has reported on frequency of the mutation of the p53 tumour suppressor gene, and p53 protein overexpression as the most commonly described abnormality. The incidence of p53 mutation tended to increase with the progression along the metaplasia-dysplasia-carcinoma sequence, with the mutation being rare in nondysplastic tissue, but present in up to 90% of esophageal adenocarcinomas (20, 24–26).

On the other hand, studies of p53 alterations in gastric cancer have reported a slight lower frequency of either allelic loss on chromosome 17p, p53 gene mutation, or p53 protein overexpression. p53 overexpression has been detected in 26–65% of gastric adenocarcinoma (27, 28). In most studies, the frequency of p53 protein overexpression was not compared to the location of the tumours.

We investigated the frequency of p53 protein expression in a series of Barrett adenocarcinoma, adenocarcinoma arising in the cardia (type II adenocarcinoma of the esophago-gastric junction) and the gastric antrum. We found no association between p53 protein overexpression and neither tumour stage or histological type nor tumour location. Similar results have been reported in most series of adenocarcinomas of the esophagus and stomach (14, 24, 25). Some studies have shown a higher frequency of p53 alterations in the gastric cancers of the intestinal type (Lauren's classification) when compared with the diffuse type (29), a feature that we were unable to confirm, which might be because of the relatively small number of cases. Furthermore,

in most studies the frequency of p53 alterations was not compared with the tumour location. We revealed the tendency for greater p53 positivity in adenocarcinoma of the cardia and adenocarcinoma of the antrum, than in Barrett's adenocarcinoma; the result that is quite opposite to the previous reports in which greater p53 positivity can be attributed to a more proximal gastric tumours as well as in Barrett's adenocarcinoma (6, 11, 27, 30–33). In the comparative study of p53 alterations in the consecutive series of oesophageal and cardia adenocarcinomas, a high frequency of gene mutation (70% and 63%, respectively), and p53 protein production (70% and 59%, respectively) was observed in both groups of tumours. In respect to the anatomical site of tumours, higher frequency of DNA aneuploidy (34), and lower frequency of microsatellite instability (32, 35), were observed in adenocarcinomas of the cardia and the oesophagus when compared with adenocarcinomas of the antrum. In our study we found no other site specific differences.

The observed clinicopathological parameters were not associated with p53 protein overexpression except at the time of surgery, Barrett's adenocarcinomas and adenocarcinomas of the cardia, both were more significantly advanced comparing to adenocarcinomas of the antrum.

Acknowledgment

This study was supported by the grants from the Serbian Ministry of Science, Technology and Development and Omicron Medical, Hellas (education grant).

REFERENCES

1. *Blot WJ, Devesa SS, Kneller RW, Fraumeni JF Jr.* Rising incidence of adenocarcinoma of the esophagus and gastric cardia. *JAMA* 1991; 265(10): 1287–9.
2. *Powell J, McConkey CC.* The rising trend in oesophageal adenocarcinoma and gastric cardia. *Eur J Cancer Prev* 1992; 1(3): 265–9.
3. *Kalish RJ, Clancy PE, Orringer MB, Appelman HD.* Clinical, epidemiologic, and morphologic comparison between adenocarcinomas arising in Barrett's esophageal mucosa and in the gastric cardia. *Gastroenterology* 1984; 86(3): 461–7.
4. *Rohde H, Bauer P, Stutzer H, Heitmann K, Gebbensleben B.* Proximal compared with distal adenocarcinoma of the stomach: differences and consequences. German Gastric Cancer TNM Study Group. *Br J Surg* 1991; 78(10): 1242–8.
5. *Harrison LE, Karpeh MS, Brennan MF.* Proximal gastric cancers resected via a transabdominal-only approach. Results and comparisons to distal adenocarcinoma of the stomach. *Ann Surg* 1997; 225(6): 678–85.
6. *Jankowski JA, Wright NA, Meltzer SJ, Triadafilopoulos G, Geboes K, Casson AG, et al.* Molecular evolution of the metaplasia-dysplasia-adenocarcinoma sequence in the esophagus. *Am J Pathol* 1999; 154(4): 965–73.
7. *Haggitt RC.* Barrett's esophagus, dysplasia, and adenocarcinoma. *Hum Pathol* 1994; 25(10): 982–93.
8. *Spechler SJ, Goyal RK.* The columnar-lined esophagus, intestinal metaplasia, and Norman Barrett. *Gastroenterology* 1996; 110(2): 614–21.
9. *Souza RF, Meltzer SJ.* The molecular basis for carcinogenesis in metaplastic columnar-lined esophagus. *Gastroenterol Clin North Am* 1997; 26(3): 583–97.
10. *Tahara E, Semba S, Tahara H.* Molecular biological observations in gastric cancer. *Semin Oncol* 1996; 23(3): 307–15.
11. *Flejou JF, Gratio V, Muzeau F, Hamelin R.* p53 abnormalities in adenocarcinoma of the gastric cardia and antrum. *Mol Pathol* 1999; 52(5): 263–8.
12. *Hickman ES, Moroni MC, Helin K.* The role of p53 and pRB in apoptosis and cancer. *Curr Opin Genet Dev* 2002; 12(1): 60–6.
13. *Levine AJ, Momand J, Finlay CA.* The p53 tumour suppressor gene. *Nature* 1991; 351(6326): 453–6.

14. Ireland AP, Clark GW, DeMeester TR. Barrett's esophagus. The significance of p53 in clinical practice. *Ann Surg* 1997; 225(1): 17–30.
15. Siewert JR, Stein HJ. Classification of adenocarcinoma of the oesophagogastric junction. *Br J Surg* 1998; 85(11): 1457–9.
16. Lauren P. The two histological main types of gastric carcinoma: diffuse and so-called intestinal-type carcinoma. An attempt at a histo-clinical classification. *Acta Pathol Microbiol Scand* 1965; 64: 31–49.
17. Craanen ME, Dekker W, Blok P, Ferwerda J, Tytgat GN. Time trends in gastric carcinoma: changing patterns of type and location. *Am J Gastroenterol* 1992; 87(5): 572–9.
18. Oberg S, Peters JH, DeMeester TR, Chandrasoma P, Hagen JA, Ireland AP, et al. Inflammation and specialized intestinal metaplasia of cardiac mucosa is a manifestation of gastroesophageal reflux disease. *Ann Surg* 1997; 226(4): 522–32.
19. Kauer WK, Burdiles P, Ireland AP, Clark GW, Peters JH, Bremner CG, et al. Does duodenal juice reflux into the esophagus of patients with complicated GERD? Evaluation of a fiberoptic sensor for bilirubin. *Am J Surg* 1995; 169(1): 98–104.
20. Toner PG, Cameron CH. The gastric mucosa. In: Whitehead R, editor. *Gastrointestinal and oesophageal pathology*. 2nd ed. Edinburgh: Churchill Livingstone; 1995. p. 15–32.
21. Meyer-Rosberg K, Scott DR, Rex D, Melchers K, Sachs G. The effect of environmental pH on the proton motive force of *Helicobacter pylori*. *Gastroenterology* 1996; 111(4): 886–900.
22. Weston AP, Krmpotich PT, Cherian R, Dixon A, Topalovski M. Prospective long-term endoscopic and histological follow-up of short segment Barrett's esophagus: comparison with traditional long segment Barrett's esophagus. *Am J Gastroenterol* 1997; 92(3): 407–13.
23. Hansson LE, Engstrand L, Nyren O, Evans DJ Jr, Lindgren A, Bergstrom R, et al. *Helicobacter pylori* infection: independent risk indicator of gastric adenocarcinoma. *Gastroenterology* 1993; 105(4): 1098–103.
24. Casson AG, Mukhopadhyay T, Cleary KR, Ro JY, Levin B, Roth JA. p53 gene mutations in Barrett's epithelium and esophageal cancer. *Cancer Res* 1991; 51(16): 4495–9.
25. Ranzani GN, Luinetti O, Padovan LS, Calistri D, Renault B, Burrel M, et al. p53 gene mutations and protein nuclear accumulation are early events in intestinal type gastric cancer but late events in diffuse type. *Cancer Epidemiol Biomarkers Prev* 1995; 4(3): 223–31.
26. Reid BJ, Prevo LJ, Galipeau PC, Sanchez CA, Longton G, Levine DS, et al. Predictors of progression in Barrett's esophagus II: baseline 17p (p53) loss of heterozygosity identifies a patient subset at increased risk for neoplastic progression. *Am J Gastroenterol* 2001; 96(10): 2839–48.
27. Monig SP, Eidt S, Zirbes TK, Stippel D, Baldus SE, Pichlmaier H. p53 expression in gastric cancer: clinicopathological correlation and prognostic significance. *Dig Dis Sci* 1997; 42(12): 2463–7.
28. Rajnakova A, Moomhala S, Goh PM, Ngoi S. Expression of nitric oxide synthase, cyclooxygenase, and p53 in different stages of human gastric cancer. *Cancer Lett* 2001; 172(2): 177–85.
29. Gabbert HE, Muller W, Schneiders A, Meier S, Hommel G. The relationship of p53 expression to the prognosis of 418 patients with gastric carcinoma. *Cancer* 1995; 76(5): 720–6.
30. Shun CT, Wu MS, Lin JT, Chen SY, Wang HP, Lee WJ, et al. Relationship of p53 and c-erbB-2 expression to histopathological features, *Helicobacter pylori* infection and prognosis in gastric cancer. *Hepatogastroenterology* 1997; 44(14): 604–9.
31. Wu TT, Watanabe T, Heitmiller R, Zahurak M, Forastiere AA, Hamilton SR. Genetic alterations in Barrett esophagus and adenocarcinomas of the esophagus and esophagogastric junction region. *Am J Pathol* 1998; 153(1): 287–94.
32. Gleeson CM, Sloan JM, McManus DT, Maxwell P, Arthur K, McGuigan JA, et al. Comparison of p53 and DNA content abnormalities in adenocarcinoma of the oesophagus and gastric cardia. *Br J Cancer* 1998; 77(2): 277–86.
33. Flejou JF, Paraf F, Potet F, Muzeau F, Fekete F, Henin D. p53 protein expression in Barrett's adenocarcinoma: a frequent event with no prognostic significance. *Histopathology* 1994; 24(5): 487–9.
34. Johnson H Jr, Belluco C, Masood S, Abou-Azama AM, Kahn L, Wise L. The value of flow cytometric analysis in patients with gastric cancer. *Arch Surg* 1993; 128(3): 314–7.
35. Muzeau F, Flejou JF, Belghiti J, Thomas G, Hamelin R. Infrequent microsatellite instability in oesophageal cancers. *Br J Cancer* 1997; 75(9): 1336–9.

The paper was received on November 1, 2004.

A p s t r a k t

Jovanović I, Todorović V, Milosavljević T, Micev M, Pesko P, Bjelović M, Mouzas Y, Tzardi M. Vojnosanit Pregl 2005; 62(12): 879–885.

EKOPRESIJA PROTEINA p53 KOD BARRETTOVOG ADENOKARCINOMA I ADENOKARCINOMA KARDIJE I ANTRUMA

Uvod/Cilj. Veliki broj studija pokazao je da postoji visoka stopa mutacije gena p53 i/ili povećana ekspresija proteina p53 kod adenokarcinoma jednjaka i želuca, ali mali broj istraživanja je posvećen uporednim proučavanjima p53 na različitim lokalizacijama ovih tumora (gastroezofagogastrični spoj, Barrettov ezofagus i antrum). Zato je cilj ove studije bio proučavanje korelacije između kliničkopatoloških parametara i prekomerne ekspresije proteina p53 kod adenokarcinoma na navedenim lokalizacijama. **Metode.** Istraživanje je sprovedeno kod 66 bolesnika koji su operisani od Barrettovog adenokarcinoma (n = 10), adenokarcinoma kardije (n = 25, tip II adenokarcinoma ezofagogastričnog spoja) i adenokarcinoma antruma (n = 31). Imunohistohemijsko bojenje metodom alkaline phosphatase – antialkaline phosphatase (APAAP) u cilju dokazivanja preterane ekspresije proteina p53 sprovedeno je na tkivnim presecima hirurških uzoraka tumora fiksiranih u formalinu i ukalupljenih u parafin. Tumori „pozitivni“ na p53 bili su oni kod kojih je više od 5% tumorskih ćelija pokazalo nukleusno imunohistohemijsko bojenje. **Rezultati.** Između ispitivanih grupa bolesnika nije bilo razlika u distribuciji u odnosu na godine, pol, tip tumora po Laurenovoj klasifikaciji, kao i u odnosu na diferentovanost tumora. Međutim, postojala je značajna razlika u dubini tumorske invazije između Barrettovog adenokarcinoma i adenokarcinoma kardije u odnosu na adenokarcinom antruma. Naime, u momentu hirurške intervencije, stadijum tumorske bolesti bio je značajno veći kod Barrett-ovog adenokarcinoma i adenokarcinoma kardije u odnosu na adenokarcinom antruma. Prekomerna ekspresija proteina p53 nađena je kod 40% (4/10) slučajeva Barrettovog adenokarcinoma, 72% (18/25) slučajeva adenokarcinoma kardije, kao i kod 65% (20/31) bolesnika sa adenokarcinomom antruma. Nije bilo razlika u pogledu ekspresije proteina p53 između ispitanika različitih grupa u odnosu na ispitivane kliničko-patološke parametre: starost, pol, tip tumora, invazivnosti, zahvaćenost limfnih nodusa i diferentovanost tumora. **Zaključak.** Između bolesnika sa Barrettovim adenokarcinomom, adenokarcinomom kardije i adenokarcinomom antruma nema razlika u prekomernoj ekspresiji proteina p53 u odnosu na starost, pol, tip tumora, invazivnosti, zahvaćenost limfnih nodusa i diferentovanost tumora.

K l j u č n e r e č i : adenokarcinom; jednjak, Barrett; kardija; pilorus; protein p53; imunohistohemija; neoplazme, invazivnost; patologija, klinčka.