



# Pakistan Veterinary Journal

ISSN: 0253-8318 (PRINT), 2074-7764 (ONLINE)

Accessible at: [www.pvj.com.pk](http://www.pvj.com.pk)

## RESEARCH ARTICLE

### Ultrasound Imaging of Testes and Epididymides of Normal and Infertile Breeding Bulls

Khalid Mahmood Ali, Nazir Ahmad\*, Nafees Akhtar, Shujait Ali, Maqbool Ahmad and Muhammad Younis<sup>1</sup>Department of Theriogenology, University of Agriculture, Faisalabad; <sup>1</sup>Semen Production Unit, Qadirabad, District Sahiwal, Pakistan\*Corresponding author: [profnazir53@hotmail.com](mailto:profnazir53@hotmail.com)

#### ARTICLE HISTORY

Received: May 30, 2011

Revised: June 11, 2011

Accepted: June 13, 2011

#### Key words:

Buffalo

Cattle

Fertile Bulls

Infertile Bulls

Ultrasonography

#### ABSTRACT

Echotexture of testes and epididymides from 10 slaughtered male buffaloes was studied. Diameter of testis and mediastinum testis was measured by ultrasound and compared with respective values taken by calipers. Testes and epididymides of another 10 fertile and 10 infertile breeding bulls were examined *in vivo* through manual palpation and ultrasound imaging. Semen quality of these bulls was also monitored. There were significant ( $P < 0.01$ ) positive correlations between ultrasound and calipers values of all parameters. The testicular parenchyma of fertile bulls was uniformly homogeneous and moderately echogenic. Epididymal tail was more heterogeneous and less echogenic, while epididymal head was homogeneous and less echogenic, than the testicular parenchyma. The epididymal body appeared as hypoechoic structure with echogenic margin. Among 10 infertile bulls, nine had poor semen quality, while one bull failed to give any ejaculate. On ultrasonography, six bulls showed abnormalities in their scrotal echotexture. Among these, one had an abundance of hyperechoic areas scattered in the testicular parenchyma, some of these showed acoustic shadowing, showing testicular degenerations with mineralization. The second bull showed many anechoic areas in the testes and epididymal head, demarcated from the rest of the organ by well defined margins. In the third bull, three-fourth of the right testis showed hyperechoic areas, suspected of testicular degeneration with mineralization. The fourth bull had two anechoic areas in one testis assumed to represent dilated blood vessel. The fifth bull showed small hyperechoic areas within the testicular parenchyma. The sixth bull showed an anechoic area with distinct hyperechogenic margin below the testicular tunics. The remaining four bulls had normal echogenicity of testes and epididymides in spite of poor semen quality. In conclusion, diagnostic ultrasound may be included in breeding soundness examination of breeding bulls.

©2011 PVJ. All rights reserved

**To Cite This Article:** Ali KM, N Ahmad, N Akhtar, S Ali, M Ahmad and M Younis, 2011. Ultrasound imaging of testes and epididymides of normal and infertile breeding bulls. *Pak Vet J*, 31(4): 345-350.

#### INTRODUCTION

Diagnostic methods of assessing the health of the bull testis and related structures mainly include manual palpation, measurement of scrotal circumference, testicular diameter and evaluation of semen. Other methods like thermography, tonometry and biopsy could not prove their worth in veterinary medicine.

In men, diagnostic ultrasound has been used for the diagnosis of several types of testicular and epididymal lesions viz: occult neoplasms (Hendry *et al.*, 1984), cystic lesions (Leung *et al.*, 1984), epididymitis (Yin and Trainor, 2009) and orchitis (Bird and Rosenfield, 1984). It is also helpful to aid diagnosis in testicular torsion,

cryptorchidism, scrotal hernia, varicocele and follow-up of testicular microlithiasis (Karmazyn, 2010). In animal reproduction, it is almost exclusively used in the female for early pregnancy diagnosis (Anwar *et al.*, 2008), monitoring morphological and physiological changes of the ovaries and tubular genital tract, and for the diagnosis of pathological lesions of these organs (Hinkeldey and Hopkins, 1996).

Diagnostic ultrasound seems to be the best technique for the evaluation of scrotal contents, which are ideally suited for this type of examination because of their general superficial location. It is very useful in confirming the presence or absence of a mass, as the homogeneous echo pattern of the normal testis serves as a good

background for the detection of small intratesticular focal lesions; the size of which can also be measured accurately. In many cases, it can give a specific diagnosis. With this technique, it is also possible to differentiate between solid and cystic enlargements. A negative ultrasound scan can be fairly safely assumed to exclude the presence of any abnormality. It may also be used as a guide for a definitive biopsy or surgical exploration.

The present paper describes semen quality and the gross and ultrasonographic appearance of scrotal contents of fertile and infertile breeding bulls *in vivo*. Moreover, values of the diameter of the testis and the mediastinum testis taken by calipers have been compared with those taken through ultrasonography in organs from slaughtered animals.

## MATERIALS AND METHODS

### Examination of organs from slaughtered animals

Testes along with epididymides, collected from 10 adult male buffaloes slaughtered at the local abattoir, were examined for gross lesions, if any. Diameter of each testis from surface to surface and from border to border was measured with the help of vernier calipers. Then these organs were imaged ultrasonically, using a B-mode, real time ultrasound scanner fitted with a 5.0 MHz convex array transducer. The diameter of each testis from surface to surface and from border to border, as well as diameter of the mediastinum testis, was also measured with the help of ultrasound. After ultrasound imaging, each testis was sectioned transversely (Fig. 1) and the diameter of the mediastinum testis was recorded with the help of vernier calipers.

### *In vivo* testis size measurements

Ten fertile and 10 infertile buffalo/cattle breeding bulls, aged between 4 and 16 years and maintained at the Semen Production Unit, Qadirabad, District Sahiwal, were used for *in vivo* studies. Testicular measurements were made while bulls were restrained in standing position. The testes were brought into the distal part of scrotum and the greatest scrotal circumference was measured with the help of a flexible measuring tape.

### Semen collection and evaluation

Semen from experimental bulls was collected with the help of an artificial vagina. Two ejaculates from each animal were collected, pooled immediately after collection and examined for physical characteristics, including volume, sperm concentration, sperm motility

and percentages of dead and morphologically abnormal spermatozoa, using standard procedures.

### Ultrasound imaging

After palpation of the testis and epididymis, the ultrasound imaging of testis and related structures of all the experimental bulls was carried out, using a B-mode, real time ultrasound scanner (Mircus SSD 500, Aloka, Japan) fitted with a 5.0 MHz convex array transducer, as described earlier (Ahmad *et al.*, 1991). Prints of ultrasonographic images were taken, using a video graphic printer (Echo Copier SSZ-307 E, Aloka, Japan).

### Statistical analysis

The mean values ( $\pm$  SE) of the testicular diameter (surface to surface and border to border) and the diameter of mediastinum testis for slaughtered animals were calculated. In order to see the relationship between the ultrasound and caliper values, the correlation coefficients between these values were computed. Similarly, the mean values ( $\pm$  SE) of the scrotal circumference and physical characteristics of semen quality for fertile breeding bulls were computed.

## RESULTS AND DISCUSSION

### Slaughtered animals

In slaughtered buffalo males, the diameter of the testis from surface to surface and from border to border ranged from 2.2 to 4.6 and 3.1 to 5.5 cm, irrespective of the side of the testis or the method of measurement (Table 1). The testis size is known to be significantly affected by age of the animal, being smaller in young than the adult or old animals (Younis *et al.*, 2003). Since the organs used in the present study were taken from slaughtered animals, the age of these animals could not be ascertained.

The diameter of the mediastinum testis, irrespective of the side or measuring technique, varied from 2.2 to 4.3 mm (Table 1). These findings are supported by those of Cartee *et al.* (1989), who observed that diameter of mediastinum testis of cattle bulls ranged from 2.0 to 4.0 mm. However, the diameter of mediastinum of canine testis was 2.0 mm (Pugh *et al.*, 1990), which reflects species differences.

There were significant positive correlations between ultrasonic and calipers measurements for the testicular diameter ( $r = 0.992$ ;  $P < 0.01$ ) and diameter of the mediastinum testis ( $r = 0.979$ ;  $P < 0.01$ ). Similarly, Bailey *et al.* (1998) described the measurements of testicular length and width by using calipers and ultrasonographic imaging. Both techniques were found to be quite reliable

**Table 1:** Mean values ( $\pm$  SE) for testis diameter (surface to surface and border to border) and mediastinum testis diameter in male buffaloes

Testis	Surface to surface diameter (cm)		Border to border diameter (cm)		Mediastinum testis diameter (mm)	
	Ultrasound	Calipers	Ultrasound	Calipers	Ultrasound	Calipers
Right	3.36 $\pm$ 0.21 (2.4 - 4.3)	3.56 $\pm$ 0.22 (2.6 - 4.6)	4.29 $\pm$ 0.25 (3.1 - 5.3)	4.47 $\pm$ 0.25 (3.3 - 5.5)	3.33 $\pm$ 0.21 (2.2 - 4.2)	3.47 $\pm$ 0.21 (2.4 - 4.3)
Left	3.33 $\pm$ 0.22 (2.2 - 4.3)	3.53 $\pm$ 0.24 (2.3 - 4.5)	4.27 $\pm$ 0.24 (3.1 - 5.1)	4.48 $\pm$ 0.24 (3.3 - 5.2)	3.23 $\pm$ 0.17 (2.3 - 4.0)	3.40 $\pm$ 0.17 (2.5 - 4.1)

Values in parentheses are ranges.

for testis measurements. However, in their study, calipers appeared to be easier to use and demonstrated a higher degree of accuracy for measurement of testicular length.

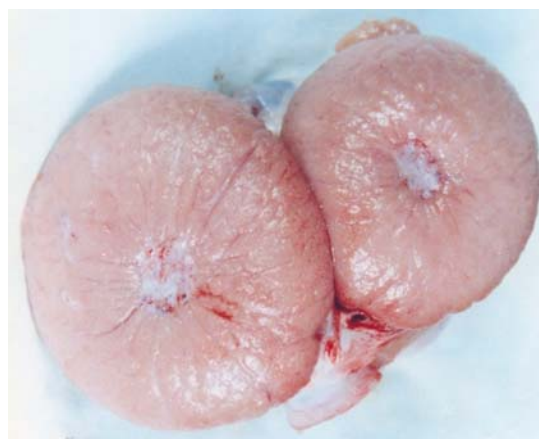In most of the measurements recorded in the present study, the caliper values were higher than the respective values recorded through ultrasound. During ultrasonographic measurements of the testis diameter, the organ was slightly pressed due to pressure exerted on the transducer to ensure its close contact with the organ. This might explain the reason for lower ultrasonographic values than caliper values. Moreover, caliper measurements of the mediastinum testis were made after cutting the organ in transverse plane; the tissue might have dilated after cutting which could have affected the values. Cartee *et al.* (1989) also observed that the caliper measurement of testis was greater than the ultrasonographic measurement when ultrasonography was done through the intact scrotal wall.

These results indicate that diagnostic ultrasound can be used to measure testicular diameter. However, some value (3 mm in the present study) should be added to the ultrasonographic measurement to compensate the decrease caused due to pressure effect of the transducer on the organ. Cartee *et al.* (1989) stated that there was no significant difference in physical and ultrasonographic measurements of exposed testicles, while such difference was observed when the scanning was made through the intact scrotal wall.

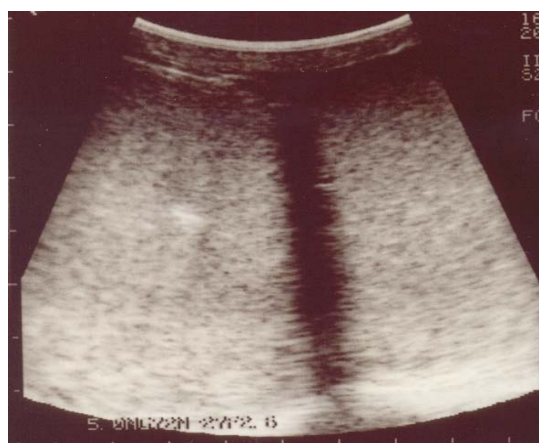#### Fertile bulls

Echotexture of testes and epididymides from slaughtered animals was more or less similar to that recorded for fertile bulls *in vivo*. Ultrasonically, the testis of fertile buffalo and cattle bulls appeared as a homogeneously hypoechoic structure. The mediastinum testis was represented by an almost circular hyperechoic area in the middle of testis in transverse images (Fig. 2), while it was seen as a hyperechoic line in longitudinal images (Fig. 3). These observations are similar to those described for boar (Cartee *et al.*, 1986), dog (England, 1991), bull (Cartee *et al.*, 1989), rams and male goats (Ahmad *et al.*, 1991) and camels (Pasha *et al.*, 2011). Ahmad *et al.* (2011) recorded an increase in the echogenicity of testicular parenchyma with advancement in age of the bull; the mean number of pixels of testicular ultrasonograms increased significantly up to 24 months of age and then leveled off as the age increased.

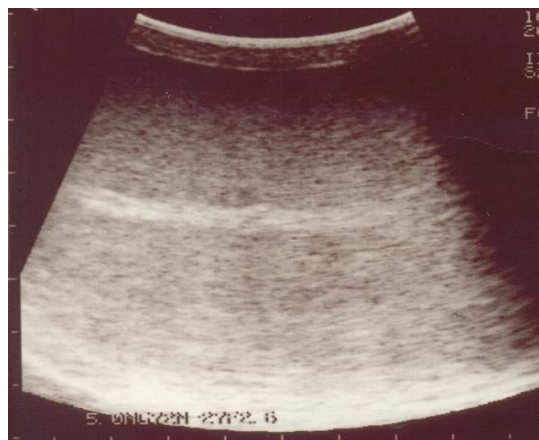In fertile buffalo and cattle bulls, the tail of the epididymis was a more heterogeneous structure than the testis. As a whole, its structure was hypoechoic relative to that of the testis (Fig. 4). These findings are comparable to those of Cartee *et al.* (1986) and Pugh *et al.* (1990) for the boar and dog, respectively. Similar observations have been recorded for bulls (Cartee *et al.*, 1989), male goats and rams (Ahmad *et al.*, 1991). It seems that the testis is relatively more homogenous, whereas the tubules in the epididymis are larger and thus generate more specular echoes (Leung *et al.*, 1984), which might have been responsible for its heterogeneous appearance. The head of the epididymis was less echogenic than the testicular parenchyma and homogeneous in echotexture. Numerous hypoechoic tubular structures represented pampiniform plexus. The epididymal body appeared as hypoechoic structure with echogenic margin.



**Fig. 1:** Cross section of a normal bull testis showing mediastinum testis in the middle.



**Fig. 2:** Transverse ultrasonograph of paired testes showing homogeneously hypoechoic structure, with a hyperechoic circular area in the middle representing mediastinum testis

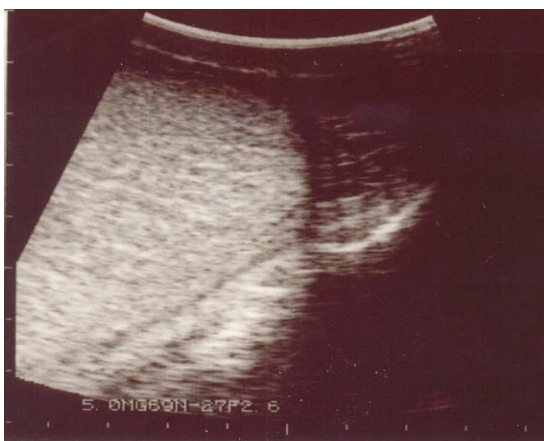

**Fig. 3:** Longitudinal ultrasonograph of normal testis showing a hyperchoic line in the middle representing mediastinum testis

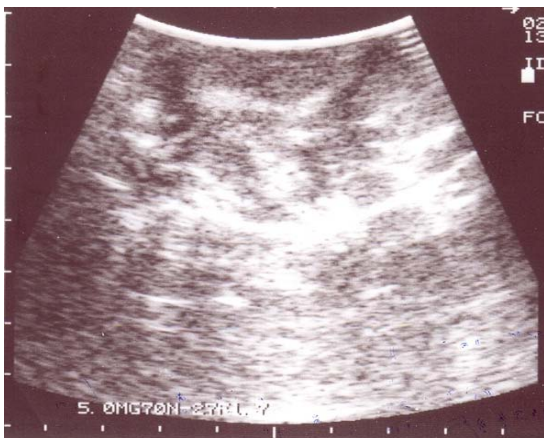
#### Infertile bulls

Among 10 infertile bulls, nine had poor semen quality, while one bull failed to give any ejaculate. On ultrasonography, six bulls showed abnormalities in their scrotal echotexture. The first bull had high percentage of

dead and abnormal spermatozoa in its semen (Table 2). The testes were hard in consistency. Ultrasonography revealed an abundance of hyperechoic areas with acoustic shadowing scattered in the parenchyma of both testes (Fig. 5). These hyperechoic areas were assumed to represent mineralization in the testes. Ahmad *et al.* (1993a) and Ahmad and Noakes (1995a) observed similar hyperechoic areas in the testicular parenchyma of infertile goats. On histopathological examination, these areas were found to represent testicular degeneration with mineralization of seminiferous tubules. According to Lenz and Giwerzman (2008), such bright echogenic spots were representing microlithiasis or microcalcifications. It appears that in this bull, poor semen quality was due to bilateral testicular degeneration with mineralization of seminiferous tubules.



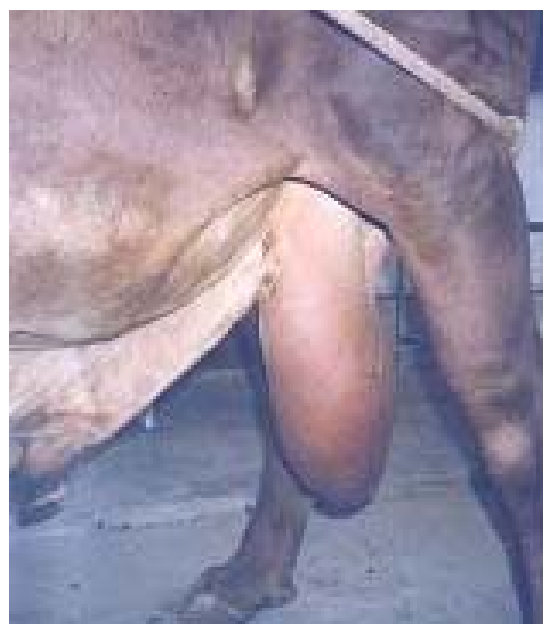**Fig. 4:** Longitudinal ultrasonograph showing normal testis (on the left) and epididymal tail (top right)



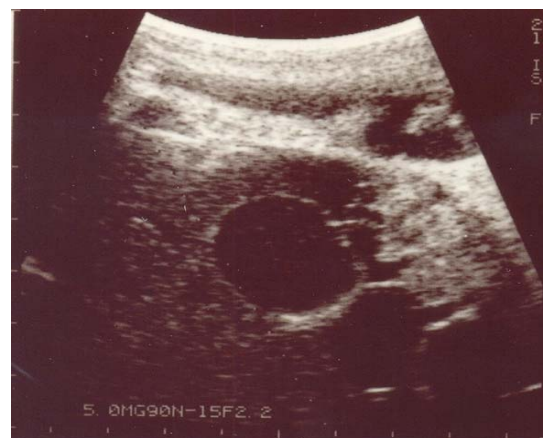
**Fig. 5:** Ultrasonograph of infertile bull No.1, showing many hyperechoic areas scattered throughout the testis

The second bull had both testes of much bigger size with pulpy consistency (Fig. 6). The scrotal circumference was 63 cm and was much bigger than the normal range. There was high percentage of dead spermatozoa (43.4%) in its semen (Table 2). Detached head was most common morphological abnormality of spermatozoa. Ultrasonography showed many anechoic areas within the testis and the epididymal head, demarcated from the rest of the

tissue by well defined hyperechoic margins (Fig. 7). On ultrasonographic measurement, one lesion in the testis was as large as 3.5 cm in diameter. These lesions were assumed to represent cysts (spermatocoele), as has been reported in dogs (England, 1991). Hyperechogenic mass, along with anechoic areas, was also seen below the scrotal skin. Whether this hyperechoic mass represented the fibrin within the fluid is not clear. Ahmad *et al.* (1999) described a case of hydrocoele in a male goat following ligation of testicular artery. The affected testis was encircled by anechoic fluid with hyperechoic fibrin strands within the fluid. In other studies (Ahmad and Noakes, 1995b; Ahmad *et al.*, 2000), anechoic areas, representing sperm granulomata, were seen within the epididymal head and the tail of infertile rams. Thus, the bull under study appears to have hydrocoele and spermatocoele with sperm granulomata of the epididymal head.



**Fig. 6:** Photograph of an infertile bull No. 2 showing enlarged scrotum



**Fig. 7:** Ultrasonograph of infertile bull No. 2, showing anechoic areas in the testis (middle & bottom right) and epididymal head (top right).

**Table 2:** Scrotal circumference and physical characteristics of semen quality in fertile and infertile breeding bulls

Bull No.	Scrotal circumference (cm)	Ejaculate volume (ml)	Sperm conc. (10 <sup>9</sup> /ml)	Sperm motility (%)	Dead sperm (%)	Abnormal sperm (%)
Fertile bulls (Av. Values)	39.5±2.3	5.02±0.4	1.07±0.1	86.36±2.0	11.22±1.9	8.42±1.1
Infertile bulls						
No. 1	40.5	6.4	0.67	59.30	31.70	19.60
No. 2	63.0	4.3	0.61	48.20	43.40	17.40
No. 3	44.5	6.7	0.54	64.40	33.90	10.30
No. 4	37.0	5.8	0.33	70.10	27.30	14.10
No. 5	33.0	2.3	0.41	48.70	41.50	23.70
No. 6	34.0	-	-	-	-	-
No. 7	33.5	2.8	0.83	59.0	9.40	38.70
No. 8	33.0	3.0	1.10	47.6	30.80	21.50
No. 9	28.0	1.8	0.34	53.5	44.40	16.30
No. 10	34.0	4.7	0.31	7.50	74.00	82.00

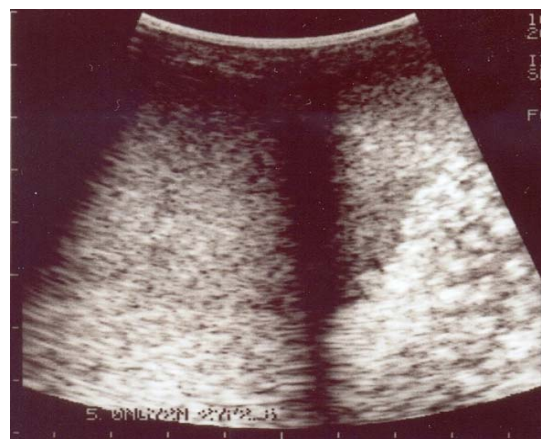The third bull had the history of progressive reduction in percentage of actively motile spermatozoa. On palpation, the right testis showed atrophy and was hard in consistency. There was high percentage of dead spermatozoa (33.9%) in the ejaculate. Ultrasound examination of the right testis revealed the presence of large number of hyperechoic areas scattered in the three-fourth of the testicular parenchyma, while one-fourth of the right testis and the whole of the left testis were normal (Fig. 8). The affected portion of the testis appeared to represent testicular degeneration with mineralization, as these findings coincided with the observations described in goats with testicular degeneration (Ahmad *et al.*, 1993a; Ahmad and Noakes, 1995a).

The ultrasound findings of this bull indicate that through this technique the extent of damage to an organ can be determined, as in this case about three-fourth of testis was affected, while one fourth appeared normal. This would not have been possible with the conventional method of palpating the organ.

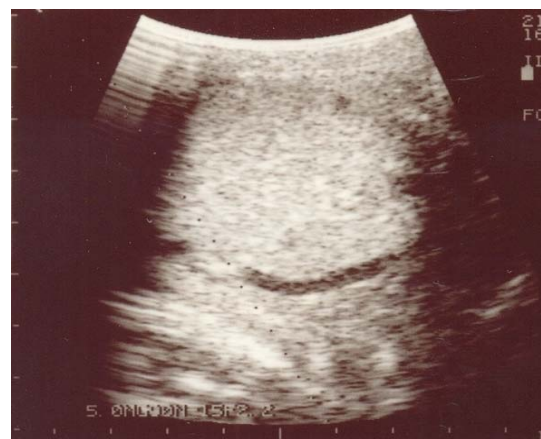The fourth bull was positive for brucellosis. On gross examination, the right epididymal tail was bigger than the left. Semen was of poor quality with the dead percentage of spermatozoa as 27.3 (Table 2). Ultrasonically, two anechoic areas were seen in one testis; one was circular in outline, while the other was curvilinear (Fig. 9). These were assumed to represent dilated blood vessels. However, the exact nature of these lesions remains unclear. The tail of the right epididymis was enlarged and showed a few hyperechoic areas with acoustic shadowing, presumably representing chronic epididymitis. Similar observations have been described in a ram (Ahmad *et al.*, 1991), in which tail of epididymis revealed a few hyperechoic areas. On histopathological examination, it was found to be affected with chronic epididymitis.

In the fifth bull, semen quality was poor (Table 2), having high percentage of dead (41.5%) and morphologically abnormal (23.7%) spermatozoa in its ejaculate. The ultrasound examination revealed small hyperechoic areas within the testicular parenchyma. Some of these areas exhibited acoustic shadowing. These were assumed to represent testicular degeneration with mineralization, as these observations are similar to the findings reported in goats with testicular degeneration and mineralization (Ahmad *et al.*, 1993a; Ahmad and Noakes, 1995a).

The sixth bull did not give any ejaculate, although it was physically healthy. On ultrasound examination, the



**Fig. 8:** Ultrasonograph of paired testes of infertile bull No. 3. About three-fourth of the right testis shows hyperechoic areas, while remaining of the right testis and whole of the left testis are normal.



**Fig. 9:** Ultrasonograph of testis of infertile bull No. 4, showing a curvilinear anechoic area in the lower part.

scrotal contents appeared normal except for an anechoic area with distinct hyperechogenic margin below the testicular tunics. Whether this was dilated blood vessel or accumulation of fluid is not clear.

The remaining four infertile bulls had poor quality of semen with high percentage of dead and morphologically abnormal spermatozoa (Table 2). The testes and epididymides of these bulls appeared normal on palpation

and also showed normal echogenicity. Thus, the probable causes of low quality semen in these bulls remain unclear. However, accessory sex glands such as seminal vesicles of these bulls were not examined. It is possible that infertility in these bulls was due to involvement of these glands, as seminal vesiculitis has been reported to be a cause of infertility in a goat (Ahmad *et al.*, 1993b).

In the present study, 10 infertile bulls were examined. Among these, nine bulls had very poor semen quality, while in one bull the semen picture was not available due to lack of libido. Ultrasound examination revealed presence of detectable lesions in six bulls. However, the true nature of these lesions could not be established due to lack of gross and histopathological examination. Therefore, gross and histopathological examination of reproductive organs, together with ultrasound imaging should be included in the future studies.

On the basis of findings of the present study, it can be concluded that diagnostic ultrasonography is a useful approach for detection of scrotal lesions in early, as well as advance stages, when used in combination with other methods such as manual palpation, measurement of scrotal circumference, testicular diameter and evaluation of semen. This technique may be included in breeding soundness examination of breeding bulls.

#### REFERENCES

- Ahmad N and DE Noakes, 1995a. Ultrasound imaging in determining the presence of testicular degeneration in two male goats. *Br Vet J*, 151: 101-110.
- Ahmad N and DE Noakes, 1995b. A clinical and ultrasonographic study of the testes and related structures of goats and rams after unilateral vasectomy. *Vet Rec*, 137: 112-117.
- Ahmad N, DE Noakes and AL Subandrio, 1991. B-mode, real time ultrasonographic imaging of the testis and the epididymis of sheep and goats. *Vet Rec*, 128: 491-496.
- Ahmad N, DE Noakes and DJ Middleton, 1993a. Use of ultrasound to diagnose testicular degeneration in a goat. *Vet Rec*, 132: 436-439.
- Ahmad N, DE Noakes and DJ Middleton, 1993b. Seminal vesiculitis and epididymitis in an Anglo-Nubian buck. *Vet Rec*, 133: 322-323.
- Ahmad N, HA Samad, NU Rehman, KM Ahmad and M Ahmad, 1999. An ultrasonographic and histopathological study of the testis and epididymis following experimentally induced unilateral ischemia in male goats and rams. *Pak Vet J*, 19: 204-209.
- Ahmad N, GCW England and DE Noakes, 2000. Ultrasonography of spontaneous lesions of the genital system of three rams, and their influence on semen quality. *Vet Rec*, 146: 10-15.
- Ahmad E, N Ahmad, Z Naseer, M Aleem, MS Khan, M Ashiq and M Younis, 2011. Relationship of age to body weight, scrotal circumference, testicular ultrasonograms and semen quality in Sahiwal bulls. *Trop Anim Health Prod*, 43: 159-164.
- Anwar M, A Riaz, N Ullah and M Rafiq, 2008. Use of ultrasonography for pregnancy diagnosis in Balkhi sheep. *Pak Vet J*, 28: 144-146.
- Bailey TL, RS Hudson, TA Powe, MG Riddell, DF Wolfe and RL Carson, 1998. Caliper and ultrasonographic measurements of bovine testicle and a mathematical formula for determining testicular volume and weight *in vivo*. *Theriogenology*, 49: 581-594.
- Bird K and AT Rosenfield, 1984. Testicular infarction secondary to acute inflammatory disease: Demonstration by B-scan ultrasound. *Radiology*, 152: 785-788.
- Cartee RE, TA Powe, BW Gray, RS Hudson and DL Kuhlers, 1986. Ultrasonographic evaluation of normal boar testicles. *Amer J Vet Res*, 47: 2543-2548.
- Cartee RE, BW Gray, TA Powe, RS Hudson and J Whitesides, 1989. Preliminary implications of B-mode ultrasonography of the testicles of beef bulls with normal breeding soundness examination. *Theriogenology*, 31: 1149-1157.
- England GCW, 1991. Relationship between ultrasonographic appearance, testicular size, spermatozoal output and testicular lesions in the dog. *J Small Anim Pract*, 32: 306-311.
- Hendry WS, WHH Garvie, AK Ah-See and AP Bayliss, 1984. Ultrasonic detection of occult testicular neoplasms in patients with gynaecomastia. *Br J Radiol*, 57: 571-572.
- Hinkeldey JA and S Hopkins, 1996. Using ultrasonography in bovine reproduction. *Iowa State Univ Veterinarian*, 58: 23-30.
- Karmazyn B, 2010. Scrotal ultrasound. *Ultrasound Clinics*, 5: 61-74.
- Lenz S and A Giwerzman, 2008. Carcinoma-in-situ of the testis: Is ultrasound of testes useful as a screening method? *J Med Ultrasound*, 16: 256-267.
- Leung ML, GRW Gooding and RD Williams, 1984. High resolution sonography of scrotal contents in asymptomatic subjects. *Amer J Roentgenol*, 143: 161-164.
- Pasha RH, AS Qureshi, LA Lodhi and H Jamil, 2011. Biometric and ultrasonographic evaluation of the testis of one-humped camel (*Camelus dromedarius*). *Pak Vet J*, 31: 129-133.
- Pugh CR, LJ Konde and RD Park, 1990. Testicular ultrasound in a normal dog. *Vet Radiol*, 31: 195-199.
- Yin S and JL Trainor, 2009. Diagnosis and management of testicular torsion, torsion of appendix testis and epididymitis. *Clin Ped Emerg Med*, 10: 38-44.
- Younis M, HA Samad, N Ahmad and I Ahmad, 2003. Effect of age and season on the body weight, scrotal circumference and libido in Nili-Ravi buffalo bulls maintained at the Semen Production Unit, Qadirabad. *Pak Vet J*, 23: 59-65.