



Endoscopically removed giant submucosal lipoma

Veliki submukozni lipom endoskopski uklonjen

Ivan Jovanović*, Aleksandra Pavlović*, Dragan Popović*, Maja Pavlov†

Clinical Center of Serbia, *Clinic of Gastroenterology and Hepatology, †First Surgical Clinic, Belgrade

Abstract

Background. Although uncommon, giant submucosal colon lipomas merit attention as they are often presented with dramatic clinical features such as bleeding, acute bowel obstruction, perforation and sometimes may be mistaken for malignancy. There is a great debate in the literature as to how to treat them. **Case report.** A patient, 67-year old, was admitted to the Clinic due to a constipation over the last several months, increasing abdominal pain mainly localized in the left lower quadrant accompanied by nausea, vomiting and abdominal distension. Physical examination was unremarkable and the results of the detailed laboratory tests and carcinoembryonic antigen remained within normal limits. Colonoscopy revealed a large 10 cm long, and 4 to 5 cm in diameter, mobile lesion in his sigmoid colon. Conventional endoscopic ultrasound revealed 5 cm hyperechoic lesion of the colonic wall. Twenty MHz mini-probe examination showed that lesion was limited to the submucosa. Since polyp appeared too large for a single transaction, it was removed piecemeal. Once the largest portion of the polyp has been resected, it was relatively easy to place the opened snare loop around portions of the residual polyp. Endoscopic resection was carried out safely without complications. Histological examination revealed the common typical histological features of lipoma elsewhere. The patient remained stable and eventually discharged home. Four weeks later he suffered no recurrent symptoms. **Conclusion.** Colonic lipomas can be endoscopically removed safely eliminating unnecessary surgery.

Key words:

lipoma; colon, sigmoid; diagnosis; endoscopy; treatment outcome.

Apstrakt

Uvod. Mada retki, veliki submukozni lipomi kolona zaslužuju pažnju. Često se prezentuju dramatičnom kliničkom slikom krvarenja, akutnom opstrukcijom creva, perforacijom, a ponekad mogu biti pogrešno shvaćeni kao maligni. U literaturi postoji velika diskusija o tome kako ih lečiti. **Prikaz bolesnika.** Bolesnik, star 67 godina, primljen je u kliniku zbog konstipacije tokom nekoliko prethodnih meseci, sve jačeg bola lokalizovanog uglavnom u levom donjem kvadrantu trbuha, udruženog sa mučninom, povraćanjem i nadimanjem. Fizikalnim pregledom utvrđen je normalan nalaz, a rezultati detaljnih laboratorijskih testova i karcinoembrion antigena bili su u granicama normalnih vrednosti. Kolonoskopijom je u sigmoidnom kolonu otkrivena velika, mobilna lezija, duga 10 cm, dijametra 4–5 cm. Konvencionalnim endoskopskim ultrazvukom otkrivena je hiperehogena lezija zida kolona, veličine 5 cm. Upotrebom mini sonde od 20 MHz dokazano je da je lezija ograničena na submukozu. Zbog veličine, polip je odstranjen deo po deo. Kada je najveći deo polipa odstranjen, bilo je relativno lako staviti otvorenu omču oko rezidualnog dela polipa. Endoskopska resekcija sprovedena je bezbedno, bez komplikacija. Histološkim ispitivanjem utvrđeno je da se radi o lipomu. Bolesnik je nakon toga bio stabilan i otpušten je kući. Četiri nedelje kasnije nije imao ponovljene simptome. **Zaključak.** Lipomi kolona mogu se bezbedno endoskopski odstraniti, bez primene operacije.

Ključne reči:

lipom; kolon, sigmoidni; dijagnoza; endoskopija; lečenje, ishod.

Introduction

Colon lipomas are benign tumors arising from adipose connective tissue in the bowel wall. They are often described as rare colonic tumors¹⁻⁴, but it is difficult to estimate the true frequency, as most are small and asymptomatic or mildly symptomatic⁵. Colonoscopy studies revealed incidence between 0.11 and 0.15%^{6,7}, while autopsy studies es-

timate the prevalence between 0.2 and 4.4% of people⁸. Although uncommon, large colonic lipomas merit attention as they are often presented with dramatic clinical features such as bleeding or acute bowel obstruction and sometimes may be mistaken for malignancy^{9,10}. We report a case of large, submucous sigmoid colon lipoma and review the literature to evaluate the clinical features, diagnosis and treatment of this disease.

Case report

We report a case of 67-year-old man who presented to his general practitioner (GP) with a history of altered bowel habit. He had been suffering from constipation over the last several months. In addition, several weeks prior to visiting his GP he started feeling increasing abdominal pain. The pain was mainly localized in the left lower quadrant. At the time of presentation to his GP the patient was experiencing episodes of pain every day accompanied by nausea, vomiting and abdominal distention. He had no history of mucus or blood passed *per rectum*, and no weight loss. Physical examination was unremarkable and the results of the detail laboratory tests including complete blood cell counts, blood biochemistry and carcinoembryonic antigen remain within normal limits. He was referred to our institution for further investigation. Colonoscopy revealed a large, yellowish, 10 cm long by 4 to 5 cm in diameter, mobile lesion in his sigmoid colon (Figure 1). The overlying mucosa was smooth, and the lesion was soft, compressible (“cushion” or “pillow” sign) with “tenting” sign of the mucosa when grasped with forceps. Surface biopsies examination revealed normal colonic mucosa. A diagnosis of mobile submucosal colonic lipoma, was considered as the most probable but malignancy could not be excluded.

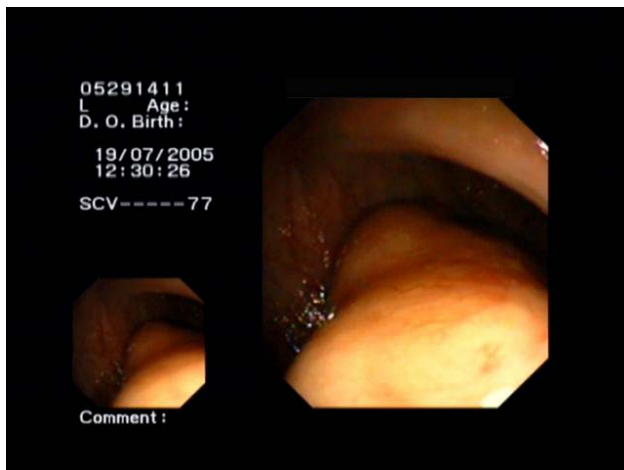


Fig. 1 – Large 10 cm long by 4 to 5 cm in diameter, mobile lesion in sigmoid colon with macroscopically intact overlying mucosa

Conventional 7.5 and 12 MHz endoscopic ultrasound (EUS) revealed 5 cm hyperechoic lesion of the colonic wall (intramural lesion). Twenty MHz mini-probe examination further showed (intramural) infiltration of the colonic wall limited to the submucosa and no extension to underlying *muscularis propria* was noted (Figure 2). The hyperechoic pattern of the lesion at EUS was consistent with a lipoma lying within the submucosa. Initially, the base of the polyp was injected with a solution of 1 : 10 000 epinephrine (8 ml) to elevate the lesions. Since polyp appeared too large for a single transaction, it was removed piecemeal with standard rotatable oval type electrosurgical snare. Although largest portion of the polyp was snared and continuous current was ap-

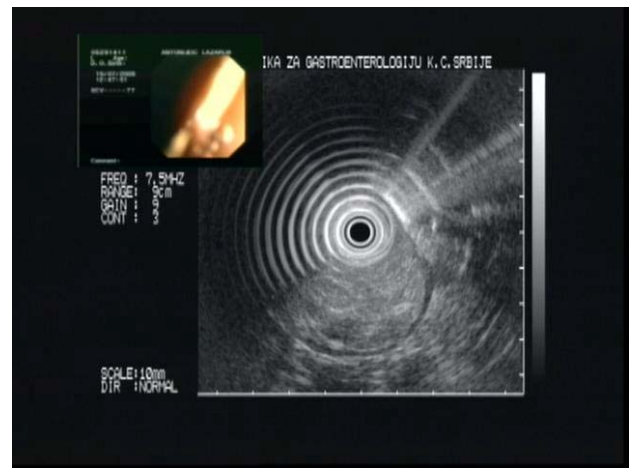


Fig. 2 – Hyperechoic intramural lesion of the colonic wall. Infiltration is limited to the submucosa and *muscularis propria* is intact (Conventional 7.5 and 12 MHz endoscopic ultrasound and 20 MHz mini-probe examination)

plied along with wire retraction, because snare handle was at the end of its travel and polyp had not been transected, cutting current had to be used to sever the remainder of the lesion. Once the largest portion of the polyp has been resected, it was relatively easy to place the opened snare loop around portions of the residual polyp. Endoscopic resection was carried out safely without complications. Gross finding of polypoid formation depicted lipomatous expansion of the submucosal layer. Histological examination revealed the common typical histological features of lipoma elsewhere. Submucosal overgrowth of lobulated mature fat tissue protuberated and was covered with the raised histologically regular colonic mucosa (Figure 3).

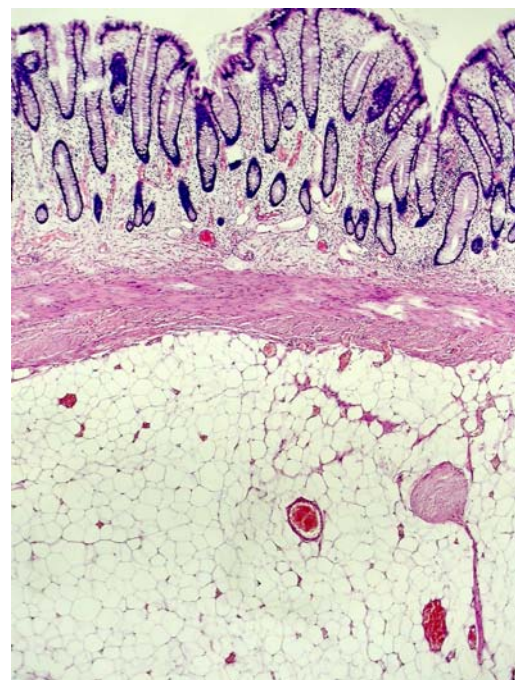


Fig. 3 – Histological sections revealed dome shaped colonic mucosa over submucosal lipomatous proliferation. (H&E, 13 ×)

The patient remained stable and eventually discharged home. An office visit four weeks later failed to reveal any recurrent symptoms. He was pain-free with normal bowel motions.

Discussion

Lipomas are the most common nonepithelial tumors of the gastrointestinal tract⁴. In the colon, however, lipomas are uncommon. They occur in older patients (average age, 60 years)^{4, 5, 10}. Seventy percent are localized in the right hemi-colon. These tumors are well differentiated and most frequently arise from adipose tissue in the bowel wall. They are usually (90%) submucosal in origin. The rest are either subserosal (more common) or intramuscular mural^{4, 5, 9, 10}. Colonic lipomas rarely cause symptoms¹¹ and among the most common problems when they occur are bleeding¹², obstruction¹³, perforation and intussusception^{14, 15}.

Diagnosis can be difficult. Pre-treatment diagnosis is important as these lesions present in a similar age group and with similar symptoms as do colonic malignancies. Lipomas can be directly visualized during colonoscopy and biopsy taken. Normal mucosa on biopsy is relatively re-assuring for the lack of malignancy.

Symptomatic lipomas need resection, and there is currently no consensus on treatment of these lesions. Several studies report successful endoscopic resection of submucosal colonic lesions including lipomas¹⁶⁻¹⁸. Removal of lesions greater than 2 cm has been associated with higher risk of perforation^{16, 19, 20} and Pfeil et al.¹⁷ in their series reported the rate of perforation as high as 43% in lipomas resected endoscopically. Interestingly, in all

three cases complicated by perforation, smooth muscle from the *muscularis propria* was identified in the specimen, and one specimen contained serosa¹⁷. As it was described recently, endoscopic ultrasound can be used to evaluate the depth of colonic lipoma margins and to distinct the origin of the lipoma in the bowel wall further ensuring safe endoscopic removal^{16, 21-23}. In our case, lesion displayed echosonographic features typical of a lipoma and revealed no extension into the underlying muscle. The base was then injected with a solution of 1 : 10 000 epinephrine (8 ml) to elevate the lesions and endoscopic removal was carried out safely.

Colonic lipomas are rare in clinical practice and they occasionally require resection due the symptoms they cause. The literature supports the concept of endoscopic resection for the lesions less than 2 cm in diameter if they are symptomatic. But, since these lesions are rarely symptomatic, the most would suggest observation and follow-up^{4, 6, 7, 16-20}.

Conclusion

Currently, the indication for endoscopic resection of symptomatic, larger than 2 cm colonic lipoma is still a controversial subject. In our opinion, endoscopic therapy is enhanced in the presence of endoscopic ultrasound and the risk of perforation can be reduced further for those 10% lipomas which arise from the muscle, which would be more safely resected at open surgery. Lipomas are benign tumors; and if a lesion is found, minimally invasive endoscopic procedures should be selected as colonic lipomas can be removed safely following the guidance of the presented therapeutic strategy eliminating unnecessary surgery.

R E F E R E N C E S

- Bala D, Czechowicz W, Sir J. The case of a giant lipoma polyp in transverse colon. *Acta Endoscopica Polona* 2000; 10: 89-91.
- Kurosaki T, Fujikawa T, Katayama R, Ikeuchi K, Takao Y, Ootsuka M, et al. A case of giant lipoma of the colon. *J Japan Soc Colo-Proct* 1996; 49: 373-7.
- Notaro JR, Masser PA. Annular colon lipoma: a case report and review of the literature. *Surgery* 1991; 110(3): 570-2.
- Rogy MA, Mirza D, Berlakovich G, Winkelbauer F, Raubs R. Submucous large-bowel lipomas – presentation and management. An 18-year study. *Eur J Surg* 1991; 157(1): 51-5.
- Bombi JA. Polyps of the colon in Barcelona, Spain. An autopsy study. *Cancer* 1988; 61(7): 1472-6.
- Chung YF, Ho YH, Nyam DC, Leong AF, Seow-Choen F. Management of colonic lipomas. *Aust N Z J Surg* 1998; 68(2): 133-5.
- Invaldi L, Carozza V, Perino M, Gambetta A, Mura G, Bianco A, et al. Large bowel lipomas. *Chirurgia* 2001; 14: 155-6.
- Vecchio R, Ferrara M, Mosca F, Ignoto A, Latieri F. Lipomas of the large bowel. *Eur J Surg* 1996; 162(11): 915-9.
- Franco-Law JM, Begin LR, Vasilevsky CA, Gordon PH. The dramatic presentation of colonic lipomata: report of two cases and review of the literature. *Am Surg* 2001; 67(5): 491-4.
- Bardaji M, Roset F, Camps R, Sant F, Fernandez-Layos MJ. Symptomatic colonic lipoma: differential diagnosis of large bowel tumors. *Int J Colorectal Dis* 1998; 13(1): 1-2.
- Zhang H, Cong JC, Chen CS, Qiao L, Liu EQ. Submucous colon lipoma: a case report and review of the literature. *World J Gastroenterol* 2005; 11(20): 3167-9.
- de Ruijter SH, van Marle AG, Doornwaard H, Melse JC. Submucosal lipoma of the colon: abdominal cramps with rectal bleeding and weight loss. *Ned Tijdschr Geneesk* 2006; 150(36): 1990-3. (Dutch)
- Ghidirim G, Mishin I, Gutsu E, Gagauz I, Danch A, Russu S. Giant submucosal lipoma of the cecum: report of a case and review of literature. *Rom J Gastroenterol* 2005; 14(4): 393-6.
- Kabaalioglu A, Gelen T, Aktan S, Kesici A, Bircan O, Luleci E. Acute colonic obstruction caused by intussusception and extrusion of a sigmoid lipoma through the anus after barium enema. *Abdom Imaging* 1997; 22(4): 389-91.
- Rodriguez DI, Drehner DM, Beck DE, McCauley CE. Colonic lipoma as a source of massive hemorrhage. Report of a case. *Dis Colon Rectum* 1990; 33(11): 977-9.
- Kim CY, Bandres D, Tio TL, Benjamin SB, Al-Kawas FH. Endoscopic removal of large colonic lipomas. *Gastrointest Endosc* 2002; 55(7): 929-31.
- Pfeil SA, Weaver MG, Abdul-Karim FW, Yang P. Colonic lipomas: outcome of endoscopic removal. *Gastrointest Endosc* 1990; 36(5): 435-8.
- Jovanović I, Cvejić T, Popović D, Micev M. Endoscopic removal of pedunculated leiomyoma of the sigmoid colon (case report

- and literature review of diagnostic and treatment options). *Acta Chir Jugosl* 2006; 53(1): 87–9.
19. *Tamura S, Yokoyama Y, Morita T, Tadokoro T, Higashidani Y, Onishi S.* "Giant" colon lipoma: what kind of findings are necessary for the indication of endoscopic resection? *Am J Gastroenterol* 2001; 96(6): 1944–6.
 20. *Chase MP, Yarze JC.* "Giant" colon lipoma – to attempt endoscopic resection or not? *Am J Gastroenterol* 2000; 95(8): 2143–4.
 21. *Watanabe F, Honda S, Kubota H, Higuchi R, Sugimoto K, Iwasaki H, et al.* Preoperative diagnosis of ileal lipoma by endoscopic ultrasonography probe. *J Clin Gastroenterol* 2000; 31(3): 245–7.
 22. *Zhou PH, Yao LQ, Zhong YS, He GJ, Xu MD, Qin XY.* Role of endoscopic miniprobe ultrasonography in diagnosis of submucosal tumor of large intestine. *World J Gastroenterol* 2004; 10(16): 2444–6.
 23. *Yu HG, Ding YM, Tan S, Luo HS, Yu JP.* A safe and efficient strategy for endoscopic resection of large, gastrointestinal lipoma. *Surg Endosc* 2007; 21(2): 265–9.

The paper was received on April 1, 2007.