

ASSOCIATION OF THE BONE LOSS WITH MAIN CLINICAL AND MICROBIOLOGICAL PARAMETERS IN CHRONIC PERIODONTITIS

Velitchka Dosseva-Panova¹, Christina Popova¹, Angelina Kisselova-Yaneva², Vladimir E. Panov³

1) Department of Periodontology, Faculty of Dental Medicine, Medical University, Sofia, Bulgaria

2) Department of Imaging and Oral Diagnostics, Faculty of Dental Medicine, Medical University, Sofia, Bulgaria

3) Department of Conservative Dentistry and Oral Pathology, Faculty of Dental Medicine, Medical University, Varna, Bulgaria

SUMMARY:

Literature data have reported that certain Gram-negative anaerobe bacteria from the subgingival environment are important etiological agents of chronic periodontal disease. Based on published criteria identifying periodontal pathogens, major evidences has been shown for: *Aggregatibacter actinomycetemcomitans*, *Porphyromonas gingivalis* and *Tannerella forsythia*; moderate evidences for: *Prevotella intermedia*, *Peptostreptococcus /Micromonas/ micros*, *Fusobacterium nucleatum*, *Eubacterium nodatum*, *Campylobacter rectus*, and *spirochetes (Treponema denticola)*. Microbiological data has been suggested by several studies as a useful indicator of disease progression, selection of an adjunctive antimicrobial administration, healing assessment and disease recurrence.

The results of this study demonstrate statistically significant correlation between periodontal attachment loss and the prevalence of *Porphyromonas gingivalis*, *Tannerella forsythia* and *Peptostreptococcus (Micromonas) micros* in deep periodontal pockets of severe chronic periodontitis patients.

Key words: periodontal pathogens, chronic periodontitis, subgingival biofilm, bone loss,

INTRODUCTION:

Periodontal disease has polymicrobial nature in strong relation with the host homeostasis. Destructive process that is initiated from dental biofilm periodontopathogens affects connective tissue of the gingiva, alveolar bone and periodontal ligament and advancing may result in tooth loss. Diagnosis of periodontitis includes clinical investigation (probing) and exact radiographic estimation of the bone loss as an important part of any periodontal diagnosis. For this reason dental practitioners and researchers use usually bite-wing radiographs or orthopantomographs. There are some circumstances that concern exact bone loss assessment – variation in projection geometry and in the film contrast and density, and certain anatomic structures. [1] Many

researchers studied the reliability of radiographs in bone level detection at tooth surfaces and found that the true bone loss can't be detected of level less than 1,0mm. [2] In recent years computerized programs, digital subtract radiography and other advanced image-processing techniques can make evaluation more reliable. [1 - 3]

Furthermore the microbiology of periodontal diseases has been object for many investigations in last few decades based on their bacterial etiology. [4 - 9] As a result we know that the establishment in the periodontal pockets of microorganisms such as *Porphyromonas gingivalis* and *Tannerella forsythia* is strongly associated with the progression of periodontitis, and the severity of the disease. [6, 7, 9 - 12] There are also publications with suggestions for other periodontopathogenic bacteria in periodontal environment to be associated with severity of clinical attachment loss and bone loss [8, 13, 14].

OBJECTIVE:

The aim of this study is to evaluate relations between bone loss and important clinical measurements and microbiological data in patient with chronic periodontitis.

MATERIALS AND METHODS:

In the presented study 20 individuals with diagnosis severe chronic periodontitis, generally healthy, without systemic antibiotic (last 6 months) or other administration of drugs were included. Clinical parameters were recorded at 6 sites/tooth and included: bleeding on probing (BoP), pocket depth (PD), clinical attachment loss (CAL) and hygiene index (HI %). Subgingival samples were collected from deepest periodontal sites (>6mm) in each patient for the purpose of bacteria identification. The levels of nine microbial strains were evaluated using Real-Time polymerase chain reaction (PET Plus test, MIP Pharma GmbH) - *Aggregatibacter actinomycetemcomitans*, *Porphyromonas gingivalis*, *Treponema denticola*, *Tannerella forsythia*, *Prevotella intermedia*, *Peptostreptococcus / Micromonas/ micros*, *Fusobacterium nucleatum*, *Eubacterium nodatum*, *Campylobacter rectus*.

RESULTS:

In the present study we found significant relationship between the bone loss and basic clinical parameters of periodontitis. There was obtained data for an important correlation of bone destruction in severe chronic periodontitis with HI, PD and CAL, as well as with some of the detected pathogenic bacteria (Fig. 1, 2 and 3, Table 1.). Respectively to present data bone loss has a significant correlation coefficient with the Total bacterial number and the prevalence of three of evaluated microbial strains: *Porphyromonas gingivalis*, *Tannerella forsythia* and *Peptostreptococcus micros*.

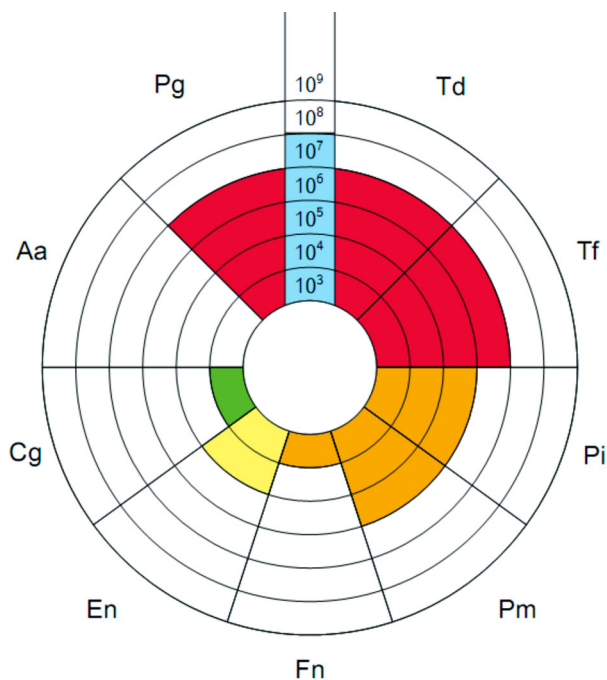


Fig. 1. Detected microbial species (Example 1).

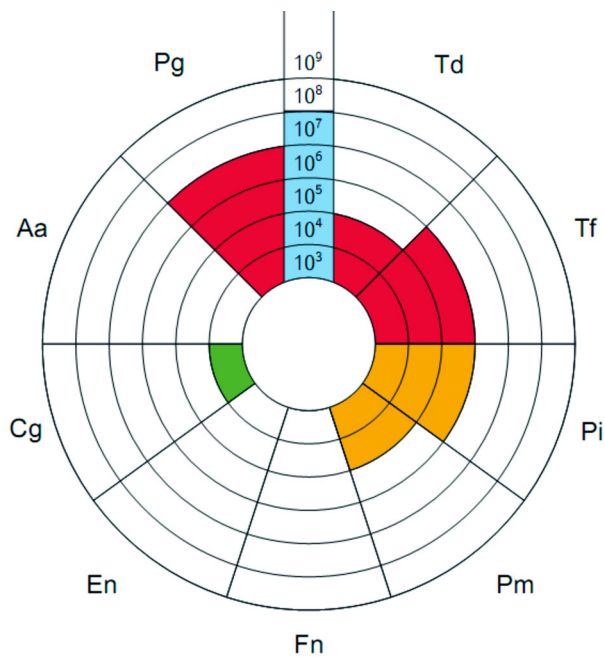


Fig. 2. Detected microbial species (Example 2).

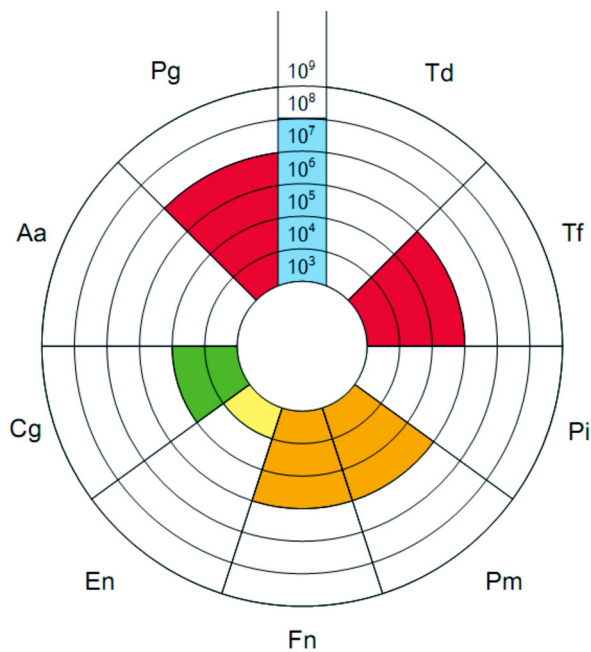


Fig. 3. Detected microbial species (Example 3).

Table 1. Interaction of “Bone Loss, mm” with clinical and microbiological parameters.

	Index	Correlation coefficient (R), at P<0,05
Bone Loss, mm	Total bacterial number	-0,489
	% prevalence of <i>Porphyromonas gingivalis</i>	0,487
	% prevalence of <i>Tannerella forsythia</i>	0,546
	% prevalence of <i>Peptostreptococcus (Micromonas) micros</i>	0,519
	HI %	-0,648
	PD mm mean	0,523
	PD 4-6mm	-0,545
	CAL	0,570

DISCUSSION:

Assessment of bone loss takes an important place in the clinical diagnosis of periodontitis. Frequently bone lost is measured as a distance from CEJ to the alveolar crest and calculate in millimeters or as a percentage of the root length. Most studies have accepted a value of 2mm distance between crestal bone and CEJ as a normal [4]. In our study for estimation of bone level were used orthopantomographs. Orthopantomographs are useful for registration and have a great advantage to give a full mouth view of the dentition with a lower ionization compared with the series of intraoral x-rays. Authors found orthopantomographs suitable for assessment of significant bone destruction in cases of severe periodontitis [2]. Because of that in our study this imaging methods was selected.

Our results are in accordance with most of authors and contemporary conception of periodontal disease's etiology and pathogenesis. In context of published of Sokransky et al. groups of microorganisms that they found together in plaque samples in patients with periodontitis and

form complexes (with different colors – red, orange, green, yellow, purple) in the present study three pathogenic bacteria - *Porphyromonas gingivalis*, *Tannerella forsythia* and *Peptostreptococcus micros* were established in major prevalence in subgingival samples in deep periodontal pockets in chronic periodontitis patients. These microorganisms belong to the red and orange complexes of Sokransky [11, 14, 15]. The results of this study demonstrate statistically significant correlation between periodontal attachment loss and pathogenic microbial finding.

CONCLUSION:

The results of this study allow offering an evidence for the correlation of bone loss in chronic periodontitis with major clinical parameters such as hygiene index, clinical attachment loss, pocket depth, and the presence of *Porphyromonas gingivalis*, *Tannerella forsythia* and *Peptostreptococcus micros* in the subgingival biofilm.

ACKNOWLEDGEMENTS:

The study was conducted with the financial support of the Medical University - Sofia, scientific researches (Grant project No. 8, Contract No. 13 for 2013.)

REFERENCES:

1. Armitage GC. Periodontal diseases: diagnosis. *Ann Periodontol.* 1996 Nov;1(1):37-215. [[PubMed](#)]
2. De Bruyn H, Vandeweghe S, Ruyffelaert C, Cosyn J, Sennerby L. Radiographic evaluation of modern oral implants with emphasis on crestal bone level and relevance to peri-implant health. *Periodontol 2000.* 2013 Jun;62(1):256-270. [[PubMed](#)] [[CrossRef](#)]
3. Tetradis S, Carranza F, Fazio R, Takei H. Radiographic aids in the diagnosis of periodontal disease. In: Carranza's clinical periodontology, Tenth Edition, 2006, Elsevier Inc, p561-578.
4. Hausman E, Allen K, Clerehugh V. What alveolar crest level on a bite-wing radiograph represents bone loss? *J Periodontol.* 1991 Sep; 62(9):570-572. [[PubMed](#)] [[CrossRef](#)]
5. Loomer PM. Microbiological diagnostic testing in the treatment of periodontal diseases. *Periodontol 2000.* 2004; 34:49-56. [[PubMed](#)] [[CrossRef](#)]
6. Page RC. The role of inflammatory mediators in the pathogenesis of periodontal diseases. *J Periodont Res.* 1991 May;26(3 Pt 2):230-242. [[PubMed](#)]
7. Popova Chr, Dosseva-Panova V, Panov VE. Clinical and microbiological data in patients with chronic periodontitis. *J of IMAB.* 2013; 19(4): 313-316. [[CrossRef](#)].
8. Salari MH, Kadkhoda Z. Rate of cultivable subgingival periodontopathogenic bacteria in chronic periodontitis. *J Oral Sci.* 2004 Sep; 46(3):157-161. [[PubMed](#)] [[CrossRef](#)]
9. Yang HW, Huang YF, Chou MY. Occurrence of *Porphyromonas gingivalis* and *Tannerella forsythia* in periodontally diseased and healthy sub-

jects. *J Periodontol*. 2004 Aug; 75(8): 1077-1083. [PubMed] [CrossRef]

10. Haffajee A, Sokransky S. Microbial etiological agents of destructive periodontal diseases. *Periodontol 2000*. 1994 Jun;5:78-111. [PubMed] [CrossRef]

11. Holt SC, Emersole JL. Porphyromonas gingivalis, Treponema denticola and Tannerella forsythia: a "red complex" a prototipe poly-bacterial pathogenic consorcium in periodontitis. *Periodontol 2000*. 2005;

38:72-122. [PubMed] [CrossRef]

12. Teles R, Sakellari D, Teles F, Konstantinidis A, Kent R, Socransky S, et all. Relationships among gingival crevicular fluid biomarkers, clinical parameters of periodontal disease, and the subgingival microbiota. *J Periodontol*. 2010 Jan;81(1):89-98. [PubMed] [CrossRef]

13. Sanz M, Newman M, Quirynen M. Advansed diagnostic techniques. In: Carranza's clinical periodontology,

Tenth Edition, 2006, Elsevier Inc, p579-601.

14. Socransky SS, Haffajee AD, Cugini MA, Smith C, Kent RJ Jr. Microbial complexes in subgingival plaque. *J Clin Periodontol*. 1998 Feb; 25(2):134-144. [PubMed] [CrossRef]

15. Popova Chr, Dosseva-Panova V, Panov V. Microbiology of periodontal diseases. A review. *Biotechnol & Biotechnol Eq*. 2013 27;3:3754-3759. [CrossRef]

Please cite this article as: Dosseva-Panova V, Popova Chr, Kisselova-Yaneva A, Panov VE. Association of the Bone Loss with main clinical and microbiological parameters in chronic periodontitis. *J of IMAB*. 2014 Jul-Sep;20(3):542-545. doi: <http://dx.doi.org/10.5272/jimab.2014203.542>.

Received: 30/04/2014; Published online: 29/07/2014;



Address for correspondence:

Professor Christina Popova, PhD, DM;
Department of Periodontology, Faculty of Dental Medicine,
1, Georgi Sofiiski str, 1431 Sofia, Bulgaria
E-mail: hropopova@yahoo.com;