



# Intestinal alkaline phosphatase activity as a molecular marker of enterotoxicity induced by single dose of 5-fluorouracil and protective role of orally administered glutamine

Katica Bajin-Katić, Karmen Stankov, Matilda Đolai, Zoran Kovačević

## ABSTRACT

**Background:** One of the critical limitations for the administration of the chemotherapy is the toxicity affecting normal tissue. The main target organs for 5-fluorouracil (5-FU) toxicity in humans and experimental animals are the gastrointestinal tract, bone marrow, and skin. The cytotoxic effects of antimetabolite chemotherapy are based on their role as substrates for the same transport processes and enzymes involved in anabolism and catabolism as the natural substrates. The main goal of our study was to analyze the dose-dependent antiproliferative effects of 5-FU on intestinal mucosa, enterotoxic potential of 5-FU in experimental animals and to test possible protective role of glutamine.

**Methods:** In our study, we used Sprague Dawley rats. The control group of rats included 50 animals, while the groups where either 5-fluorouracil (5-FU) alone or 5-FU and glutamine were administered included 200 animals. All experimental animals were further stratified according to the experimental model (25 animals in each of 8 experimental subgroups of animals). The 5-FU was administered by intraperitoneal application in single dose of 0, 100, 200, 300, and 400 mg of 5-FU per kg of body weight. Water solution of 1% glutamine was prepared daily and administered orally, in volume of 200 ml, for 7 days continuously, after the 7th day of 5-FU administration. Experimental animals were sacrificed 7 days after the administration of 5-FU. The isolation of enterocytes was performed according to the method of Kralovansky et al. In cell homogenate obtained by described method, we determined the protein content using the Biuret method and the DNA content using the Burton reagent. The activities of enzymes alkaline phosphatase (ALP), glutathione S-transferase (GST), glutathione reductase (GR), and glutathione peroxidase (GPX) were determined by kinetic method. All paraffin samples of the small intestine were stained by haematoxiline and eosine (HE method). All the experiments were done in duplicate and analyzed by standard statistical methods.

**Results:** Our results of enterotoxicity induced by intraperitoneally administered 5-FU showed statistically significant decrease of DNA content in small intestine samples of experimental animals, decrease in activity of intestinal alkaline phosphatase enzyme and the increase in glutathione-dependent enzymes. The glutamine supplementation reduced 5-FU intestinal toxicity.

**Conclusion:** Intestinal alkaline phosphatase is a good marker of the dose-dependent enterotoxicity induced by 5-fluorouracil.

Medical Faculty Novi Sad, Novi Sad, Serbia; Address correspondence to: Doc. dr sc. Katica Bajin-Katić, Department of Biochemistry, Medical Faculty Novi Sad, Hajduk Veljkova 3, 21000 Novi Sad, Serbia; The manuscript was received: 23.03.2006, Provisionally accepted: 28.06.2006, Accepted for publication: 22.08.2006

© 2007, Institute of Oncology Sremska Kamenica, Serbia

**KEYWORDS:** Fluorouracil; Glutamine; Alkaline Phosphatase; Drug Toxicity; Intestinal Mucosa; Enzymes; Biological Markers; Animal Experimentation

## INTRODUCTION

Alkaline phosphatase (ALP) is a marker enzyme of microvillus membranes (MVM) in intestine and exists both in the soluble and membrane bound forms. The two isoforms of the enzyme are encoded by 2.7 and 3.0 kb mRNA transcripts. The isoenzymes undergo considerable modification during postnatal development (1, 2). The high activity of intestinal ALP, which is localized at the brush border of intestinal epithelial cells, suggests the participation of this enzyme in the transport of nutrients such as inorganic phosphate across the membrane. Intestinal ALP appears to have an important

role in active metabolism by hydrolyzing phospho-compounds to supply free inorganic phosphate (3).

In the last two decades, several comprehensive investigations of cytotoxic agents have shown that intraperitoneally administered 5-fluorouracil (5-FU) induces apoptosis or cell cycle arrest in intestinal epithelial cells of experimental animals and tends to target basal cells within the crypt (4-7). The intestinal injury incurred in ischemia/reperfusion studies has conventionally been assessed with histological grading scales. One of the critical limitations of these techniques is the inability to differentiate irreversible injury from repa-

able injury. Both experimental and clinical studies of these phenomena would be greatly advanced by the identification of a biochemical marker specific for microvillus injury. Such a marker could then be used to delineate factors affecting intestinal injury as well as the efficacy of therapeutic interventions (5). Our interest in alkaline phosphatase as a potential marker of cytotoxic injury is derived from previous experimental observations by our laboratory and from the results of Sisley et al. (5,8).

Few studies have demonstrated that in the rat intestinal brush border membranes, alkaline phosphatase activity was highly susceptible to inactivation by free radical injury in an *in vitro* model of lipid peroxidation, whereas other brush border membrane integral enzymes including disaccharidases and peptidases were resistant to free radical damage (3,9). Our current experiments were designed to evaluate the specificity of the intestinal brush border membrane alkaline phosphatase as a potential novel marker for dose-dependent intestinal injury and possible mucosal protection by glutamine.

Glutamine, traditionally considered a nonessential amino acid, now appears to be a conditionally essential nutrient during serious injury or illness. In good health, this is the most abundant amino acid in plasma and skeletal muscle, but circulating and tissue concentrations fall precipitously after injury, surgery or infection. Glutamine is preferred fuel for the small intestine and clinical studies have revealed that both the parenteral and enteral glutamine supplementation is beneficial in patients after multiple trauma, and surgery. Studies have shown that utilization of glutamine by the gut increases after surgery and other stress conditions and appears to play a vital role in gut maintenance during critical illness. These clinical studies are supported by experimental data showing that glutamine administration maintains gut barrier function (10).

Glutamine can offer protection to the cells by different mechanisms. Glutamine is utilized as a major energy source by the intestinal mucosa and it drives mitochondrial ATP formation by oxidative phosphorylation. Uptake of glutamine by the enterocytes occurs from the gut lumen across the brush border and from the blood stream via capillaries that are adjacent to the basement membrane. The avid uptake of glutamine by the mucosal cells is due in part to the high activity of glutaminase, the first enzyme in the series of reactions that completely oxidizes the carbon chain of glutamine to generate energy. Glutamine may also serve as a metabolic precursor for glutathione, the important cellular antioxidant (10). Our previous study (8) showed that the glutaminase is not as sensitive marker of enterotoxicity as alkaline phosphatase.

The main goal of our present study was to setup the experimental conditions by testing biochemical parameters (enzymes), which may enable follow-up of controlled intestinal mucosa damage, induced by 5-FU, as well as to test whether glutamine decreases or prevents this damage. Therefore, we presented the results of this investigation.

## MATERIAL AND METHODS

In our study, we used Sprague Dawley rats, body weight of 250 g approximately. The control group of rats included 50 animals, while the experimental groups where either 5-fluorouracil (5-FU) alone or 5-FU and glutamine were administered, included 200 animals. All experimental animals were further stratified according to the experimental model (25 animals in each of 8 experimental subgroups of animals). The animals received standard nutritive formula for rats. The 5-FU was administered by intraperitoneal application. Water solution of 1% glutamine was prepared daily and administered orally for 7 days after the 5-FU, in volume of 200 ml.

The dose of 5-FU administered was 0-400 mg/kg BW (body weight). For the analysis of the dose-dependent effects, we decided to follow-up the enzyme activity on 7th day after the administration of 0, 100, 200, 300, and 400 mg of 5-FU per kg of body weight.

The experimental animals were sacrificed according to the experimental plan. The animals in experimental group, which received only 5-FU, were sacrificed 7 days after the single 5-FU dose. The animals in the experimental group, which received the single dose of 5-FU and 7 days later started to drink fresh glutamine solution, were sacrificed after 7 days of oral administration of glutamine.

The isolation of enterocytes was performed according to the method of Kralovansky et al. (11). The enterocytes were obtained by "scrapping" method from the 90 cm long intestine,

starting from the end of duodenum. The mucosa was homogenized in Potter-Elvehjem homogenizer in isotonic KCl with 10 mmol/l mercaptoethanol at 0°C. After the centrifugation on 15000 rpm in Eppendorf centrifuge for the analysis of studied parameters, the supernatant was used, as well as for the total protein content determination by Biuret method. The "scrapping" method provides homogenous experimental material and therefore, all the parameters are calculated according to the exactly measured length of the intestines and the protein content. The isolated cells were collected in one combined cell fraction. The experimental animals were continually observed and all behavioral changes, toxic gastrointestinal damages as well as the survival periods for each animal were recorded.

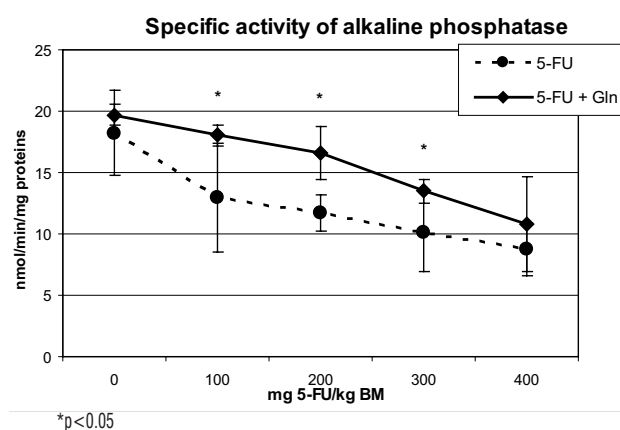
In cell homogenate obtained by described method, we determined the protein content using the Biuret method (12), and the DNA content using the Burton reagent (13). The activities of enzymes alkaline phosphatase (ALP), glutathione S-transferase (GST), glutathione reductase (GR) and glutathione peroxidase (GPX) were determined by kinetic method (13-15). All samples of the small intestine were fixed in 10% formaldehyde, then put into paraffin, cut into 5 µm samples, and stained by haematoxiline and eosine (HE method). The samples prepared according to the methodology described above were analysed qualitatively, by light microscopy, and the digital camera was used for the photographs of samples.

All the experiments were done in duplicate. Results are expressed as mean ± standard error of the mean (SEM). Differences among means were tested for statistical significance by student's two-tailed t-test. Statistical significance was set at  $p < 0.05$ .

## RESULTS

Our study was aimed to investigate the dose-dependent effects of intraperitoneal administration of 5-fluorouracil (5-FU) on intestinal toxicity and to test the possible protective effects of glutamine. According to the results of our preliminary experiments, we have selected the time course and the doses of 5-FU applied intraperitoneally in rats.

Our results showed that the protective effects of oral administration of 1% glutamine solution were present in groups of experimental animals that received 100, 200, and 300 mg 5-FU/kg of body mass. The marker of this protective effect was the statistically significant increase in alkaline phosphatase activity in the samples of intestinal mucosa from the rats which received orally the 1% glutamine solution after the intraperitoneal application of 5-FU (Figure 1). The increased activity of alkaline phosphate in this group of animals may be the result of the stimulation of cell membrane stabilization, induced by oral administration of fresh glutamine solution.

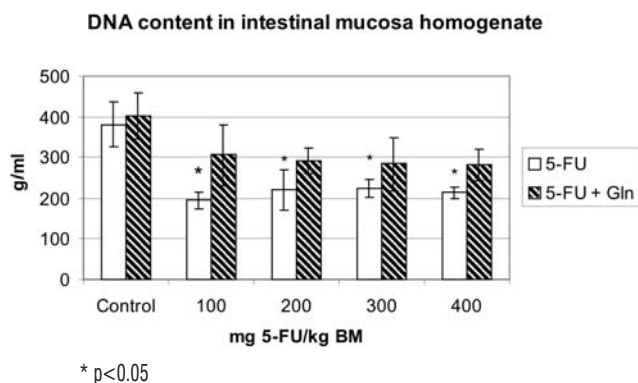


**Figure 1.** The comparison of specific activity of alkaline phosphatase in intestinal mucosa of two groups of experimental animals treated by 5-FU, with and without glutamine administration. The statistically significant differences between two groups are indicated by asterisk.

The effects of the intestinal toxicity induced by 5-FU on DNA content and glutathione-associated enzymes are shown in figures 2-4. For the analysis of glutathione-associated enzymes and for the qualitative histopathological analysis, we selected the animals which

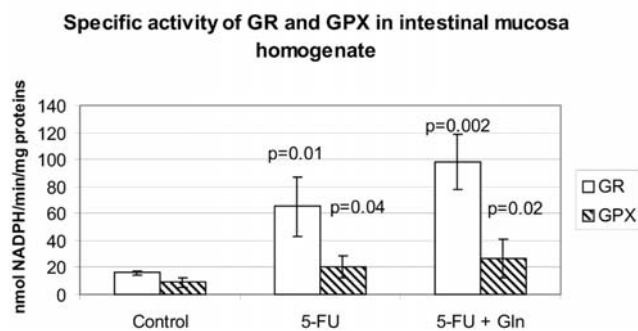
received 200 mg/kg BW of 5-FU alone and with glutamine, according to the results of the activity of alkaline phosphatase in this subgroups of animals.

In Figure 2, we showed that the 5-FU application induced the statistically significant decrease of the DNA content in samples of intestinal mucosa homogenates in comparison with the samples from animals in control group, for each dose of 5-FU applied. This decrease in DNA content was not observed in 5-FU + glutamine subgroups in comparison with the control group.

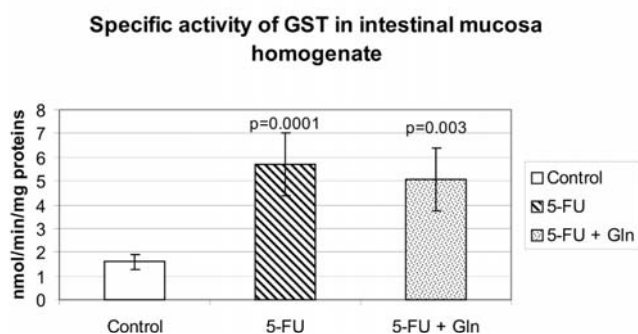


**Figure 2.** DNA content in intestinal mucosa homogenate. The statistically significant differences between control and 5-FU subgroups are indicated by asterisk.

The Figure 3 is showing that the application of 200 mg/kg BW of 5-FU induced the statistically significant increase of the GR and GPX activity. This increase was even more evident in the samples of the animals receiving 5-FU + glutamine, which is a precursor of glutathione, the substrate of GR and GPX. The similar dynamics of enzyme activity is shown on Figure 4, where the application of 5-FU alone and 5-FU + glutamine induced the statistically significant increase of the GST activity.

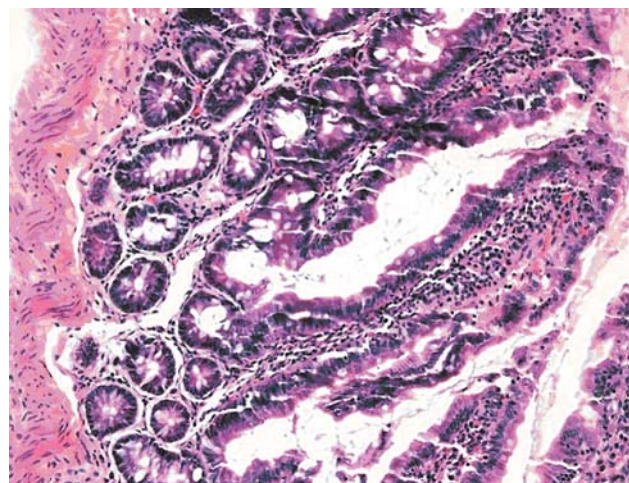


**Figure 3.** Specific activity of GR and GPX in intestinal mucosa homogenate.

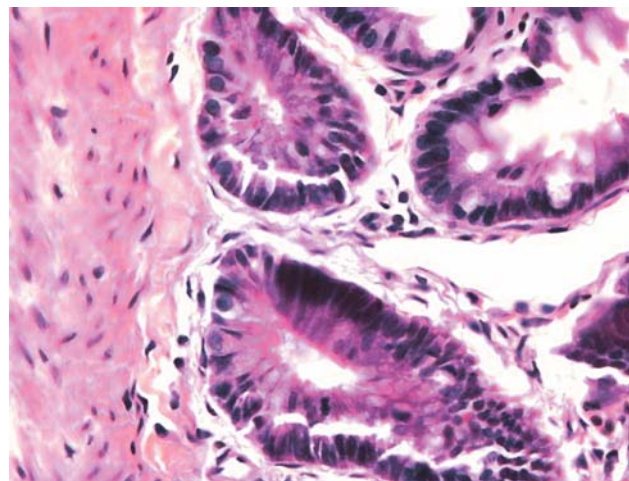


**Figure 4.** Specific activity of GST in intestinal mucosa homogenate.

Qualitative histopathological analysis of the samples from the control group of animals showed that they are the small intestine samples (results not shown). On the surface of the intestine, the villi are characterised by adequate height and width, by the presence of cylindrical epithelium and adequate number of goblet cells and intraepithelial lymphocytes. The brush border is preserved. The crypt space is of adequate height. The crypts are regularly distributed and lined by cylindrical epithelium with adequate number of goblet cells. The adequate number of mitoses is present in the epithelium of cryptal bases. The lamina propria is modestly oedematous and slightly infiltrated with lymphocytes and plasma cells. The samples from the group of animals with intraperitoneal application of 5-fluorouracil, showed that they are the small intestine samples. In all samples thin and long villae are present, and covered by typical epithelium (Figure 5). The crypts are of adequate depth, but modestly of irregular distribution. Some crypts are slightly dilated. Epithelium of crypts is cylindrical, with adequate number of goblet cells and modestly increased number of mitoses within the epithelium of cryptal bases (Figure 6).



**Figure 5.** General view of the small intestine mucosa in the group 5-FU (HE, 10 X 20)



**Figure 6.** Small intestine crypts in the mucosa of the animals receiving 5-FU (HE, 10 x 40)

In all samples of small intestine from the animals that orally received the glutamine solution after the intraperitoneal application of 5-FU, intestinal villae are of adequate height and width, covered by cylindrical epithelium with an adequate number of goblet cells and intraepithelial lymphocytes. The brush border is preserved (Figure 7). The crypt space is of adequate height. The crypts are regularly distributed, with regular diameter, and lined by cylindrical epithelium with adequate number of goblet cells. The adequate number of mitoses is present in the epithelium of cryptal bases. The lamina propria is slightly infiltrated with lymphocytes and plasma cells (Figure 8).

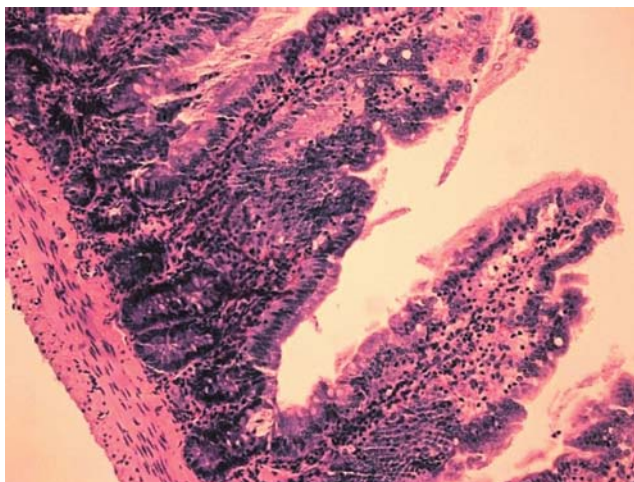


Figure 7. General view of the small intestine mucosa in the group 5-FU + glutamine (HE, 10 X 10)

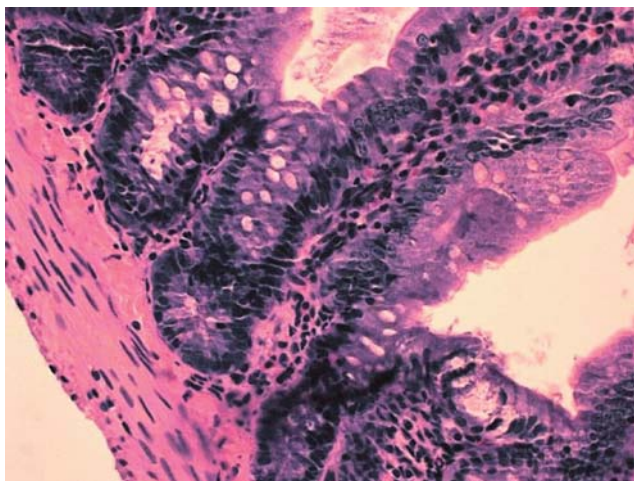


Figure 8. Small intestine crypts in the mucosa of the animals receiving 5-FU + glutamine (HE, 10 x 40)

## DISCUSSION

The current experimental observations in rat intestinal mucosa are consistent with our previous findings in methotrexate-mediated injury and demonstrate that a reduction in mucosal alkaline phosphatase activity appears to be a potential marker of injury induced by antitumor drugs (8). This easily assessable enzyme allows a clear distinction between reparable and irreversible damage and could prove to be a valuable tool in the further characterization of cytotoxic phenomena. Such measurements may prove to be important in the quantitative evaluation of therapeutic interventions in human intestinal toxicity and determination of tolerable doses of antitumor drugs.

In the relevant animal models described in our study, we found that alkaline phosphatase activity was significantly reduced by 5-FU, but not significantly affected after the glutamine supplementation. In contrast, glutathione *S*-transferase, glutathione reductase and glutathione peroxidase, showed the increase in enzyme activity after 5-FU, which is in accordance with the findings of other authors that these enzymes are involved in the protection from chemically induced intestinal damage (16,17).

The significant dose-dependent decrease in ALP activity in intestinal mucosa may be the result of two phenomena: the downregulation of the expression of ALP enzyme and the inhibition of DNA synthesis, showed by the decline in DNA content. On the other hand, the significant increase in glutathione-dependent enzymes may be the consequence of the up-regulation of the expression of these enzymes, induced by oxidative stress. It is important

to emphasize that the glutamine supplementation is very important for the activity of glutathione-dependent enzymes, since the glutamine is one of the three constitutive amino acids in glutathione, one of the major parts of cellular antioxidative mechanisms (10,18).

Qualitative histopathological analysis of the small intestine from the animals in the control group showed the normal characteristics of the epithelium of villae and crypts, with very small number of cells in lamina propria. Therefore, this sample may be considered as the normal sample of small intestine. The same finding is present in the sample from the animals in the group that only received orally the glutamine solution.

The qualitative analysis of the small intestine samples from the animals in the group that intraperitoneally received the bolus dose of 5-FU showed that observed changes were not dose-dependent.

By intraperitoneal application of antitumor drugs, direct enterotoxicity is avoided. According to the fact that the life cycle of enterocytes is 3-6 days, for the significant histopathological changes and for the effects on DNA of enterocytes, the histopathological analysis should be performed later than 7 days after the application of 5-FU. After 7 days from the application of 5-FU only functional changes of protein synthesis may be present, without morphological alterations on cellular level. Our hypothesis is that the morphological changes may be visible if using the electron microscopy, such as lowering of the brush border epithelium, or the decrease of the number of certain organelles (e.g. rough endoplasmic reticulum). If the changes are followed longer, our hypothesis is that we may expect the decrease of the proliferative capacity and of the number of mitoses in the epithelium of crypt bases. It may be concluded from our histopathological analysis, that the intraperitoneally administered 5-FU mainly exerted its effect on the intestinal cells by systemic exposure from the basal side.

It is well known that the glutathione system is one of the major mechanisms in reducing oxidative stress. Many studies showed that glutamine-supplemented nutrition can enhance tissue glutathione levels and that it is associated with improved survival after 5-fluorouracil administration. Glutamine can act as a source of glutamate in many tissues such as liver or skeletal muscle and it has been shown to preserve total glutathione levels after injury/ischemia in both hepatic and gut models. It has been shown that the gut barrier protection by glutamine could possibly be due to glutathione synthesis, by scavenging reactive oxygen intermediates and decreasing the formation of free radicals. Glutamine has been shown to induce the expression of heat shock proteins (HSP) in intestinal cells and this could be one of the mechanisms of protection. Studies have shown that glutamine protection is independent of HSP induction and dependent of glutathione augmentation during surgical stress (10,19-21).

Furthermore, a decrease in alkaline phosphatase activity was found to be a good indicator for assessing the severity of intestinal injury, which was dose dependent. The above findings clearly demonstrate that intestinal brush border membrane alkaline phosphatase could serve as an important marker of toxic injury.

## REFERENCES

- Lorenz B, Schröder HC. Mammalian intestinal alkaline phosphatase acts as highly active exopolyphosphatase. *Biochim Biophys Acta* 2001;1547:254-61.
- Mahmood S, Kaur K, Mittal N, Mahmood A. *Giardia lamblia*: Expression of alkaline phosphatase activity in infected rat intestine. *Experimental Parasitology* 2005;110:91-5.
- Sogabe N, Mizoi L, Asahi K, Ezawa I, Goseki-Sone M. Enhancement by lactose of intestinal alkaline phosphatase expression in rats. *Bone* 2004;35:249-55.
- Inomata A, Horii I, Suzuki K. 5-Fluorouracil-induced intestinal toxicity: what determines the severity of damage to murine intestinal crypt epithelia? *Toxicology Letters* 2002;133:231-40.
- Sisley AC, Desai TR, Hynes KL, Gewertz BL, Pradep KD. Decrease in mucosal alkaline phosphatase: A potential marker of intestinal reperfusion injury. *J Lab Clin Med* 1999;133:335-41.
- Grem JL. 5-Fluorouracil: forty-plus and still ticking. A review of its preclinical and clinical development. *Investigational New Drugs* 2000;18:299-313.
- Longley DB, Harkin DP, Johnston PG. 5-Fluorouracil: mechanisms of action and clinical strategies. *Nature Reviews Cancer* 2003;3:330-8.

8. Bajin-Katić K, Stankov K, Kovačević Z. Changes of biochemical parameters in rat intestinal mucosa induced by methotrexate and effects of enteral administration of glutamine. *Arch Oncol* 2004;12:35-8.
9. Sánchez de Medina F, Martínez-Augustin O, González R, Ballesterá I, Nieto A, Gálvez J, et al. Induction of alkaline phosphatase in the inflamed intestine: a novel pharmacological target for inflammatory bowel disease. *Biochemical Pharmacology* 2004;68:2317–26.
10. Thomas S, Balasubramanian KA. Role of intestine in postsurgical complications: involvement of free radicals. *Free Radical Biology & Medicine* 2004;36:745–56.
11. Kralovanszky J, Prajda N. Biological changes of intestinal epithelial cells induced by cytostatic agents in rats. *Arch Toxic* 1985;8:94-103.
12. Gornall AG, Bardawill CJ. Determination of serum proteins by means of the biuret reaction. *J Biol Chem* 1949;177:751-6.
13. Plummer DT. *An introduction to practical biochemistry*. 3<sup>rd</sup> ed. London: McGraw Hill Book Co; 1971. p. 205.
14. Habig WH, Pabst MJ, Jakoby WB. Glutathione S-transferases. The first enzymatic step in mercapturic acid formation. *J Biol Chem* 1974;249:7130-9.
15. Beutler E. *Red cell metabolism. A manual of biochemical methods*. 2<sup>nd</sup> ed. New York: Grune & Stratton; 1975.
16. Nomani H, Ghobadloo SM, Yaghmaei B, Rezvanie NA, Yaghmaei K. Glutathione S-transferase activity in patients with colorectal cancer. *Clin Biochem* 2005;38:621-4.
17. Esworthy RS, Swiderek KM, Ho YS, Chu FF. Selenium-dependent glutathione peroxidase-G1 is a major glutathione peroxidase activity in the mucosal epithelium of rodent intestine. *Biochim Biophys Acta* 1998;1381:213-26.
18. Stankov K, Kovačević Z. Oxidative stress and glutathione-associated antioxidative systems in malignant cells. *Arch Oncol* 1998;6:109-13.
19. Hong RW, Helton WS, Rounds JD, Wilmore DW. Glutamine supplemented TPN preserves hepatic glutathione and improves survival following chemotherapy. *Surg Forum* 1990;41:9-11.
20. Harward TR, Coe D, Souba WW, Klingman N, Seeger JM. Glutamine preserves gut glutathione levels during intestinal ischemia/reperfusion. *J Surg Res* 1994;56:351-5.
21. Prabhu R, Thomas S, Balasubramanian KA. Oral glutamine attenuates surgical manipulation-induced alterations in the intestinal brush border membrane. *J Surg Res* 2003;115:148-56.