



## The effect of intravitreal administration of bevacizumab on macular edema and visual acuity in age-related macular degeneration with subfoveolar choroidal neovascularisation

Uticaj intravitrealne primene bevacizumaba na edem makule i oštrinu vida kod senilne degeneracije žute mrlje sa supfoveolarnom horoidnom neovaskularizacijom

Dragana Ristić\*, Miroslav Vukosavljević\*<sup>†</sup>, Biljana Draganić\*,  
Vesna Cerović\*, Nenad Petrović\*, Mirjana Janičijević-Petrović<sup>‡</sup>

\*Ophthalmology Clinic, Military Medical Academy, Belgrade Serbia; <sup>†</sup>Faculty of Medicine of the Military Medical Academy, University of Defence, Belgrade, Serbia;  
<sup>‡</sup>Department of Ophthalmology, Clinical Center of Kragujevac, Kragujevac, Serbia

### Abstract

**Background/Aim.** Age-related macular degeneration (AMD) is a leading cause of the loss of central visual acuity in population older than 70 years. We can distinguish wet and dry form of AMD. The aim of the study was to present our early results in treatment of the wet (neovascular) form of AMD with intravitreal administration of bevacizumab. **Methods.** The study included 39 patients. Each patient underwent a complete ophthalmological examination, fluorescein angiography (FA) and optical coherence tomography (OCT). All the patients received 1.25 mg of intravitreal bevacizumab (0.05 mL of commercial phial of Avastin®). The total of three doses was given with a one-month interval between doses. **Results.** Among 39 patients, 24 were women and 15 men. The average best corrected visual acuity (BCVA) was improved from 0.09 before the therapy to 0.24 after the administration of all the three doses of bevacizumab ( $p < 0.001$ ). The average central macular thickness (CMT) measured by OCT was improved from 474  $\mu\text{m}$  in the beginning to 341  $\mu\text{m}$  after the administration of all the three doses of the drug ( $p < 0.001$ ). There were no side effects. **Conclusions.** Our short-term experience indicates that intravitreal administration of three doses of bevacizumab in one-month intervals between the doses leads to a significant reduction of macular edema and improvement of BCVA in patients with neovascular AMD.

### Key words:

antibodies monoclonal; angiogenesis inhibitors; macular degeneration; choroidal neovascularisation; treatment outcome.

### Apstrakt

**Uvod/Cilj.** Starosna degeneracija žute mrlje (*age-related macular degeneration* – AMD) glavni je uzročnik gubitka centralne oštrine vida kod osoba starijih od 70 godine. Postoje vlažna i suva forma AMD. Cilj rada bio je prikaz rezultata u lečenju vlažne (neovaskularne) forme AMD intravitrealnom primenom bevacizumaba. **Metode.** U radu je prikazano 39 bolesnika. Kod svakog bolesnika urađen je kompletan oftalmološki pregled, fluoresceinska angiografija (FA) i optička koherentna tomografija (*optical coherence tomography* – OCT). Svi bolesnici su primili intravitrealno 1,25 mg bevacizumaba (0,05 mL komercijalnog preparata Avastin®). Ukupno su date tri doze u razmacima po mesec dana između doza. **Rezultati.** Od 39 bolesnika, 24 osobe bile su ženskog, a 15 muškog pola. Prosečna najbolje korigovana vidna oštrina (*best corrected visual acuity* – BCVA) popravila se sa 0,09 pre terapije, na 0,24 nakon primene sve tri doze bevacizumaba ( $p < 0,001$ ). Prosečna centralna debljina makule (*central macular thickness* – CMT), merena OCT aparatom, popravila se sa 474  $\mu\text{m}$  na početku lečenja na 341  $\mu\text{m}$  nakon primene sve tri doze leka ( $p < 0,001$ ). Nije bilo nikakvih neželjenih efekata. **Zaključak.** Naše kratkoročno iskustvo govori u prilog tome da bevacizumab, primenjen intravitrealno u tri doze u razmacima po mesec dana, dovodi do značajnog smanjenja edema makule i poboljšanja BCVA kod bolesnika sa neovaskularnom AMD.

### Ključne reči:

antitela, monoklonska; angiogeneza, inhibitori; makularna degeneracija; horoidalna neovaskularizacija; lečenje, ishod.

**Introduction**

Age-related macular degeneration (AMD) is a leading cause of the loss of central visual acuity in population older than 70 years. We can distinguish wet and dry form of AMD. Wet or exudative (neovascular) form is characterized by the presence of a choroidal neovascular membrane (CNV) which is related to higher retinal blood vessel permeability and neoangiogenesis. One of the underlying causes of these vascular changes is the activity of an isoform of vascular endothelial growth factor (VEGF) called VEGF-A.

VEGF-A presents in various isoforms (VEGF<sub>121</sub>, VEGF<sub>145</sub>, VEGF<sub>165</sub>, VEGF<sub>189</sub>, VEGF<sub>206</sub>)<sup>1</sup>. All these isoforms can be bound by bevacizumab which is its advantage over other available VEGF-A inhibitors (pegaptanib, ranibizumab). Molecular weight of bevacizumab (149 kDa), longer half-life and ability to reach subretinal space through the circulation explain its better results in the management of neovascular AMD.

Bevacizumab (Avastin<sup>®</sup>) is a monoclonal VEGF-anti body approved for intravenous use in the management of colorectal carcinoma. Off-label intravenous administration of this medication in neovascular AMD treatment was firstly published by Michels et al. in 2005<sup>2</sup>. Shortly after this many other articles about intravitreal administration of bevacizumab in neovascular AMD treatment have followed<sup>3-8</sup>.

The aim of this article was to present our initial results in monitoring macular edema reduction and its correlation with visual acuity after intravitreal administration of bevacizumab to patients with neovascular AMD.

**Methods**

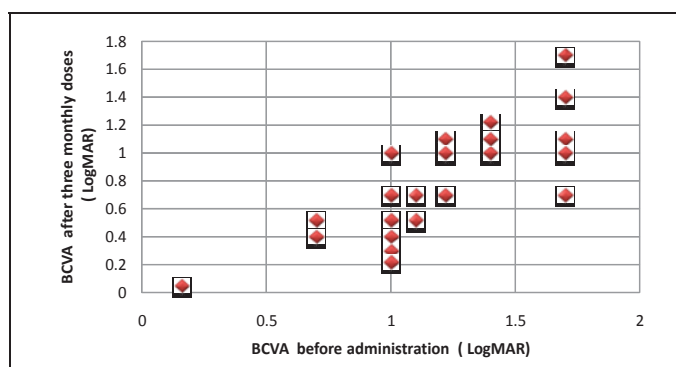
The participants in our study were 39 patients with subfoveolar CNV related to AMD. Intravitreal administration of

mac were applied at one-month intervals. The patients were followed up on first, seventh and thirtieth day. A complete ophthalmological examination was performed on each patient, including best corrected visual acuity (BCVA), fluorescein angiography (FA), and optical coherence tomography (OCT). Visual acuity and OCT were performed at each control examination, while FA was only performed during the initial examination and then one month following the third bevacizumab dose.

Best-corrected visual acuity, originally expressed in meters, was converted into logarithm of the minimum angle of resolution (LogMAR) for more accurate analyses. For statistical analysis we used the Friedman ANOVA test and Wilcoxon test with  $p < 0.001$  considered highly statistically significant.

**Results**

We analyzed 39 patients; among them 24 were woman and 15 were man. The average age was 73.5 (64–83) years. Visual acuity and OCT were measured prior to the intervention and followed up at regular check-ups on the 7th and 30th day following the intervention. The average visual acuity before the intervention was 0.09. After three months and three monthly doses of bevacizumab applied over that period, the average visual acuity was 0.24 ( $p < 0.001$ ). One month after the first dose, BCVA was 0.20 ( $p < 0.001$ ) and one month after the second dose it was 0.22 ( $p < 0.05$ ). In our study BCVA of 34 (87.2%) eyes improved and of 5 (12.8%) eyes remained the same. We had no cases of visual acuity worsening. Seven (17.95%) eyes showed visual acuity improvement of one row and 13 (33.3%) eyes improved by two rows. Eventually, 5 (12.82%) eyes showed improvement of the stunning five rows (Figure 1, Table 1).



**Fig. 1 – Change in best corrected visual acuity (BCVA) after the administration of three monthly doses of bevacizumab MAR – minimum angle of resolution.**

bevacizumab was approved by the Ethics Committee of the Military Medical Academy (MMA). All the patients were informed about off-label usage of this medication, about possible side effects and complications but also about potential benefit from this treatment. All the patients signed a written consent form prior to drug administration. Every patient received 1.25 mg of bevacizumab (0.05 mL of commercial phial of Avastin<sup>®</sup> intravitreally). Three doses of bevacizu-

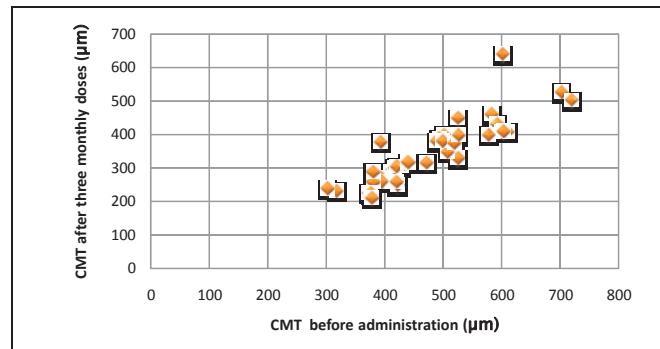
**Table 1  
The average best corrected visual acuity (BCVA) after the administration of bevacizumab**

Time (months)	Average BCVA (m)	<i>p</i>
0	0.09	
1	0.20	< 0.001
2	0.22	< 0.05
3	0.24	< 0.001

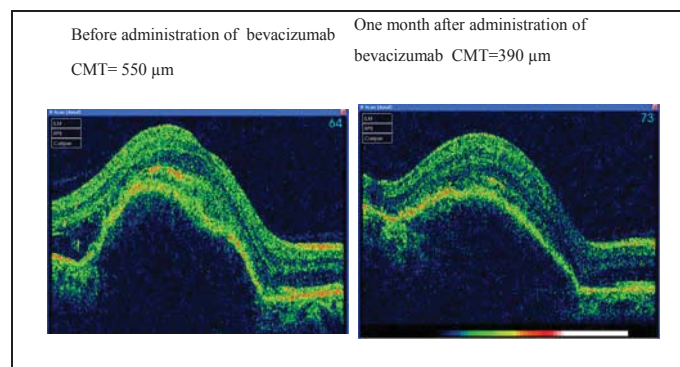
The average central macular thickness (CMT) measured by OCT prior to the intervention was 474  $\mu\text{m}$ , and three months following three doses of bevacizumab it was 341  $\mu\text{m}$  ( $p < 0.001$ ). After the administration of all the three doses of bevacizumab, the average macular edema reduction was 132  $\mu\text{m}$ . Every eye showed an improvement in CMT reduction, although in 5 eyes BCVA did not improve (Figures 2 and 3, Table 2).

as gastrointestinal bleeding, thromboembolism and arterial hypertension, intravitreal bevacizumab administration applied in our study proved to be free of any systemic and local complications.

There are several anti-VEGF medications registered for intravitreal administration worldwide. Pegaptanib was the first in this group to be accepted for wet AMD form treatment. Shortly after this one, ranibizumab was registered for



**Fig. 2 – Change in central macular thickness (CMT) ( $\mu\text{m}$ ) measured by optical coherence tomography (OCT) after the administration of three monthly doses of bevacizumab.**



**Fig. 3 – Central macular thickness (CMT) measured by optical coherence tomography (OCT) before and after administration of bevacizumab.**

**Table 2**  
**Average central macular thickness (CMT) measured by optical coherence tomography (OCT) after administration of bevacizumab**

Time (months)	Average CMT ( $\mu\text{m}$ )	$p$
0	474	
1	402	< 0.001
2	374	< 0.001
3	341	< 0.001

## Discussion

Most of the eyes treated with bevacizumab in this study showed attempted improvement, both morphological and functional response. Our results confirm a significantly higher reduction of macular edema and improvement of BCVA in patients with neovascular AMD.

While systemic bevacizumab administration was related to increased risk for complications and adverse effects such

intravitreal administration. Ranibizumab (Lucentis<sup>®</sup>) was approved for intravitreal administration by the American Food and Drug Administration in 2006. This decision was based on the results presented in MARINA and ANCHOR studies. These studies proved ranibizumab efficiency<sup>3,9</sup>.

As previously mentioned, Avastin<sup>®</sup> was introduced in ophthalmology in 2005 and soon after that several studies about its efficiency in treatment of wet AMD form followed. Fong et al.<sup>10</sup> reported in their study that there was no statistically significant difference regarding BCVA improvement between groups receiving bevacizumab and ranibizumab. After the reports about similar efficiency of these two medications we decided to use significantly less expensive bevacizumab in our study.

Our study was based on updated results, published worldwide, about intravitreal bevacizumab administration. A precise dose of the used medication and timeline in the treatment protocol varied among the studies. Most frequently used doses were 1.25 mg and 2.5 mg of bevacizumab. Based

on the published data that imply no statistically significant difference between the two doses in BCVA improvement and CMT reduction, we chose the lower one for our study.

Ghazi et al.<sup>11</sup> applied bevacizumab only once and then decided about continuing with the next dose based on clinical evaluation. In studies published by Bashshur et al.<sup>5</sup> and Avery et al.<sup>4</sup> bevacizumab was applied three times in one-month intervals between the doses. It is considered that anti VEGF effect of bevacizumab starts after approximately 24 h from administration and persists for 2–3 weeks<sup>12</sup>. Conrad et al.<sup>8</sup> in 2008 considered that bevacizumab effect might last up to 8 weeks after administration. We assume that this periodic administration provides better VEGF inhibition and, consequently, faster CNV retrieval. This was our reason to accept three doses protocol with one month between doses.

## Conclusion

Today many ophthalmologists worldwide use anti-VEGF treatment, particularly bevacizumab for neovascular AMD.

In our study we used three doses of the drug with one-month period between each one. Results showed a significant difference in improving visual acuity and reducing macular edema. It is also important to point out that we did not have any complications in this study.

Still, the decision which protocol of administration is the best one remains uncertain. For this reason we believe that summing up all our experiences may bring us one step closer to more decisive criteria and most effective protocol for neovascular AMD treatment with intravitreal bevacizumab administration.

## R E F E R E N C E S

1. *Churchill AJ, Carter JG, Lovell HC, Ramsden C, Turner SJ, Yeung A, et al.* VEGF polymorphisms are associated with neovascular age-related macular degeneration. *Hum Mol Genet* 2006; 15(19): 2955–61.
2. *Michels S, Rosenfeld PJ, Puliafito CA, Marcus EN, Venkatraman AS.* Systemic bevacizumab (Avastin) therapy for neovascular age-related macular degeneration twelve-week results of an uncontrolled open-label clinical study. *Ophthalmology* 2005; 112(6): 1035–47.
3. *Rosenfeld PJ, Moshfeghi AA, Puliafito CA.* Optical coherence tomography findings after an intravitreal injection of bevacizumab (avastin) for neovascular age-related macular degeneration. *Ophthalmic Surg Lasers Imaging* 2005; 36(4): 331–5.
4. *Avery RL, Pieramici DJ, Rabena MD, Castellarin AA, Nasir MA, Giust MJ.* Intravitreal bevacizumab (Avastin) for neovascular age-related macular degeneration. *Ophthalmology* 2006; 113(3): 363–72.e5.
5. *Bashshur ZF, Bazarbachi A, Schakal A, Haddad ZA, El Haibi CP, Noureddin BN, et al.* Intravitreal bevacizumab for the management of choroidal neovascularization in age-related macular degeneration. *Am J Ophthalmol* 2006; 142(1): 1–9.
6. *Rich RM, Rosenfeld PJ, Puliafito CA, Dubovy SR, Davis JL, Flynn HW Jr, et al.* Short-term safety and efficacy of intravitreal bevacizumab (Avastin) for neovascular age-related macular degeneration. *Retina* 2006; 26(5): 495–511.
7. *Spaide RF, Laud K, Fine HF, Klanicnik JM Jr, Meyerle CB, Yanuzzi LA, et al.* Intravitreal bevacizumab treatment of choroidal neovascularisation secondary to age-related macular degeneration. *Retina* 2006; 26(4): 383–90.
8. *Conrad PW, Zacks DN, Johnson MW.* Intravitreal bevacizumab has initial clinical benefit lasting eight weeks in eyes with neovascular age-related macular degeneration. *Clin Ophthalmol* 2008; 2(4): 727–33.
9. *Brown DM, Kaiser PK, Michels M, Soubrane G, Heier JS, Kim RY, et al.* Ranibizumab versus verteporfin for neovascular age-related macular degeneration. *N Engl J Med* 2006; 355(14): 1432–44.
10. *Fong DS, Custis P, Howes J, Hsu JW.* Intravitreal bevacizumab and ranibizumab for age-related macular degeneration a multicenter, retrospective study. *Ophthalmology* 2010; 117(2): 298–302.
11. *Ghazi NG, Kirk TQ, Knappe RM, Tiedeman JS, Conway BP.* Is monthly retreatment with intravitreal bevacizumab (Avastin) necessary in neovascular age-related macular degeneration? *Clin Ophthalmol* 2010; 4: 307–14.
12. *Welch DE, Elmariab H, Peden MC, Adams SG, Ratnakaram R, Kaushal S.* Short-term response of macular oedema to intravitreal bevacizumab. *Br J Ophthalmol* 2009; 93(8): 1033–6.

Received on March 11, 2011.

Revised on July 18, 2011.

Accepted on July 19, 2011.

Online-First December, 2012.