



Splenic artery pseudoaneurysm as a complication of pancreatic pseudocyst

Pseudoaneurizma slezinske arterije kao komplikacija pseudociste pankreasa

Saša Micković*, Miroslav Mitrović*, Nebojša Stanković*,
Mihailo Bezmarević*, Milan Jovanović*, Darko Mirković*, Ivana Tufegžić†,
Irena Nikolić Micković‡

Military Medical Academy, *Clinic for Abdominal and Endocrine Surgery,
†Institute for Pathology; ‡ University Children's Hospital, Belgrade, Belgrade, Serbia

Abstract

Introduction. Pancreatic pseudocyst presented as pseudoaneurysm of the splenic artery is a potential serious complication in patients with chronic pancreatitis. **Case report.** A 42-year-old male patient with a long-standing evolution of chronic pancreatitis and 8-year long evolution of pancreas pseudocyst was referred to the Military Medical Academy, Belgrade due to worsening of the general condition. At admission, the patient was cachectic, febrile, and had the increased values of amylases in urine and sedimentation (SE). After clinical and diagnostic examination: laboratory assessment, esophagogastroduodenoscopy (EGDS), ultrasonography (US), endoscopic ultrasonography (EUS), multislice computed scanner (MSCT) angiography, pseudoaneurysm was found caused by the conversion of pseudocyst on the basis of chronic pancreatitis. The patient was operated on after founding pancreatic pseudocyst, which caused erosion of the splenic artery and their mutual communication. Postoperative course was duly preceded without complications with one year follow-up. **Conclusion.** Angiography is the most reliable and the safest method for diagnosing hemorrhagic pseudocysts when they clinically present as pseudoaneurysms. A potentially dangerous complication in the presented case was treated surgically with excellent postoperative results.

Key words:

pancreatitis, chronic; pancreatic pseudocyst; aneurysm, false; hypertension, portal; splenic artery; splenic vein; venous thrombosis; digestive system surgical procedures; diagnosis; treatment outcome.

Apstrakt

Uvod. Pankreasna pseudocista koja se prezentuje kao pseudoaneurizma slezinske arterije je potencijalno opasna komplikacija kod bolesnika sa hroničnim pankreatitisom. **Prikaz bolesnika.** Bolesnik, star 42 godine, sa dugogodišnjim hroničnim pankreatitisom i osmogodišnjom evolucijom pseudociste pankreasa primljen je u Vojnomedicinsku akademiju, Beograd zbog pogoršanja opšteg stanja. Na prijemu, bolesnik je bio kahektičan, febrilan, sa povišenom vrednošću amilaze u urinu i povišenom sedimentacijom (SE). Nakon kliničke i dijagnostičke evaluacije: laboratorijski nalazi, ezofagogastroduodenoskopija (EGDS), ultrazvučni pregled (US) abdomena, endoskopski ultrazvučni (EUS) pregled, multislajnska skenerska (MSCT) angiografija, nađena je pseudoaneurizma koja je nastala konverzijom pseudociste na bazi hroničnog pankreatitisa. Bolesnik je operisan kada je nađena pseudocista pankreasa koja je dovela do erozije slezinske arterije i njihove međusobne komunikacije. Postoperativni tok prošao je uredno, sa praćenjem bolesnika u narednih godinu dana bez komplikacija. **Zaključak.** Angiografija je najpouzdanija i najsigurnija metoda za dijagnostikovanje hemoragične pseudociste, koja se klinički prezentuje kao pseudoaneurizma. Kod prikazanog bolesnika potencijalno opasna komplikacija lečena je hirurški sa odličnim postoperativnim rezultatom.

Ključne reči:

pankreatitis, hronični; pankreas, pseudocista; pseudoaneurizma; hipertenzija, portalna; a. splenica; v. splenica; tromboza, venska; hirurgija digestivnog sistema, procedure; dijagnoza; lečenje, ishod.

Introduction

In recent decades, pancreatic pseudocyst and complications which accompany it¹⁻² have been successfully treated using conservative treatment without surgery³⁻⁵. There are

clear advantages of new techniques development and modern achievements over the conventional surgical management, but only in clearly defined indications with acceptable risk of complications⁶. However, in cases with the pseudocyst additionally complicated with hemorrhage^{1,2}, in the literature

the state known as conversion of pseudocyst in pseudoaneurysm, and evolution of regional left-sided portal hypertension (LPH), surgery takes place as the most important method for treatment of this serious complication⁷⁻⁹. One of a few surgical procedures that may be a method of choice in hemorrhage and/or rupture of cysts and/or pseudoaneurysms is distal spleno-pancreatectomy^{1,2,9}.

Case report

A patient, at the age of 42, was admitted to the Clinic for Gastroenterology, Military Medical Academy, Belgrade, due to chronic pseudocyst in pancreatic tail region for eight years. Lately, the patient had attacks of pain followed by nausea and vomiting. In the last 15 years the patient consumed alcoholic drinks regularly and in several occasions he had attacks of acute pancreatitis. On admission, he had abdominal pain without jaundice, febrile to 38.5°C. Objective findings were palpable and painful tumefaction and rough systolic auscultation with murmur in the region of epigastrium. Pancytopenia dominated in laboratory status with an emphasis on the fall of platelets (PLT) of $50 \times 10^9/L$, sedimentation (SE) 79 mm/Lh, international normalized ratio (INR) 1, and the value of urinary amylase of 1,129 IU/L. Esophagogastroduodenoscopy (EGDS) verified the existence of outside pressure on the fundus area and back wall of the stomach body. Ultrasonography (US) of the abdomen showed the presence of massive calcification, particularly in the area of the pancreatic tail with the existence of pulsating tumefaction with thickened wall in the area of the tail of pancreas. Endoscopic ultrasonography (EUS) showed collection of fluid in the *bursa omentalis*, close to the region of the tail of the pancreas and in the exact region there was a large partially septated collection with flow. Multislice computed tomography (MSCT) angiography of the portal basin showed the number of calcification in the pancreas, enlarged spleen and thrombosis of the splenic vein. Drainage of the spleen was made through the well-developed collaterals around cardio and fundus region of the gizzard and the network of blood vessels which partially went through the frontal abdominal wall. The superior mesenteric vein and portal vein were viable without signs of thrombosis. In the arterial phase there was normal arborization of *truncus coeliacus* and arterial plexus of the liver. Pseudoaneurysm was found in the splenic artery of the size 85 mm × 60 mm which was pulsating (Figure 1).

The patient was presented at a meeting of gastroenterologists, radiologists and surgeons who decided to make surgical intervention.

Intraoperatively, a pulsating formation was found in the region of the body and tail of the pancreas completely filling the space of *bursa omentalis*, forming a hard fibrous structure that was adhered to the transverse colon and transverse mesocolon and the whole back wall of the gizzard. The spleen was dark violet and enlarged of the size about 16 cm × 12 cm × 10 cm with tortuous and rigid splenic artery. The whole pancreas was enlarged and fibrous. Expressed and congested venous collaterals in the gastrosplenic ligament, down to the great curvature of gizzard (vv. *gastri-*

cae breves) were found to the great omentum (*gastroepiploica*) and in retroperitoneum (Figure 2). The gizzard was edematous with hypertrophic front and rear wall.

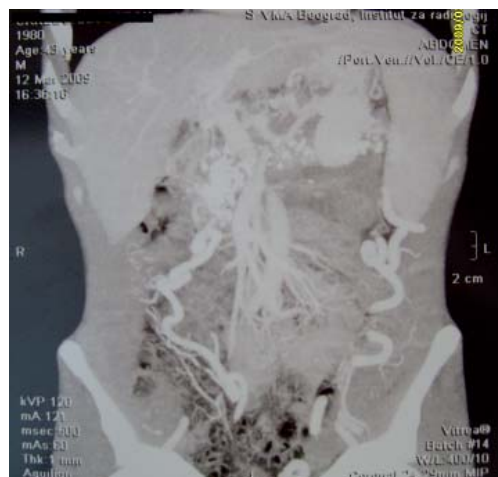

Fig. 1 - Pseudocyst and the enlarged spleen with calcification through the head, body and tail of the pancreas on multislice computed tomography (MSCT) angiography

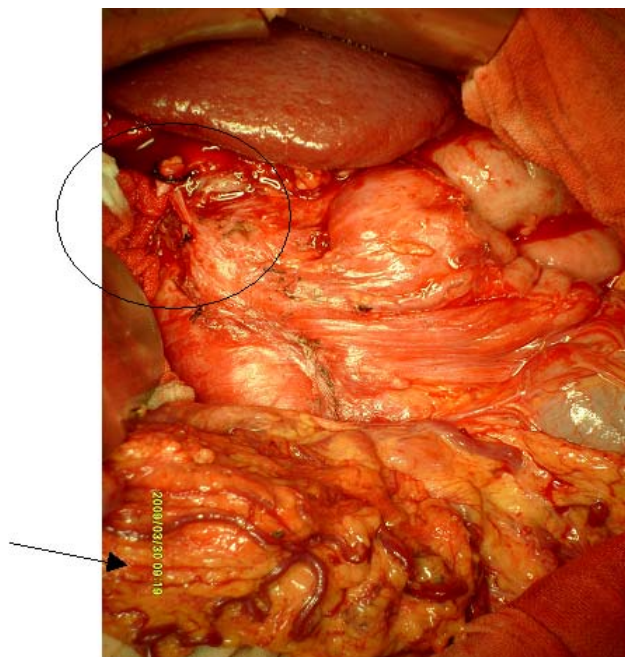


Fig. 2 - Congested venous collaterals, pseudoaneurysm (pseudoaneurysm) and the enlarged spleen

Using transgastrocolic approach we performed meticulous dissection of the gizzard, colon and body and tail of the pancreas, mobilizing the duodenum and the head of the pancreas. Two fine-needle biopsies for *ex tempore* examination were taken from the head and from the junction of the body and tail of the pancreas revealing benign tumor. The splenic artery was double clamped at its beginning and in the splenic hilum (Figure 3). We opened pseudocystic formation at the junction of the body and the tail of the pancreas, which was partly filled with fresh blood, partly with thrombotic masses. After evacuation of the cavity content, the communication

between the lumen of pseudocyst and splenic artery was determined just before branching of the artery. Thrombosis of the splenic vein in the region of pancreatic tail was found. After carefully performed mobilization of the spleen we made splenectomy and distal pancreatectomy with extirpation of pseudoaneurysm and proximal ligation of splenic artery. Wirsung's duct was identified and managed with transfixion suture-ligation.

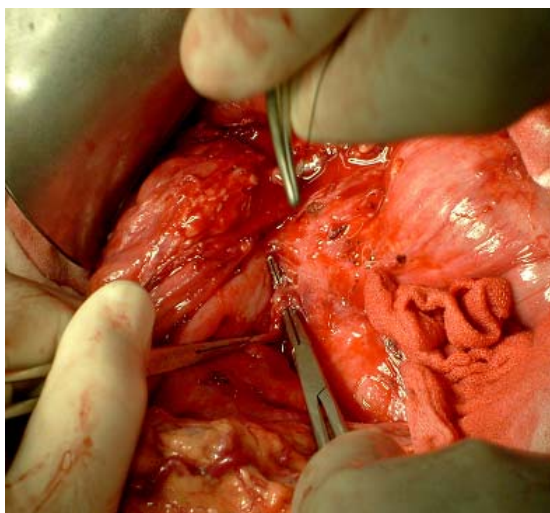


Fig. 3 – Clamping of the splenic artery at each side of pseudoaneurysm

Postoperative course was in order, without bleeding. No pancreatic fistula was registered. The patient was put back to oral food on the 4th postoperative day, and antiaggregation therapy was introduced. The patient was discharged on the 13th postoperative day with thrombocytosis of $950 \times 10^9/L$. One month after discharging thrombocytosis of $1075 \times 10^9/L$ was registered in the patient. The value of amylase in urine and serum was within normal range. US of abdomen registered state after distal splenopancreatectomy without pathological collections in the abdomen. The patient received polyvalent pneumococcal vaccine in dispensary.

Histopathological examination of the extirpated pseudocyst is showed on Figure 4.

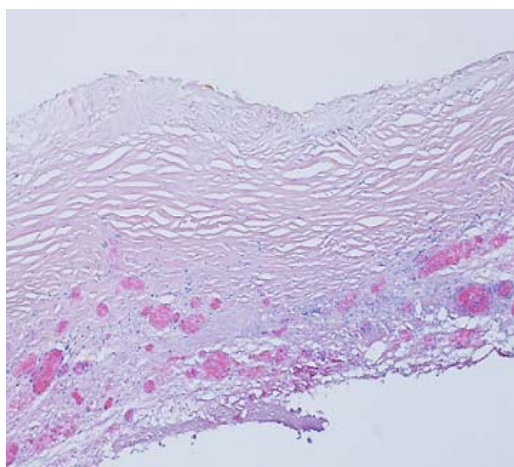


Fig. 4 – Histopathological examination of the extirpated pseudocyst (HE, 5x)

Discussion

Bleeding from pseudoaneurysm based on splenic artery lesions is a potentially fatal complication in patients with chronic pancreatitis. Although rare, it might be caused by trauma^{10, 11}. Pseudoaneurysm can be developed with or without existing pseudocystic formations. If it comes to conversion (erosion of pseudocyst into the adjacent court or blood vessels wall) it may cause fatal complications due to rupture and massive hemorrhage (intraperitoneal, retroperitoneal, into the nearby organs and/or ducts)¹². Bleeding in the bile duct was firstly described by Lower and Farrell¹³ in 1931, and named as “*haemosuccus pancreaticus*” by Sanblom¹⁴ in 1970. Pseudocyst with pseudoaneurysm is present in about 10% of patients with chronic pancreatitis¹⁵. Pseudoaneurysm is caused by enzymatic digestion of blood vessel^{16, 17} and/or local compression of the blood vessel wall by pseudocyst¹⁸. Because of its proximity, the splenic artery is the most frequently affected, about 40%¹⁹. Further, the incidence of isolated pseudoaneurysms of the splenic artery is low¹⁶.

There are still controversy and disagreement in which cases surgery is needed and what is the gold timing for surgery. Several important factors increase the risk of serious acute hemorrhage: duration of chronic pancreatitis, closeness of pseudocyst to the blood vessels (erosion of pancreatic pseudocyst into a nearby blood vessel is a complication with high mortality rate caused by intraabdominal hemorrhage), communication of pseudocyst with the pancreatic and biliary duct, thrombosis and occlusion of the splenic blood vessels^{16, 20}.

In 30% of patients the most common clinical manifestation of pseudoaneurysms is abdominal pain²¹. The incidence of intracystic hemorrhage despite the management and diagnosis varies from 6% to 17%^{22, 23}. Rupture of pseudoaneurysms was found in 31% of patients with pseudocystic complications of the chronic pancreatitis²⁴. According to some authors, the size of pseudoaneurysms from 2 cm to 17 cm is not the cause of their rupture^{10, 25}. The frequency of fatal hemorrhage, as complications of chronic pancreatitis, varies from 1.2% to 14.5% (Table 1)^{20, 26}. Surgical procedures carry a morbidity and mortality risk of 1.3% - 9%^{27, 28}.

Endovascular techniques were successfully applied in 75%–85% of patients with morbidity rate of 14%–25%, and mortality rate of 0%–14%^{4, 28}. The results of these studies do not recommend percutaneous angioembolisation (PAE) as adequate therapy due to the high percentage of failure, more than 20%¹⁶. In treatment of the splenic artery pseudoaneurysm surgical or radiological procedures may be used equally²⁹. While the effectiveness of embolization is undeniable, it depends on the competence of radiologist. Minimally invasive surgical techniques are used as spare solution for patients with good general condition without other complications of pancreatitis³⁰. Previous studies have shown effective and lasting control of bleeding pseudoaneurysm by applying embolization^{29, 31}, even this procedure has been used as the first treatment with success³². Others point out surgery which is always indicated^{17, 10, 32}. Distal pancreatectomy and

Table 1

Classification of hemorrhagic complications in chronic pancreatitis (modified to ref. 12)

(A) Pancreatitis-related
1. Pseudoaneurysms or arterial wall necrosis and rupture
2. Gastric-oesophageal varices [splenic vein thrombosis with left-sided portal hypertension (LPH)]
3. Intracystic hemorrhage from vessels within the pseudocyst wall
4. Splenic rupture
(B) Coexistent pathology
1. Peptic ulceration
2. Gastritis, duodenitis, or stress ulceration
3. Oesophageal varices (alcoholic liver disease with portal hypertension)
4. Mallory – Weiss syndrome

splenectomy is the method of choice for complicated hemorrhagic pseudocyst localized in the tail of the pancreas, with very low morbidity and mortality rate^{32, 35}.

There are several possibilities to solve complicated pseudocysts (greater than 6 cm): 1) percutaneous US application of trombine^{3, 36} (when surgery and endovascular embolization are not feasible or not possible), for first-line treatment³⁶; 2) endoscopic drainage (very effective in many patients with acceptable complication rate; without possibility to control bleeding, this procedure is contraindicated in hemorrhagic pseudocysts); with endoscopic retrograde cholangiopancreatography (ERCP) is effective in the most cases after embolization⁵; 3) surgery⁷⁻¹⁰ (invasive, more traumatic but successful if other procedures fails; there is the possibility to control bleeding^{5, 37}); 4) laparoscopic procedures, but only in elective cases³⁸; 5) endovascular treatment (transcatheter angioembolisation), can be used as the first line treatment^{4, 5, 37}.

The high incidence of morbidity and mortality rate requires an essential and active management and multidisciplinary approach to solving complicated pancreatic pseudocysts and complications which accompany it. An optimal approach is determined by the presentation of patients. Surgery and PAE have complementary role. PAE is recommended as the method for hemodynamically stable patients. Surgery is

reserved for active bleeding, hemodynamically unstable patients, severe pain, poor or failed PAE, as well as other complications such as infection and/or external compression of the surrounded organs¹⁶. In the regional LPH as the result of splenic vein thrombosis is the most common pathology regarding chronic pancreatitis and/or the existence of pseudocyst localized in the tail of the pancreas^{34, 35}. The incidence of isolated splenic vein thrombosis at autopsies in patients with the history of chronic pancreatitis was 20%–40%^{15, 33}. Splenectomy with distal pancreatectomy is the gold standard for resolving vascular lesions of the pancreas¹⁰. Also, splenectomy with distal pancreatectomy (treatment in pancreatic pathology) is a curative method for solving regional LPH^{32, 34}.

Conclusion

Angiography is the most reliable and the safest method for diagnosing hemorrhagic pseudocysts when they clinically present as pseudoaneurysms. Chemoembolization is a method of choice for uncomplicated pseudoaneurysms. In the presented case, a potentially dangerous complication was treated surgically with an excellent postoperative result.

R E F E R E N C E S

1. *Vujic I.* Vascular complications of pancreatitis. *Radiol Clin North Am* 1989; 27(1): 81–91.
2. *Mallik IH, Winsle MCl.* Vascular complication of pancreatitis. *JOP J Pancreas* 2004; 5(5): 328–37.
3. *Sparrow P, Asquith J, Chalmers N.* Ultrasonic-guided percutaneous injection of pancreatic pseudoaneurysm with thrombin. *Cardiovasc Intervent Radiol* 2003; 26(3): 312–5.
4. *Yamaguchi K, Futagawa S, Ochi M, Sakamoto I, Hayashi K.* Pancreatic pseudoaneurysm converted from pseudocyst: transcatheter embolization and serial CT assessment. *Radiat Med* 2000; 18(2): 147–50.
5. *Udd M, Leppaniemi AK, Bidel S, Keto P, Roth WD, Haapiainen RK.* Treatment of bleeding pseudoaneurysms in patients with chronic pancreatitis. *World J Surg* 2007; 31(3): 504–10.
6. *Piffaretti G, Tozzi M, Lomazzi C, Rivolta N, Riva F, Caronno R,* et al. Splenic artery aneurysms: postembolization syndrome and surgical complications. *Am J Surg* 2007; 193(2): 166–70.
7. *El Hamel A, Paré R, Adda G, Bouteloup PY, Hugnet C, Malafosse M.* Bleeding pseudocysts and pseudoaneurysms in chronic pancreatitis. *Br J Surg* 1991; 78(9): 1059–63.
8. *Hsu JT, Yeh CN, Hung CF, Chen HM, Hwang TL, Jan YY,* et al. Management and outcome of bleeding pseudoaneurysm associated with chronic pancreatitis. *BMC Gastroenterol* 2006; 6: 3.
9. *de Perrot M, Berney T, Bühler L, Delgado X, Mentha G, Morel P.* Management of bleeding pseudoaneurysms in patients with pancreatitis. *Br J Surg* 1999; 86(1): 29–32.
10. *Tessier DJ, Stone WM, Fowl RJ, Abbas MA, Andrews JC, Bower TC,* et al. Clinical features and management of splenic artery pseudoaneurysm: case series and cumulative review of literature. *J Vasc Surg* 2003; 38(5): 969–74.
11. *Sugg SL, Gerndt SJ, Hamilton BJ, Francis IR, Taberi PA, Rodriguez JL.* Pseudoaneurysms of the intraparenchymal splenic artery after blunt abdominal trauma: a complication of nonoperative therapy and its management. *J Trauma* 1995; 39(3): 593–5.
12. *Ammori BJ, Madan M, Alexander DJ.* Haemorrhagic complications of pancreatitis: presentation, diagnosis and management. *Ann R Coll Surg Engl* 1998; 80(5): 316–25.
13. *Lower WE, Farrell JI.* Aneurysm of the splenic artery: report of case and review of the literature. *Arch Surg* 1931; 23: 182–90.

14. Sandblom P. Gastrointestinal hemorrhage through the pancreatic duct. *Ann Surg* 1970; 171(1): 61–6.
15. Rignault D, Mine J, Moine D. Splenoportographic changes in chronic pancreatitis. *Surgery* 1968; 63(4): 571–5.
16. Carr JA, Cho JS, Shepard AD, Nypaver TJ, Reddy DJ. Visceral pseudoaneurysms due to pancreatic pseudocysts: rare but lethal complications of pancreatitis. *J Vasc Surg* 2000; 32(4): 722–30.
17. Geokas MC. The role of elastase in acute pancreatitis. II. Intrapancreatic elastolytic activity in trypsin-induced acute pancreatitis in dogs. *Arch Pathol* 1968; 86(2): 127–34.
18. Forsmark CE, Wilcox CM, Grendell JH. Endoscopy-negative upper gastrointestinal bleeding in a patient with chronic pancreatitis. *Gastroenterology* 1992; 102(1): 320–9.
19. Boudghène F, L'Herminé C, Bigot JM. Arterial complications of pancreatitis: diagnostic and therapeutic aspects in 104 cases. *J Vasc Interv Radiol* 1993; 4(4): 551–8.
20. Flati G, Andrén-Sandberg A, La Pinta M, Porowska B, Carboni M. Potentially fatal bleeding in acute pancreatitis: pathophysiology, prevention, and treatment. *Pancreas* 2003; 26(1): 8–14.
21. Agrawal GA, Johnson PT, Fishman EK. Splenic artery aneurysms and pseudoaneurysms: clinical distinctions and CT appearances. *AJR Am J Roentgenol* 2007; 188(4): 992–9.
22. Sankaran S, Walt AJ. The natural and unnatural history of pancreatic pseudocysts. *Br J Surg* 1975; 62(1): 37–44.
23. Kiviluoto T, Kivisaari L, Kivilaakso E, Lempinen M. Pseudocysts in chronic pancreatitis. Surgical results in 102 consecutive patients. *Arch Surg* 1989; 124(2): 240–3.
24. Lankisch PG. Diagnostic standards in chronic pancreatitis. Exocrine pancreatic function tests. *Z Gastroenterol Verh* 1991; 26: 58–61. (German)
25. Abbas MA, Stone WM, Fowl RJ, Glowiczki P, Oldenburg WA, Pairolero PC, et al. Splenic artery aneurysms: two decades experience at Mayo clinic. *Ann Vasc Surg* 2002; 16(4): 442–9.
26. Bittner R. Surgical management of pancreatic abscess. In: Berger H, Warsaw AL, Buchler M, editors. *The Pancreas*. Oxford, United Kingdom: Blackwell Science; 1998. p. 627–31.
27. Frey CF. Hemorrhagic pancreatitis. *Am J Surg* 1979; 137(5): 616–23.
28. Guillon R, Garcier JM, Abergel A, Mofid R, Garcia V, Chabid T, et al. Management of splenic artery aneurysms and false aneurysms with endovascular treatment in 12 patients. *Cardiovasc Intervent Radiol* 2003; 26(3): 256–60.
29. Bergert H, Hinterseher I, Kersting S, Leonhardt J, Bloomenthal A, Saeger HD. Management and outcome of hemorrhage due to arterial pseudoaneurysms in pancreatitis. *Surgery* 2005; 137(3): 323–8.
30. Gambiez LP, Ernst OJ, Merlier OA, Porte HL, Chambon JP, Quandalle PA. Arterial embolization for bleeding pseudocysts complicating chronic pancreatitis. *Arch Surg* 1997; 132(9): 1016–21.
31. Beattie GC, Hardman JG, Redhead D, Sirwardena AK. Evidence for a central role for selective mesenteric angiography in the management of the major vascular complications of pancreatitis. *Am J Surg* 2003; 185(2): 96–102.
32. Bresler L, Boissel P, Grosdidier J. Major hemorrhage from pseudocysts and pseudoaneurysms caused by chronic pancreatitis: surgical therapy. *World J Surg* 1991; 15(5): 649–52.
33. Evans GR, Yellin AE, Weaver FA, Stain SC. Sinistral (left-sided) portal hypertension. *Am Surg* 1990; 56(12): 758–63.
34. Sakorafas GH, Sarr MG, Farley DR, Farnell MB. The significance of sinistral portal hypertension complicating chronic pancreatitis. *Am J Surg* 2000; 179(2): 129–33.
35. Bernades P, Baetz A, Lévy P, Belghiti J, Menu Y, Fékété F. Splenic and portal venous obstruction in chronic pancreatitis. A prospective longitudinal study of a medical-surgical series of 266 patients. *Dig Dis Sci* 1992; 37(3): 340–6.
36. McErlean A, Looby S, Lee MJ. Percutaneous ultrasound-guided thrombin injection as first-line treatment of pancreatic pseudoaneurysm. *Cardiovasc Intervent Radiol* 2007; 30(3): 526–8.
37. Bergert H, Dobrowolski F, Caffier S, Bloomenthal A, Hinterseher I, Saeger HD. Prevalence and treatment of bleeding complications in chronic pancreatitis. *Langenbecks Arch Surg* 2004; 389(6): 504–10.
38. Palanivelu C, Senthilkumar K, Madhankumar MV, Rajan PS, Shetty AR, Jani K, et al. Management of pancreatic pseudocyst in the era of laparoscopic surgery—experience from a tertiary centre. *Surg Endosc* 2007; 21(12): 2262–7.

Received on July 21, 2009.

Accepted on December 25, 2009.