



Case Report

Korean J Pediatr 2013;56(4):182-185

<http://dx.doi.org/10.3345/kjp.2013.56.4.182>

eISSN 1738-1061 • pISSN 2092-7258

An unusual cause of duodenal perforation due to a lollipop stick

Mi Jin Kim, MD, PhD¹, Jeong Meen Seo, MD, PhD³, Yoon Lee, MD², Yoo Min Lee, MD², Yon Ho Choe, MD, PhD²

Department of Pediatrics¹, Ilsan Paik Hospital, Inje University College of Medicine, Goyang

Departments of²Pediatrics and³Surgery, Samsung Medical Center, Sungkyunkwan University School of Medicine, Seoul, Korea

Children have a natural tendency to explore objects with their mouths; this can result in the swallowing of foreign objects. Most ingested foreign bodies pass uneventfully through the gastrointestinal tract. However, some foreign bodies cause obstruction or perforation of the gastrointestinal tract, requiring surgical intervention. Perforation of the gastrointestinal tract may be associated with considerable morbidity and mortality. The most common sites of intestinal foreign body perforation are the ileocecal and rectosigmoid regions. Foreign body perforation of the duodenum is relatively uncommon. We report the first Korean case of duodenal perforation by an ingested 8-cm lollipop stick. Lollipops are popular with the children and fairly accessible to them, as most parents are not aware of their potential harm. Pediatric clinicians should be aware of the risks associated with lollipop stick ingestion. Our report also describes the feasibility and safety of laparoscopic diagnosis and management of pediatric patients with peritonitis induced by the ingestion of foreign bodies.

Corresponding author: Yon Ho Choe, MD, PhD
Department of Pediatrics, Samsung Medical Center,
Sungkyunkwan University School of Medicine, 81
Irwon-ro, Gangnam-gu, Seoul 135-710, Korea
Tel: +82-2-3410-3539
Fax: +82-2-3410-0043
E-mail: i101016@skku.edu

Received: 5 March 2012

Revised: 11 June 2012

Accepted: 12 July 2012

Key words: Lollipop stick, Foreign bodies, Duodenal perforation, Laparoscopy

Introduction

Children have a natural tendency to explore objects with their mouths, which can result in foreign body ingestion. Many cases of ingestion of foreign bodies are noted in children between 6 months and 3 years of age¹. Most of the foreign objects that are passed down to the stomach or to more distal sites are spontaneously excreted in feces without treatment. However, foreign bodies sometimes cause obstruction or perforation of the gastrointestinal tract, necessitating surgical intervention². Here, we report the first Korean case of duodenal perforation resulting from an ingested lollipop stick.

Case report

A six-year-old girl with no previous history of medical problems or surgery was admitted to the emergency department of our hospital with a two-day history of diffuse abdominal pain, nausea and vomiting. Physical examination of the febrile patient (38.8°C) was unremarkable except for moderate right-upper quadrant abdominal tenderness. Laboratory findings revealed moderately increased white blood cell count (20,710/ μ L; reference range, 4,000 to 11,000/ μ L) and C-reactive protein level (6.95 mg/dL; reference range, 0 to 0.3 mg/dL). Hemoglobin, platelet count, total bilirubin, amino-transferases, amylase, lipase, creatinine, and urinalysis were within reference ranges. Chest and plain abdominal X-ray examinations were unremarkable (Fig. 1). Abdominal

Copyright © 2013 by The Korean Pediatric Society

This is an open-access article distributed under the terms of the Creative Commons Attribution Non-Commercial License (<http://creativecommons.org/licenses/by-nc/3.0/>) which permits unrestricted non-commercial use, distribution, and reproduction in any medium, provided the original work is properly cited.

ultrasonography showed a tubular echogenic structure in the second portion of the duodenum with the possibility of duodenal penetration and adjacent omental fatty infiltration

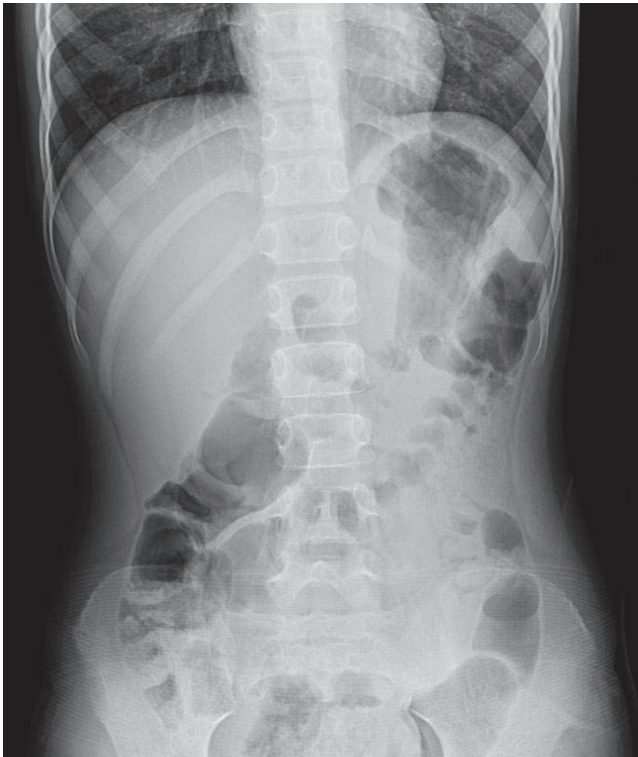


Fig. 1. Unremarkable plain abdominal radiograph.

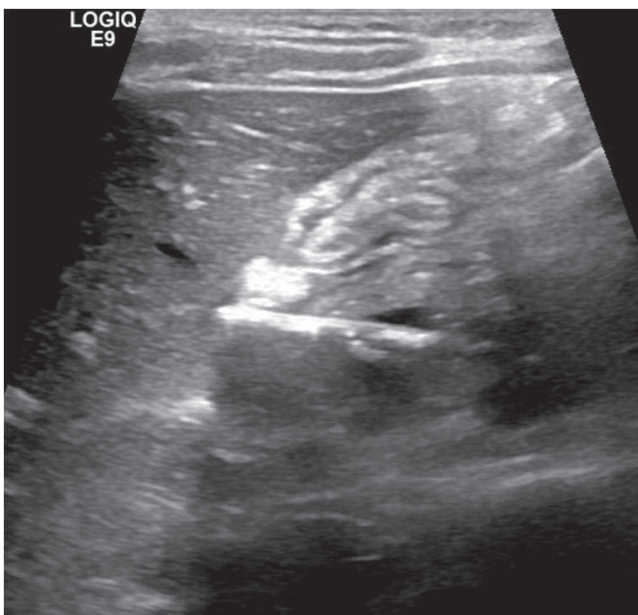


Fig. 2. Abdominal ultrasonography demonstrated a tubular echogenic structure in the second portion of the duodenum, with a possibility of duodenal penetration.

associated with right-side peritonitis (Fig. 2). The computed tomography scan also identified a linear foreign body of about 10 cm with internal air contents in the duodenum (Fig. 3). The patient denied foreign body ingestion.

Considering the patient's stable general condition, we chose to perform a laparoscopic examination to assess the status of the perforation site and surrounding tissues. Using an umbilical 5-mm port, two 3-mm ports at the upper midline, and a fourth 5-mm port in the subxiphoid area, we found a lollipop stick perforating the second portion of the duodenum and evidence of peritonitis. The stick was easily discernible and extracted from the duodenal lumen through the perforation (Fig. 4). The biliary tree was undamaged. The perforation was closed in a single layer using 4/0 absorbable monofilament (Monosyn) and later reinforced with an omental patch. The peritoneal cavity was lavaged with saline. We performed intraoperative upper gastrointestinal endoscopy with a pneumatic test and found no evidence of leakage. We inserted a closed drain in the right upper quadrant of the subdiaphragmatic area.

The postoperative course was uncomplicated. The patient resumed oral intake on the seventh postoperative day and was discharged from the hospital ten days after surgery.

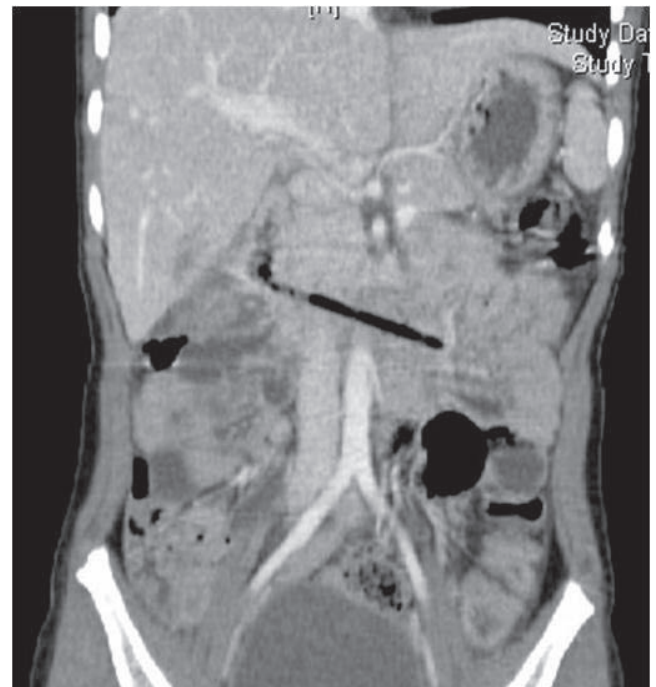

Fig. 3. Abdominal computed tomography revealed an approximately 10-cm linear foreign body (FB) with internal air contents in the duodenum and disruption of the duodenal wall. A linear low-attenuated lesion in the inferior segment of the liver was an injury associated with the FB.

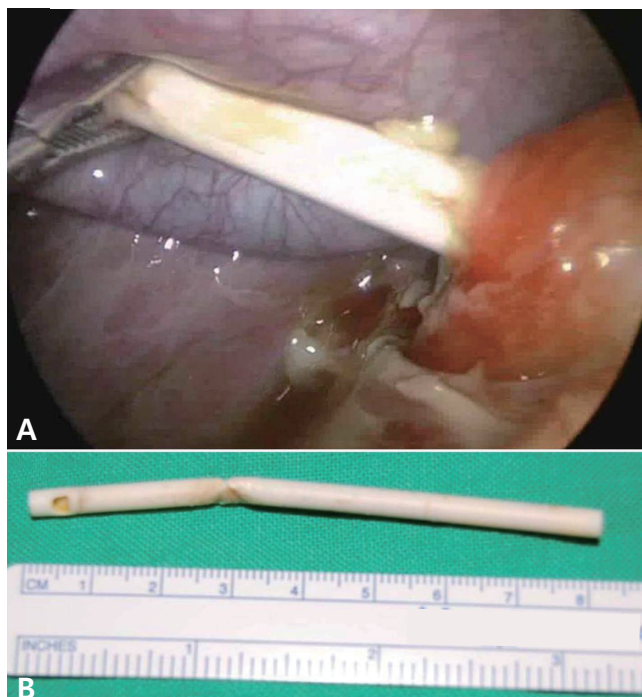


Fig. 4. Laparoscopic views of the duodenal perforation and the extracted lollipop stick. A lollipop stick was located at the second portion of the duodenum and was removed with a laparoscopic grasper (A). The 8-cm long lollipop stick was removed (B).

Discussion

Foreign object ingestion is a common clinical problem in young children. Commonly ingested objects are coins, toy parts, jewelry, button-type batteries, needles and pins, as well as fish and chicken bones³. The majority of ingested foreign bodies pass uneventfully through the gastrointestinal tract⁴. However, in some patients, the ingested foreign body causes impaction, perforation, or obstruction. Perforation occurs in less than 1% of ingestion of a foreign body³. Perforation of the gastrointestinal tract may be associated with a considerably high mortality and morbidity. Gastrointestinal tract perforation may cause peritonitis, abscess formation, inflammatory mass formation, obstruction, fistulae, and hemorrhage⁵. Most deaths in patients with foreign body perforation of the gastrointestinal tract are due to fulminant sepsis⁶. Therefore, efforts should be made to remove the ingested foreign bodies if they cannot pass through the gastrointestinal tract spontaneously.

The most common sites of intestinal perforation by a foreign body are the ileocecal and rectosigmoid regions⁷. Duodenal perforation because of ingested foreign objects is relatively uncommon⁸. Clinical presentations vary, depending on the site of perforation and the extent and duration of peritonitis⁴. As most young pediatric patients usually do not remember the foreign body ingestion, the final diagnosis is frequently delayed.

Non-radio-opaque foreign bodies are especially difficult to detect on plain radiographs of the abdomen. Computed tomography scans and ultrasonography may help clinicians in this challenging situation; however, in most patients, the diagnosis is not confirmed until surgical intervention.

In this case, the lollipop stick was entrapped in the duodenal sweep and resulted in perforation of the duodenum. The retroperitoneal, relatively immobile, and rigid nature of the duodenum as well as its deep transverse rugae and sharp angulations make it a common site for the entrapment of long and sharp-ended objects⁹. Objects longer than 6 to 10 cm have difficulty in passing the duodenal sweep¹⁰. Therefore, in cases of unsuccessful endoscopic removal of gastric foreign bodies that are longer than 6.0 cm, surgical removal should be considered. Compared with traditional surgical treatments, laparoscopic removal of a foreign object is less invasive and is associated with minimal postoperative pain, a faster return to normal activities, and better cosmetic outcome⁶.

This is the first Korean case report of duodenal perforation resulting from an ingested lollipop stick. Lollipops are popular among the pediatric population, and they are accessible to children because most parents are not aware of their potential risks. Pediatric clinicians should be aware of the risk associated with lollipop stick ingestion. Our report also suggests the feasibility and safety of laparoscopic diagnosis and treatment for pediatric patients with peritonitis induced by the ingestion of foreign bodies.

Conflict of interest

No potential conflict of interest relevant to this article was reported.

References

- Hernandez Anselmi E, Gutierrez San Roman C, Barrios Fontoba JE, Ayuso González L, Valdes Dieguez E, Lluna Gonzalez J, et al. Intestinal perforation caused by magnetic toys. *J Pediatr Surg* 2007;42:E13-6.
- Hartin CW Jr, Lau ST, Caty MG. Metallic foreign body in the appendix of 3-year-old boy. *J Pediatr Surg* 2008;43:2106-8.
- Velitchkov NG, Grigorov GI, Losanoff JE, Kjossev KT. Ingested foreign bodies of the gastrointestinal tract: retrospective analysis of 542 cases. *World J Surg* 1996;20:1001-5.
- Losanoff JE, Kjossev KT. Ingested foreign bodies of the gastrointestinal tract. *J Emerg Med* 1999;17:525-6.
- Selivanov V, Sheldon GF, Cello JP, Crass RA. Management of foreign body ingestion. *Ann Surg* 1984;199:187-91.
- Omejc M. Laparoscopic removal of an ingested pin migrating into the liver. *Surg Endosc* 2002;16:537.
- Pinero Madrona A, Fernandez Hernandez JA, Carrasco Prats M,

- Riquelme Riquelme J, Parrila Paricio P. Intestinal perforation by foreign bodies. *Eur J Surg* 2000;166:307-9.
8. Goh BK, Chow PK, Quah HM, Ong HS, Eu KW, Ooi LL, et al. Perforation of the gastrointestinal tract secondary to ingestion of foreign bodies. *World J Surg* 2006;30:372-7.
 9. Chao HH, Chao TC. Perforation of the duodenum by an ingested toothbrush. *World J Gastroenterol* 2008;14:4410-2.
 10. Eisen GM, Baron TH, Dominitz JA, Faigel DO, Goldstein JL, Johanson JF, et al. Guideline for the management of ingested foreign bodies. *Gastrointest Endosc* 2002;55:802-6.