



Possibilities of reconstruction and implant-prosthetic rehabilitation following mandible resection

Mogućnosti rekonstrukcije i implantološko-protetičke rehabilitacije nakon resekcije mandibule

Vitomir S. Konstantinović*, Vladimir S. Todorović*, Vojkan M. Lazić†

*Clinic of Maxillofacial Surgery, †Clinic of Dental Prosthetics, Faculty of Dental Medicine, University of Belgrade, Belgrade, Serbia

Abstract

Introduction. Mandible reconstruction is still very challenging for surgeons. Mandible defects could be the consequence of ablative surgery for malignancies, huge jaw cysts, infection and trauma. Segmental resection of the mandible may compromise orofacial function and often lead to patients psychological disorders. Despite very frequent use of microvascular flaps, autogenous bone grafts are still very reliable technique for mandible reconstruction. Comprehensive therapy means not only mandible reconstruction, but prosthodontic rehabilitation supported by dental implants, which can significantly improve patients quality of life. The aim of this paper was to evaluate possible techniques of mandible reconstruction and to present a patient who had been submitted to mandible resection and reconstruction with autogenous iliac bone graft and prosthodontic rehabilitation with fixed denture anchored by disc-shaped implants in early loading protocol. **Case report.** Mandible reconstruction was performed simultaneously with resection. Autogenous iliac bone graft was taken, reshaped and placed in two parts, to the required optimal contour of the mandible. After graft consolidation, decision was made for prosthodontics rehabilitation with fixed dentures supported by implants. In addition to the standard preoperative procedures, planning was done based on a biomodel gained by rapid prototyping after CT scan. It offered a real 3D planning to obtain a proper shape, dimension and the position of implants. **Conclusion.** If bone dimensions of a reconstructed mandible are insufficient, like in the presented case, the use of basal osseointegrated implants may be a method of choice. Avoiding bone augmentation procedures, as well as early loading protocol for this type of implants, shorten the total rehabilitation time, which is very convenient for patients. Fixed denture supported by dental implants is the best solution for comprehensive rehabilitation after mandible resection.

Key words:

oral surgical procedures; mandibular injuries; reconstructive surgical procedures; dental prosthesis, implant-supported; rehabilitation, treatment outcome

Apstrakt

Uvod. Rekonstrukcija mandibule još uvek predstavlja izazov za hirurga. Defekti mandibule mogu biti posledica radikalnog hirurškog tretmana malignih tumora, velikih viličnih cista, infekcija i povreda. Nedostatak dela vilične kosti kompromituje sve orofacijalne funkcije, a česti su i psihološki poremećaji. Pored sve učestalije primene mikrovaskularnih reznjeva, slobodni koštani graftovi su još uvek veoma pouzdan metod rekonstrukcije mandibule. Sveobuhvatna terapija pored rekonstrukcije mandibule podrazumeva i implantološko-protetičku rehabilitaciju, kojom se znatno poboljšava kvalitet života bolesnika. Cilj ovog rada bio je da se kroz pregled literature ocene metode rekonstrukcije mandibule i da se prikaže bolesnica kod koje je nakon segmentalne resekcije mandibule izvršena rehabilitacija fiksnom zubnom nadoknadom nošenom implantatima oblika diska. **Prikaz bolesnika.** U istom aktu sa resekcijom izvršena je i rekonstrukcija slobodnim koštanim ilijačnim graftom, koji je preoblikovan i postavljen iz dva dela, kako bi se uspostavio optimalan kontinuitet i forma mandibule. Po konsolidaciji grafta, postavljena je indikacija za izradu fiksne zubne nadoknade nošene implantatima. Pored standardnih preoperativnih procedura, izvršeno je realno trodimenzionalno planiranje na biomodelu dobijenim softverskom analizom CT podataka. Na taj način određen je oblik, veličina i najpovoljniji položaj implantata. **Zaključak.** Ukoliko su koštane dimenzije rekonstruisane mandibule nedovoljne, kao kod prikazane bolesnice, primena bazalnih oseointegriranih implantata oblika diska može biti metoda izbora. Njihovom upotrebom izbegava se dodatna nadoknada kosti što uz rano opterećenje predstavlja pogodnost za bolesnike, jer se znatno skraćuje vreme rehabilitacije. Izrada fiksne zubne nadoknade nošene implantatima je najbolji način definitivne rehabilitacije bolesnika sa rekonstruisanom mandibulom.

Ključne reči:

hirurgija, oralna, procedure; mandibula, povrede; hirurgija, rekonstruktivna, procedure; zubna proteza, implantatom podržana; rehabilitacija; lečenje, ishod.

Introduction

Mandible reconstruction has been a challenge for surgeons for more than a century. Mandible defects resulting in face deformity of various stages are mostly the consequence for ablative surgery for malignancies, huge jaw cysts, infections (osteomyelitis) and trauma, that may compromise orofacial functions and cause subsequent psychological disorders.

Adequate anatomic reconstructing assumes the outcome which should provide satisfactory mandible dimensions, form and shape. Also, muscle attachments which enable normal functioning should be established again. It is necessary to consider a definitive prosthetic rehabilitation and to think about the space for the placement of oral implants. In spite of a significant progress achieved, particularly in the last 40 years, none of the existing reconstruction techniques is completely satisfactory¹.

According to the algorithm developed by Takushima et al.², mandible defects are classified as either „lateral“ or „anterior“. Soft-tissue defects are classified into three categories: „none“ (no or minimal defect on both sides of facial skin and oral mucosa); „skin or mucosal“ (only skin or mucosal defect); and „through-and-through“ (defect is through-and-through from the oral mucosa to the facial skin). To select a suitable reconstruction method, bone-defect should be considered first, followed by the soft tissue condition. In accordance with this, autologous bone grafts, alloplastic materials and tissue engineered matrix origin cell grafts, are utilized for the mandible reconstruction¹. Most frequently used are autologous bone grafts which can be applied in three principally different ways, such as: free bone grafts, pedicled bone grafts and microvascular bone grafts (flaps)³.

The introduction of microvascular surgery has led to a significant progress in mandible defects treatment¹. Microvascular bone grafts can be „osteomuscular“ which, apart from the bone, contain the periosteum and the attached muscle, or „osteomusculocutaneous“, which also contain the skin on their surface. These, so-called composite grafts can be taken from the different donor regions: fibula, iliac and scapula. They are indicated for the reconstruction of large bone defects, defects in recipient sites of poor quality (scarred tissue, irradiated tissue, etc.), and when a simultaneous bone and soft tissue reconstruction is preferred³. According to the literature, the most frequently applied is fibula flap^{1,4}. The basic advantage of microvascular composite flaps is the possibility of one-stage treatment of both bone and soft tissue defects by using a single donor site, with over 90% efficacy, even in irradiated patients^{1,5,6}. Foster et al.⁵ state that the success of implants osseointegration in microvascular bone flaps was recorded in 99% cases. Compared with free bone grafts, there is a less risk to develop postoperative complications such as resorption or infection. However, complications of various degrees can be developed in the donor region, such as pain, difficulties in walking (limping), pathological fractures, herniation, etc.⁷. On the other hand, duration of surgery may impose a serious problem with patients with a compromised

general condition¹. It should be also mentioned that such procedures require qualified staff and well-equipped institutions, yet not always possible to provide.

Initial efforts to use free bone grafts date back to the beginning of the 19th century. Owing to the experience gained during the First and Second World War, this technique became widely accepted as standard in treatment of mandible defects. Until 1970s, fixation of these grafts was done with a wire, taking a longer period of intermaxillary fixation with the level of success ranging from 20% to 90%. It is known that the success of free bone grafts depends on the fixation and revascularization of the recipient site. Revascularization is very important for the process of resorption and deposition of a new bone, which is referred to as creeping substitution¹. Also, it is known that even micro-movements, if fixation is not enough strong, could jeopardize the viability of a graft or lead to graft failure. There is surprisingly little literature about the success rate of free bone grafts fixed with plates and screws as compared to wire fixation. However, fixation is nowadays routinely done with reconstructive plates and screws. The usual donor sites are: the iliac crest, rib or tibia. With regard to the bone quantity and quality, the best characteristics are provided by the iliac crest. The anterior iliac crest is the donor region of choice in most of cases. Iliac grafts could be taken as „cancellous“, „thin cortical“, „corticocancellous“, and „bicorticocancellous“ (full thickness) bone grafts³. The technique of raising free iliac bone grafts is simple one, their shape matches mandible contours and dimensions and they provide enough amount of bone that is very significant for implant placement. Generally, patients experience a postoperative course without difficulties, and donor site complications are rare (12%).

A definitive functional reconstruction implies prosthetic rehabilitation, which may be done with mobile restorations which are retained by means of the existing teeth. However, apart from the limited function and discomfort of patient, mobile prosthesis also causes an additional bone resorption. An ideal reconstruction is achieved with fixed dentures anchored by dental implants. If bone dimensions are not sufficient, bone augmentation or adequate implantation systems can be used.

Disk-shaped dental implants placed in jaw bones by lateral approach were described even in 1972. Significantly improved in the sense of their design and surface, they have been recently applied as the so-called basal osseointegrated implants⁸. Owing to their design which enables bicortical osseointegration in the basal, the most resorption-resistant part of the jaw bone, they can be also placed even when vertical and horizontal dimensions of the residual alveolar ridge are insufficient, that is a huge advantage over other implantation systems. Moreover, the possibility of early loading, conditioned by the achievement of a balanced occlusion, provides a patient with great comfort.

The aim of this paper was to evaluate possible techniques of mandible reconstruction and the contemporary approach to comprehensive functional rehabilitation of patient after a segmental mandible resection.

A female patient with mandible resection followed by immediate reconstruction with an autogenous iliac bone graft was presented. After a complete graft integration, in the second phase, the basal osseointegrated implants were inserted and early loaded with the fixed denture.

Case report

A 55-years-old female patient was admitted to the Clinic of Maxillofacial Surgery, Faculty of Dental Medicine, University of Belgrade, with pathological lesion in mandible which was identified during the routine radiographic examination. The patient was not complaining to any discomfort which might indicate the presence of lesion. A radiological finding was unspecific, showing confined multilocular bone radiolucency of the corpus, angulus and ramus of the mandible at the right side (Figure 1). After biopsy and histopathological finding the diagnosis of odontogenic keratocyst was made. After preoperative planning, a segmental mandible resection from

the canine to the subcondylar region including a coronoid process was performed. A total length of the resected part was about 8 cm. Simultaneously, a primary reconstruction with a free bone graft from the iliac bone was done. Due to the size of defect, the graft was reshaped and placed in two parts in order to achieve the most optimal continuity and mandible form. Titanium reconstructive plate and screws (Synthes GmbH, Switzerland) were used for graft fixation (Figure 2).

A postoperative course was uneventful. A control orthopantomogram, which was made immediately after the operation, showed a good position of the graft. Three months after the operation, a complete graft integration with a certain degree of resorption was radiologically confirmed.

On the basis of the control radiography after 10 months, a definite resorption of graft was estimated to be about 20%.

A final decision about prosthetic rehabilitation with fixed dentures supported by implants in the early loading protocol was made in agreement with the patient after having been informed about all the eventual possibilities.

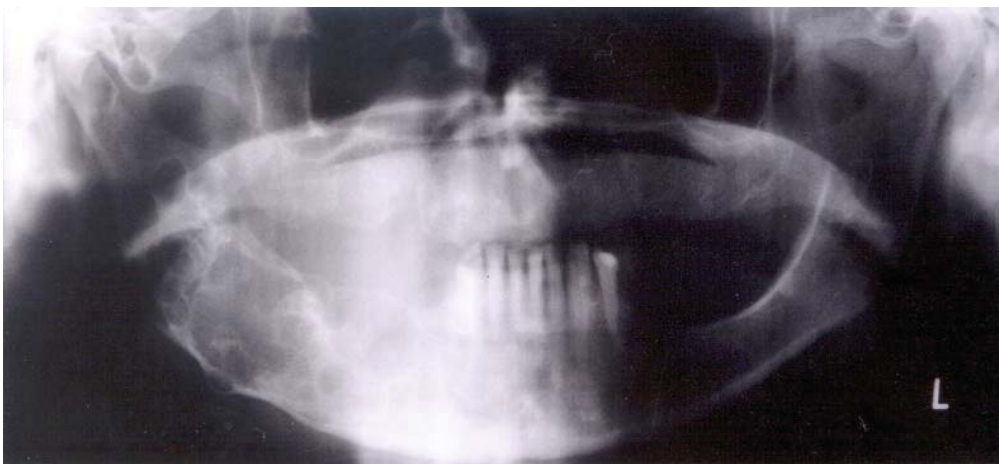


Fig. 1 – Orthopantomograph with odontogenic keratocyst

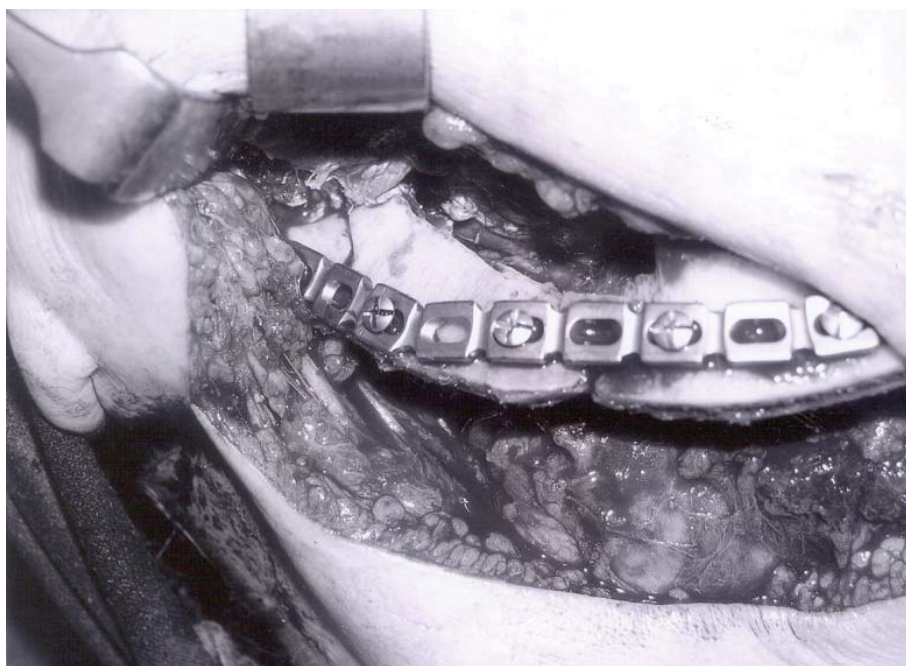


Fig. 2 – Fixation of the graft with reconstructive plate and screws

Based on the orthopantomogram, vertical and horizontal bone dimensions were insufficient for placement of conventional screw implants. To have an insight into the exact situation, the procedure continued with the 3D planning on the basis of CT data using the software (Mimics, Materialise, Belgium). This software allowed manufacturing of a mandible biomodel by means of 3D copying (rapid prototyping). In the mean time, the impressions of both jaws were taken and plaster study models were obtained. The biomodel served to carefully analyse the available bone, in order to determine the exact shape, size and the position of implants (Figure 3). In addition, a surgical stent which helped in inserting implants in the pre-determined specific positions was made.

The implantation procedure was performed under general anesthesia. Intraoperatively, following rising mucoperiosteal flap, the stability of bone graft was confirmed. After surgical stent adaptation, implantation was done according to the protocol for disk-shaped implants (lateral insertion). In the residual alveolar ridge in the molar region at the left side, an implant was placed, and in the graft at the right side, two disk-shaped implants were inserted (Diskos-ID Brand, Dr. Ihde Dental AG, Switzerland) (Figure 4). Six days after the operation, the impressions were taken, and the implants were loaded with a temporary composite bridge on the day 10.

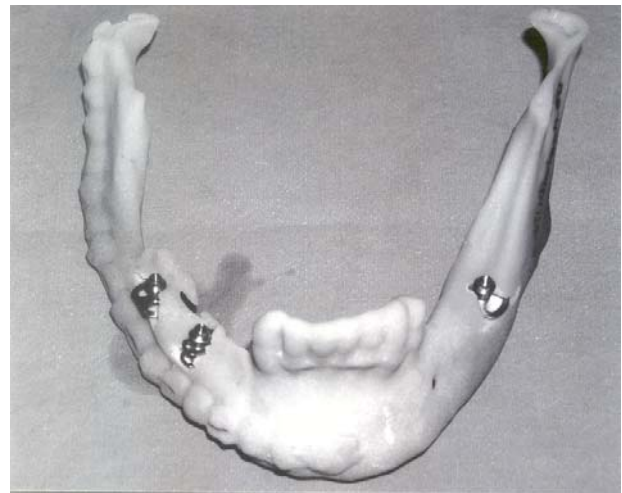


Fig. 3 – Biomodel with implants

The control CT and orthopantomographs showed an excellent position of implants. Six months later, a complete integration of implants was determined clinically (radiologically), and a definite metalceramic circular bridge was produced. There were no signs of marginal bone loss around the loaded implants after 2 years, which was confirmed by control orthopantomograph (Figure 5).

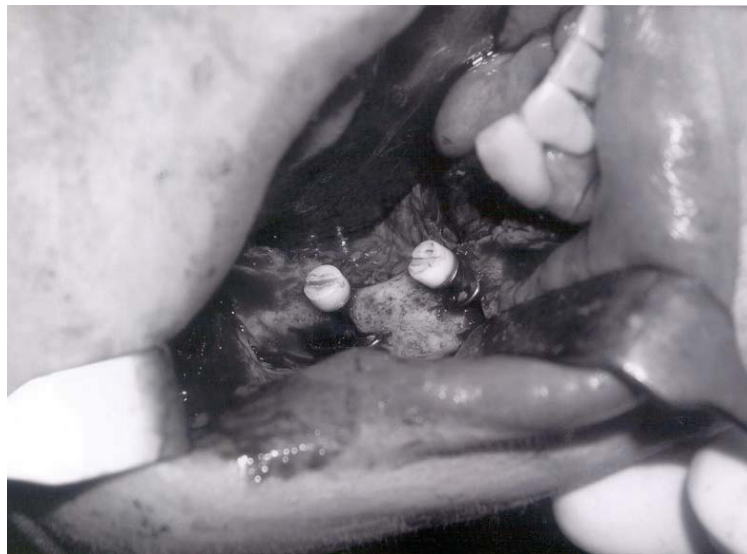

Fig. 4 – Disk implants inserted in reconstructed mandible

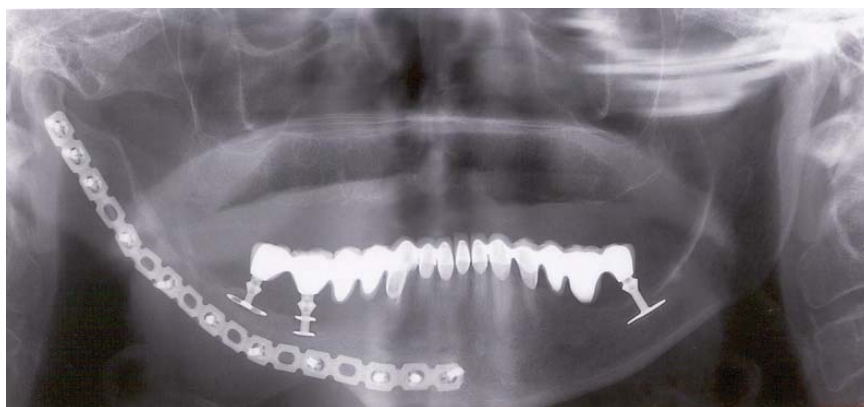


Fig. 5 – Orthopantomograph two years after implantation

Discussion

There are no many papers on mandible reconstruction with free bone grafts and oral implants in the literature. However, there are several hesitations concerning this topic which need further consideration.

First of all, considering the currently available techniques for mandible reconstruction, the question arises about which cases are suitable for the reconstruction with free bone grafts as a method of choice. There are several crucial criteria for a definite decision making. As concerns the size of the defect, Goh et al.¹ believe that free bone grafts are still a good option for defects smaller than 5 cm, if the surrounding soft tissues are in good condition. Hotz⁹ gives priority to the delayed mandible reconstruction with a free iliac graft for defects smaller than 8 cm. Foster et al.⁵ in their comparative study concluded that the use of avascular bone grafts is limited to smaller bone defects (< 5–6 cm), in patients who do not undergo irradiation therapy and/or do not have a compromised general condition. Pogrel et al.¹⁰ share similar opinion indicating the dimension of 6 cm as an upper limit for use of avascular grafts. Contrary to them, Chiapasco et al.¹¹ in their retrospective study showed that the limiting factor for the use of avascular grafts is not the size of defect but surely the insufficient quality and quantity of surrounding soft tissues, in the sense of compromised revascularization. The mentioned study presents successful reconstructions also for defects which spread from the symphyseal part to the condylar region of the mandible.

The majority of authors agree that the iliac crest is the best donor site, because of easy approach and possibility for taking a large amount of bone^{3,9,10,12}.

One of the dilemmas is whether the reconstruction should be done simultaneously with mandible resection or subsequently. Hotz⁹ indicates an important problem of simultaneous reconstruction in cases with malignancies, because it is not possible to perform a histopathological verification of the tumour free margins. Also, compared with the postponed reconstruction, the duration of intervention is significantly prolonged and therefore the risk of postoperative complications is increased.

Since the patient presented in this paper was involved with a benign lesion (the patient was not irradiated), the size of the bone defect was estimated to be about 8 cm, and soft tissues were of a satisfactory quality, the decision was made for a primary reconstruction with a free bone iliac graft. According to the exact dimensions of the resected part of the mandible, the graft was reshaped and fixed in two parts in order to adequately reconstruct the mandible contours.

A contemporary approach to a patient definitive rehabilitation after mandible resection does not imply an anatomic reconstruction only, but also a prosthetic rehabilitation. In the past, patients were mostly rehabilitated with mobile dentures of limited functional and aesthetic values. The introduction of endosseal implants provided rehabilitation with fixed dentures showing to be more comfortable, and significantly improving both function and aesthetic.

There are numerous studies describing successful application of conventional screw implants in reconstructed mandibles^{6,9,12,13}.

When considering the right timing for implants placement, there are two reasons in favour of the delayed implantation. The first is in the fact that the successful osseointegration depends on osteoblasts capable for osteogenesis, and bone grafts are, so to say “a dead bone” as long as the process of the so-called “acceptance of the grafts” does not start. Another reason is that the simultaneous implantation is proportionally more demanding and rarely meets prosthetic requirements. Lekholm et al.¹⁴ have concluded that implantation success is higher with the delayed approach. Lundgren et al.¹³ in their research revealed that the delayed procedure not only results in bigger amount of bone on the implant's surface but also stimulates further remodelling and formation of a new bone. Foster et al.⁵ mentioned that it is necessary to wait for 5 to 6 months after reconstruction, so that the implantation procedure may be successful. Considering the size of the graft and the time necessary for remodelling and formation of osteogenetic potential in the presented case, the decision was made to place the implants subsequently, at least after 6 months.

The basic prerequisite of successful implantation procedure is a sufficient quantity of bone. When free bone grafts are concerned, the expected resorption is 25% in relation to the initial graft volume¹⁵. One study tested the average vertical resorption of the graft and the value obtained was 3.53 cm¹⁴. Stošić¹⁶ indicates an average resorption of graft to be 15%–30%. Also, it is important to know whether the patient underwent a postoperative irradiation therapy¹⁷.

A problem might occur with the lack of bone for placement of screw implants. If so, it is possible to apply various augmentation procedures or to use particular implant systems^{18,19}. The use of basal osseointegrated (disk) implants in immediate or early loading protocols is a useful solution if a bone dimensions are insufficient for placing conventional screw type implants. By means of that, total rehabilitation time could be significantly shortened, which is very convenient to patients.

It is very important to point out that the multidisciplinary approach and good planning together with the use of adequate measuring is of crucial importance for an overall favourable outcome²⁰. A real 3D determination of future implant positions on a biomodel obtained on the basis of CT data appears very useful if a limiting anatomic factor is present. Also, it was possible for the patient to become familiar with the planned procedure.

Conclusion

It is the fact that the introduction of microvascular flaps has reduced indications for the use of free bone grafts. However, in favourable condition of soft tissues of the accepting region, free bone grafts are still very reliable method for mandible reconstruction. The best way to achieve definitive patient rehabilitation with a reconstructed mandible is to make a fixed denture supported by implants, because it is

very comfortable for a patient both in the functional and aesthetic sense.

In case of insufficient bone dimensions of the reconstructed mandible, the use of disk implants in immediate or early loading protocols is an useful optional method of rehabilitation.

Acknowledgement

A part of this research was financed with the Grant No 175075 of the Ministry of Education, Science and Technological Development of the Republic of Serbia.

R E F E R E N C E S

1. *Goh BT, Lee S, Tideman H, Stoeltinga PJ.* Mandibular reconstruction in adults: a review. *Int J Oral Maxillofac Surg* 2008; 37(7): 597–605.
2. *Takushima A, Harii K, Asato H, Momosawa A, Okazaki M, Nakatsuka T.* Choice of osseous and osteocutaneous flaps for mandibular reconstruction. *Int J Clin Oncol* 2005; 10(4): 234–42.
3. *Ehrenfeld M, Hagenmaier C.* Autogenous Bone Grafts in Maxillofacial Reconstruction. In: *Greenberg AM, Prain J*, editors. *Craniomaxillofacial Reconstructive and Corrective Bone Surgery: Principles of Internal Fixation Using the AO/ASIF Technique.* New York: Springer; 2002. p. 295–309.
4. *Wedder V, Farshad M, Sen M, Koehler C, Hanschin A, Graetz K, et al.* Retrospective analysis and clinical evaluation of mandible reconstruction with a free fibula flap. *Eur J Plast Surg* 2007; 29(6): 285–91.
5. *Foster RD, Anthony JP, Sharma A, Pogrel MA.* Vascularized bone flaps versus nonvascularized bone grafts for mandibular reconstruction: an outcome analysis of primary bony union and endosseous implant success. *Head Neck* 1999; 21(1): 66–71.
6. *Hidalgo DA, Pusic AL.* Free-flap mandibular reconstruction: a 10-year follow-up study. *Plast Reconstr Surg* 2002; 110(2): 438–49; discussion 450–1.
7. *Ghassemi A, Ghassemi M, Riediger D, Hilgers RD, Gerresen M.* Comparison of donor-site engraftment after harvesting vascularized and nonvascularized iliac bone grafts. *J Oral Maxillofac Surg* 2009; 67(8): 1589–94.
8. *Ibde S.* Principles of BOI, Clinical Scientific, and Practical Guidelines to 4-D Dental Implantology. Berlin, Heidelberg, New York: Springer-Verlag; 2005.
9. *Hotz G.* Reconstruction of mandibular discontinuity defects with delayed nonvascularized free iliac crest bone grafts and endosseous implants: a clinical report. *J Prosthet Dent* 1996; 76(4): 350–5.
10. *Pogrel MA, Podlesh S, Anthony JP, Alexander J.* A comparison of vascularized and nonvascularized bone grafts for reconstruction of mandibular continuity defects. *J Oral Maxillofac Surg* 1997; 55(11): 1200–6.
11. *Chiapasco M, Colletti G, Romeo E, Zaniboni M, Brusati R.* Long-term results of mandibular reconstruction with autogenous bone grafts and oral implants after tumor resection. *Clin Oral Implants Res* 2008; 19(10): 1074–80.
12. *Chiapasco M, Abati S, Ramundo G, Rossi A, Romeo E, Vogel G.* Behavior of implants in bone grafts or free flaps after tumor resection. *Clin Oral Implants Res* 2000; 11(1): 66–75.
13. *Lundgren S, Rasmussen L, Sjöström M, Sennerby L.* Simultaneous or delayed placement of titanium implants in free autogenous iliac bone grafts. Histological analysis of the bone graft-titanium interface in 10 consecutive patients. *Int J Oral Maxillofac Surg* 1999; 28(1): 31–7.
14. *Lekholm U, Wannfors K, Isaksson S, Adielsson B.* Oral implants in combination with bone grafts. A 3-year retrospective multicenter study using the Brånemark implant system. *Int J Oral Maxillofac Surg* 1999; 28(3): 181–7.
15. *Stoll P, Prein J, Bähr W, Wächter R.* Considerations in the fixation of bone grafts for the reconstruction of mandibular continuity defects. In: *Greenberg AM, Prain J*, editors. *Craniomaxillofacial Reconstructive and Corrective Bone Surgery: Principles of Internal Fixation Using the AO/ASIF Technique.* New York: Springer; 2002. p. 317–26.
16. *Stošić S.* Mandibular reconstruction. Belgrade: Rubikon; 2005. (Serbian)
17. *Ibde S, Kopp S, Gundlach K, Konstantinović VS.* Effects of radiation therapy on craniofacial and dental implants: a review of the literature. *Oral Surg Oral Med Oral Pathol Oral Radiol Endod* 2009; 107(1): 56–65.
18. *Konstantinović V.* Aspekte der implantologischen Versorgung mit BOI im Bereich des Sinus maxillaris. *ZMK* 2003; 19: 568–75.
19. *Konstantinović VS, Lazić VM, Stefan I.* Nasal epithesis retained by basal (disk) implants. *J Craniofac Surg* 2010; 21(1): 33–6.
20. *Arsić S, Perić P, Stojković M, Ilić D, Stojanović M, Ajduković Z, Vučić S.* Comparative analysis of linear morphometric parameters of the humane mandibula obtained by direct and indirect measurement. *Vojnosanit Pregl*; 2010; 67(10): 839–46. (Serbian)

Received on June 13, 2011.

Revised on August 25, 2011.

Accepted on September 5, 2011.