



Two cases of uveitis masquerade syndrome caused by bilateral intraocular large B-cell lymphoma

Dva bolesnika sa maskiranim sindromom uveitisa nastalim kao posledica obostranog intraokularnog limfoma velikih B-ćelija

Svetlana Jovanović*[†], Zorica Jovanović[†], Jelena Paović*[§],
Vesna Stanković Čeperković[†], Snežana Pešić[†], Vujica Marković*[§]

*Clinic of Ophthalmology, Clinical Center "Kragujevac", Kragujevac, Serbia; [†]Faculty of Medicine, University of Kragujevac, Kragujevac, Serbia; [‡]Clinic of Ophthalmology, Clinical Center of Serbia, Belgrade, Serbia; [§]Faculty of Medicine, University of Belgrade, Serbia

Abstract

Introduction. Sometimes it is not easy to clinically recognize subtle differences between intraocular lymphoma and non-infectious uveitis. The most common lymphoma subtype involving the eye is B-cell lymphoma. **Case report.** We presented two patients aged 59 and 58 years with infiltration of the subretinal space with a large B-cell non-Hodgkin intraocular lymphoma. The patients originally had clinically masked syndrome in the form of intermediate uveitis. As it was a corticosteroid-resistant uveitis, we focused on the possible diagnosis of neoplastic causes of this syndrome. During hospitalization, the neurological symptoms emerged and multiple subretinal changes accompanied by yellowish white patches of retinal pigment epithelium with signs of vitritis, which made us suspect the intraocular lymphoma. Endocranial magnetic resonance imaging established tumorous infiltration in the region of the left hemisphere of the cerebellum. The histopathological finding confirmed the diagnosis of large B-cell non-Hodgkin lymphoma of risk moderate degree, immunoblast – centroblast cytological type. The other patient had clinical chronic uveitis accompanied by yellowish shaped white echographic changes of the retina and localized changes in the level of the subretina. The diagnosis of lymphoma was made by brain biopsy. **Conclusion.** Uveitis masquerade syndrome should be considered in all patients over 40 years with idiopathic steroid-resistant uveitis. Treatment begun on time can affect the course and improve the prognosis of uveitis masquerade syndrome (UMS) and systemic disease.

Key words:

eye neoplasms; lymphoma, non-hodgkin; uveitis; diagnosis, differential.

Apstrakt

Uvod. Ponekad je teško ustanoviti suptilnu razliku između intraokularnog limfoma i neinfektivnog uveitisa. Najčešći podtip intraokularnog limfoma je B-ćelijski limfom. **Prikaz bolesnika.** Prikazali smo dva bolesnika, starosti 59 i 58 godina, sa infiltracijom subretinalnog prostora velikim B-ćelijama non-Hodgkin intraokularnog limfoma. Prvi bolesnik prvobitno je imao kliničku sliku maskiranog sindroma u vidu intermedijalnog uveitisa. Kako se radilo o kortikosteroid-rezistentnom uveitisu, usredsredili smo se na moguću dijagnozu neoplastičnog uzroka ovog maskiranog sindroma. U toku hospitalizacije na neurologiji pojavili su se subretinalni eksudati praćeni žučkastobeličastim promenama retinalnog pigmentnog epitela i znacima vitritisa koji su nas naveli na sumnju na intraokularni limfom. Magnetna rezonanca (MR) endokranijuma potvrdila je infiltraciju leve hemisfere cerebeluma. Patohistološki nalaz operisanog tumora cerebeluma potvrdio je dijagnozu non-Hodgkin limfoma velikih B-ćelija, umerenog stepena rizika, imunoblast-centroblastom citološkog tipa. Drugi bolesnika imao je kliničku sliku hroničnog zadnjeg uveitisa sa žučkasto beličastim promenama retine i ehografski lokalizovanim promenama u nivou subretine. Dijagnoza limfoma postavljena je biopsijom mozga. **Zaključak.** Uveitis maskirani sindrom (UMS) treba razmotriti kod svih bolesnika starijih od 40 godina sa idiopatskim kortikosteroid-rezistentnim uveitisom. Lečenje započeto na vreme može uticati na tok i poboljšati prognozu UMS i sistemske bolesti.

Ključne reči:

oko, neoplazme; limfom, nehodžkinov; uveitis; dijagnoza, diferencijalna.

Introduction

Uveitis masquerade syndromes (UMSs) are a group of non-inflammatory ocular diseases of benign or malign origin^{1,2}. A neoplastic lesion causes intraocular cellular infiltration and mimics intraocular inflammation, simulating immune mediated uveitis, poorly or not at all responsive to corticosteroid treatment. Because UMSs are not only sight-threatening but in case of malign UMSs also a life-threatening disease, prompt and correct diagnosis and treatment is very important³.

The World Health Organization (WHO) / Revised European-American Classification of Lymphoid Neoplasms (REAL) immunophenotypic classification identifies 3 types of lymphomas: B-cell neoplasms, T-cell and natural killer (NK) cell neoplasms and Hodgkin's disease⁴.

Intraocular lymphoma can be further classified either as primary B-cell lymphoma of the retina and central nervous system (CNS) or as extranodal lymphoma of the uvea, or as a secondary B-cell lymphoma that represents uveal manifestation of systemic lymphoma. The most common lymphoma subtype involving the eye is B-cell lymphoma⁴. Suspicion is needed if symptoms are unilateral or occurs in very young children or in the elderly.

Primary intraocular lymphoma (PIOL) is, in fact, a subtype of primary central nervous system lymphoma (PCNSL) and non-Hodgkin's lymphoma (NHL). Neuraxis consists of not only the brain and spinal cord, but also the neurosensory retina. PCNSL is most commonly a B-cell tumor, though T-cell PCNSL has been described⁴. As an NHL B-cell disease, PCNSL is most frequently a subtype of diffuse large B-cell lymphoma (DLBCL).

There are 3 major subtypes of DLBCL: activated B-cell DLBCL (ABC DLBCL), germinal center B-cell (GCB DLBCL), and primary mediastinal (thymic large) B-cell DLBCL (PMB DLBCL) also known as type 3, based on gene signature profiling⁵.

Ocular disease is bilateral in 50% of patients with PIOL⁶. Differential diagnosis include various diseases, such as sarcoidosis, tuberculosis, syphilis, toxoplasmosis, toxocardioid, idiopathic vasculitis and scleritis, primary ocular – CNS non Hodgkins lymphoma, large B cell lymphoma, etc.

This small, retrospective observation case study reports the clinical presentation and pathophysiologic correlation in 2 patients over 50 years of age with masquerade syndrome. Informed consent was obtained from each patient.

Comprehensive clinical ophthalmic examination using ultrasound and fluorescein angiography diagnostics was performed in both patients, who were further evaluated with computed topography (CT) and magnetic resonance imaging (MRI). All imaging modalities were conducted according to the standard protocol⁷. The diagnosis of intraocular lymphoma was based on the histopathology pattern on biopsy specimen⁸.

Case report 1

The first patient, a 59-year-old man, presented with an 11-month history of intraocular inflammation like uveitis, anterior and posterior. He had no ophthalmological disease in the past. The first ophthalmological manifestations were in the form of unilateral anterior and then posterior uveitis followed changes developed later in the same sense and on the other eye. The front uveitis was a small whitish precipitate of the endothel without plastic reactions in the sense of creating synechia. Posterior uveitis was in the form of vitritis with creamy white lesions in the level of the retina and retinal pigment epithelium (RPE) lesion boundary (Figure 1a).

The findings of ultrasound a month after showed lifting of the retinas in both eyes with masses in the subretinal space (Figures 1b and c).

Visual acuity and field of vision were changed. Initially the patient only slightly reacted to the corticosteroid therapy. After a year from the first appearance of symptoms of uveitis the patient developed neurological manifestations of the disease but still the CT finding was negative.

The third attempt with MRI detected tumor in the left hemisphere of the cerebellum. Pathohistological findings showed a diffuse large B-cell non-Hodgkin lymphoma of a moderate degree risk, immunoblast-centroblast cytological type. A diffuse large cell tumor consisted of large oval or irregular cell nuclei, with a large nucleolus and a lower number of smaller, medium or heavy amphophil basophil cytoplasm, with a rare presence of apoptosis, with a tangible body macrophage histiocytoma and numerous mitoses (Figure 1d).

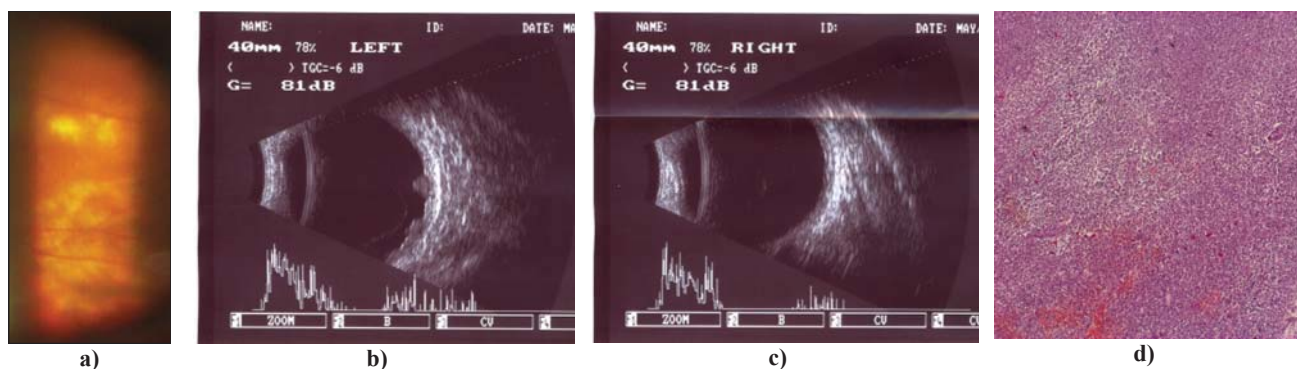


Fig. 1 – A patient with primary intraocular lymphoma showing creamy white lesions at the level of the retina and retinal pigment epithelium lesion boundary.

a) Fotofundus; b, c) Ultrasound – lifting of the retinas in both eyes with masses in the subretinal space; d) Non-Hodgkin lymphoma in the brain – B-cell, large cell diffusum (immunoblast-centroblast cytological type)

He was afebrile and his routine blood test was normal except low total red blood cell count (RBC), hemoglobin (Hgb), mean platelet volume (MPV) and relative volume of thrombocytes (Pct) were on little level. The patient did not allow biopsy of the retina.

Localization of the tumor was in the brain and subretinal space, actually in the immune privileged sites.

Case report 2

The second patient was a 58-year-old woman with anterior and posterior uveitis for several months. She showed no satisfactory respond to the treatment with corticosteroids. In fact, the therapy with corticosteroids had led to an incomplete reabsorption flare and precipitate in the front segment, with signs of vitritis in the back. The last segment was visible and the ultrasound findings showed an improvement. The posterior uveitis was manifested in the form of creamy, yellow white to orange subretinal pigment epithel (RPE) infiltrates, which also disappeared as a result of the treatment with corticosteroids, but the last segment as a whole was changed (Figure 2a).

Ultrasound suggested that intraocular lymphoma still responded to corticosteroid therapy. The fluorescein angiography in the intraocular lymphoma had a characteristic appearance. RPE disturbances included granularity, mottling, and late staining patterns. Fluorescence blockage at the level of the RPE, due to tumor infiltration could correspond to the deep retinal or subretinal creamy colored lesions noted on fundus photography. Visual acuity and visual field testing, were both reduced significantly. Intraocular (IOP) was 14 mm Hg. A routine blood test was normal except for Hgb. MR images demonstrated enhancement in the left temporal lobe. The diagnosis of lymphoma was made by brain biopsy. Histopathological finding was diffuse large B-cell non-Hodgkin lymphoma (Figures 2 b, c and d).

ophthalmologist is particularly important. Imaging of the central nervous system should be included. Imaging modalities are: full field fundus photography, ultrasound, fluorescein angiography, indocyanine green angiography, ocular coherence tomography, brain imaging. Systemic organs imaging is generally not necessary in the cases of suspected PIOL or PCNSL, and this practice is not highly recommended¹¹. When there is a reason to suspect systemic lymphoma added to the standard tests are a complete blood cell count, erythrocyte sedimentation rate, and bone marrow evaluation¹². Vitreous biopsy is a useful tool to diagnose PIOL. If it is implemented prior to steroid therapy, it might suppress the number of vitreous cells, including lymphoma cells, which may result in a negative vitreous cytology¹³. The lymphoma cells of POIL and PCNSL are very fragile, and if systemic corticosteroids are used to treat a presumed "uveitis", the lymphoma cells may be even more fragile¹⁴. Conventional ocular and brain examination includes cytological and histological examination (macroscopic and microscopic). Molecular pathology involves gene rearrangements, translocations, molecular signals, infectious deoxyribonucleic acid (DNA)¹⁵. Immunohistochemistry shows the same picture as that for PIOL. As the majority of PCNSL cells are B-cells, they stain for CD19, CD20, and surface immunoglobulin^{16,17}.

Conclusion

Sometimes, uveitis is the only initial manifestation of an occult systemic problem in patients older than 40 years. UMS should be considered in all patients with idiopathic corticosteroid resistant chronic uveitis. Primary intraocular lymphoma should be considered in all patients aged 40 and older with ultrasonographic findings of subretinal lesions and vitreous cells. Malignancies and other diseases should be considered, with implementation of diagnosis biopsies of vi-

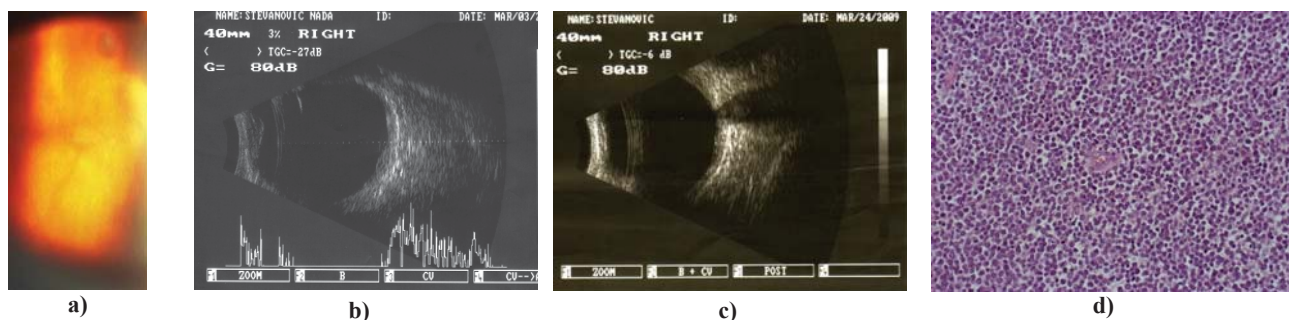


Fig. 2 – A patient with primary intraocular lymphoma showing creamy, yellow-white to orange sub-retinal pigment epithelium infiltrates

a) Fofundus; b) Ultrasound – lifting of the retinas in both eyes with masses in the subretinal space before the therapy c) after the therapy; d) Non-Hodgkin lymphoma in the brain (B-cell, large cell diffusum).

Discussion

Primary intraocular lymphoma is the most common manifestation of masked uveitis syndromes⁹. It is typically presented as posterior uveitis with cellular exudation in the vitreous fluid¹⁰. Imaging of the eye is the first step in evaluating the diagnosis with suspicion of PIOL. The role of an

trous fluid and brain. Timely treatment may improve the prognosis of UMS. Direct treatment of malignancy or underlying condition may be required to control uveitis.

Acknowledgements

This work was supported by the Grant No. 500-01-00035, the Ministry of Health of the Republic of Serbia.

R E F E R E N C E S

1. Chan CC, Wallace DJ. Intraocular Lymphoma: Update on Diagnosis and Management. *Cancer Control* 2004; 11(5): 285–95.
2. Kubicka-Trzaska A, Romanowska-Dixon B. Malignant uveitis masquerade syndromes. *Klin Oczna* 2008; 110(4–6): 199–202.
3. Choi JY, Kafkala C, Foster CS. Primary intraocular lymphoma: A review. *Semin Ophthalmol* 2006; 21(3): 125–33.
4. Parikh AH, Khan SH, Wright JD Jr, Ob KT. Systemic non-Hodgkin's lymphoma simulating primary intraocular lymphoma. *Am J Ophthalmol* 2005; 139(3): 573–4.
5. Choi JS, Nam DH, Ko YH. Primary central nervous system lymphoma in Korea: comparison of B- and T- cell lymphomas. *Am J Surg Pathol* 2003; 27(7): 919–28.
6. Wright G, Tan B, Rosenwald A, Hurt EH. A gene expression-based method to diagnose clinically distinct subgroups of diffuse large B-cell lymphoma. *Proc Natl Acad Sci USA* 2003; 100(17): 9991–6.
7. Hoffman PM, McKelvie P, Hall AJ, Stavell RJ, Santamaria JD. Intraocular lymphoma: a series of 14 patients with clinicopathological features and treatment outcomes. *Eye (Lond)* 2003; 17(4): 513–21.
8. Pileri SA, Agostinelli C, Sabattini E, Bacci F, Sagramoso C, Pileri A Jr, et al. Lymphoma classification: the quiet after the storm. *Semin Diagn Pathol* 2011; 28(2): 113–23.
9. Cogliatti SB, Schimid U. Who is Who and what is REAL? *Swiss Med Wkly* 2002; 132(43–44): 607–17.
10. Rothova A, Ooijman F, Kerkhoff F, Van Der Lelij A, Lokhorst HM. Uveitis masquerade syndromes. *Ophthalmology* 2001; 108(2): 386–99.
11. Nussenblatt RB, Chan CC, Wilson WH, Hochman J, Gottesman M; CNS and Ocular Lymphoma Workshop Group. International Central Nervous System and Ocular Lymphoma Workshop: recommendations for the future. *Ocul Immunol Inflamm* 2006; 14(3): 139–44.
12. Leary-Clarke GA, Chan CC, Nussenblatt RB. Diagnosis and management of primary intraocular lymphoma. *Hematol Oncol Clin North Am* 2005; 19(4):739–49.
13. Buggage RR, Chan CC, Nussenblatt RB. Ocular manifestation of centralnervous system lymphoma. *Curr Opin Oncol* 2001; 13(3): 137–42.
14. Kim E, Kim C, Lee J, Cho Y. A case of primary intraocular lymphoma treated by intravitreal methotrexate. *Korean J Ophthalmol* 2009; 23(3): 210–4.
15. Wallace DJ, Shen D, Read GF, Miyayaga M, Mochizuki M, Sen HN, et al. Detection of the bcl-2 t(14;18) translocation and proto-oncogene expression in primary intraocular lymphoma. *Invest Ophthalmol Vis Sci* 2006; 47(7): 2750–6.
16. Basbir R, MaManus B, Cuningham C, Weisburger D, Hosbberg F. Detection of Eber-1 RNA in primary brain lymphomas in immunocompetent and immunocompromised patients. *J Neurooncol* 1994; 20(1): 47–53.
17. Schlegel U. Primary CNS Lymphoma *Ther Adv Neurol Disord* 2009; 2(2): 93–104.

Received on September 12, 2011.

Accepted on June 11, 2012.