



## Bilateral cortical blindness secondary to tuberculous meningitis in a young Indian female

Meenakshi wadhvani<sup>1\*</sup>, Rajiv Garg<sup>2</sup>, Anil Gurtoo<sup>3</sup>

We are reporting this case to highlight the importance of prompt treatment and diagnosis in case of tuberculous meningitis. A 30 year old female presented with the complaint of sudden painless total loss of vision for the past five days. This diminution of vision was associated with headache and fever (99°F) for the past one month. There was no history of seizure, painful ocular movement or ocular trauma. Patient was taken to medical practitioner where she was started on intravenous medication nature not known and was referred to our hospital. There was a past history of pulmonary tuberculosis 4 year back for which she took antitubercular treatment for 1 year (Isoniazid, Rifampicin, Pyrizinamide, Ethambutol and Streptomycin) was declared cured. Patient looked emaciated, thin built and had altered sensorium. On systemic examination, all the systems were within normal limits except for her neurological system which revealed a positive Babinski sign and neck rigidity. On ocular examination her visual acuity in both the eyes was no perception of light. Pupils were normal in size, direct and consensual pupillary reactions were normal in both the eyes, ocular movements were full in both the eyes. In posterior segment examination, optic nerve and rest of the fundus was within normal limits. Rest of the examination of anterior and posterior segments of both the eyes were within normal limits. Intraocular pressure was within normal limit<sup>1</sup>. CT scan of head showed hydrocephalus with infarct in both the occipital lobes (Fig. 1A,B). She was admitted on emergency basis in the ophthalmology ward with a

provisional diagnosis of hydrocephalus secondary to tuberculous meningitis with cortical blindness and was started on I/V mannitol and oral acetazolamide and injection dexamethasone 1mg/kg.

Her routine hematological and biochemical tests done on the day of admission was within normal limits. Her chest x ray did not show any active tubercular lesion. Her general condition deteriorated on second day, she had three episodes of vomiting and stopped responding to verbal commands and was shifted to Neurology ward where she was started on 5 drug (HRZES) antitubercular treatment, I/V vancomycin, I/V acyclovir, 5% dextrose drip. Lumbar puncture was done and CSF studies showed presence of coagulum, ADA 12.20, total proteins 90.10 mg/dl, globulin not increased, glucose 33, chloride 126, 0.24 x10<sup>9</sup> cells with predominant lymphocytes and no AFB. Her HIV was non reactive. Despite of all the above treatment her condition deteriorated and she died on fifth day.

GJMEDPH 2013; Vol. 2, issue 3

<sup>1</sup> Pool officer  
RPC, AIIMS  
New Delhi, India

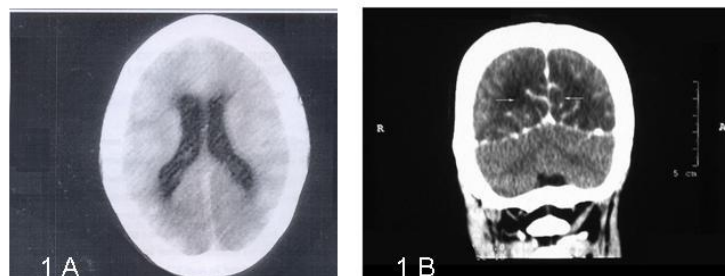
<sup>2</sup> Prof. Ophthalmology  
L.H.M.C.  
New Delhi, India

<sup>3</sup> Prof. and HOD Medicine  
L.H.M.C.  
New Delhi, India

\*Corresponding Author  
Pool officer  
RPC, AIIMS  
New Delhi, India  
mkgang08@gmail.com

Conflict of Interest—none

Funding—none



**Figure 1(A) Axial section showing mid dilatation of both the lateral ventricles suggestive of hydrocephalus (B) Coronal section showing hypodense areas (arrows) in both the occipital lobes suggestive of infarct in both the grey and white matter**


Tuberculous meningitis is particularly a distressing disease. Meningitis can result from direct meningeal invasion during a tuberculous bacilleamia either at the time of initial infection or at the time of breakdown of an old pulmonary infection. It can also result from breakdown of an old parameningeal focus with rupture into the subarachnoid space, leading to diffuse meningitis or localized arteritis. Small or large vessel arteritis is the principal feature in the presentation of tuberculous meningitis. Cortical blindness could possibly be due to arteritis (posterior inferior cerebellar arteries) leading to infarction of occipital lobe<sup>4,5</sup>. In view of her past history, present clinical examination, CSF findings and CT scan a provisional diagnosis of tubercular meningitis was made. Cerebral vasculitis and infarction may have resulted due to relapse of her disease. It is possible

that cerebral arteritis and ischemia leading to occipital lobe infarct resulted in sudden onset of cortical blindness<sup>1-3</sup>.

Even inspite of prompt and rapid treatment patient died on the fifth day. This indicates the bad prognosis in a patient of cortical blindness with tubercular meningitis. The cause of death could be diffuse arteritis therefore leading to ischemia and infarction of occipital lobe. In meningitis, the scan may be normal but can also show diffuse edema or obstructive hydrocephalus. The treatment strategy for tuberculous meningitis and hydrocephalus should be aggressive, anti-tuberculous drugs and wherever necessary intravenous steroids should be started<sup>5</sup>.

#### REFERENCES

1. Garg R.K. Tuberculosis of the central nervous system. *Postgrad Med J.* Mar 1999;75(881):133-40.
2. Monga P.K, Dhaliwal U. Paradoxical reaction in tubercular meningitis resulting in involvement of optic radiation. *Indian J Ophthalmol*:2009;57:139-41.
3. Semlali S, El Kharras A, Mahi M, Hsaini Y, Benameur M, Aziz N, et al. Imaging features of CNS tuberculosis. *J Radiol.* Feb 2008;89(2):209-20.
4. Rock R.B, Olin M, Baker C.A, Molitor T.W, Peterson P.K. Central nervous system tuberculosis: pathogenesis and clinical aspects. *Clin Microbiol*



*Rev. Apr 2008;21(2):243-61*

5. Goel A. Tuberculous meningitis and hydrocephalus. *Neurol India. 2004;52:155.*