

Aortic aneurysm and non-Hodgkin's lymphoma in Marfan syndrome

Marfan sendromunda Hodgkin dışı lenfoma ve aort anevrizması

Sujoy Ghosh, Subrata Ghosh, Sandip Kumar Ghosh

The Ayr Hospital, Scotland, UK

Abstract

The combination of Marfan syndrome with lymphoma is extremely rare. This report describes a case of Marfan syndrome who presented with chest discomfort and was diagnosed to have an aortic aneurysm and an additional incidental mediastinal mass that on further investigation turned out to be a diffuse large B cell lymphoma. We have suggested a hypothesis which can explain the occurrence of lymphoma in Marfan syndrome. (*Turk J Hematol 2009; 26: 31-3*)

Key words: Marfan syndrome, non-Hodgkin's Lymphoma, aortic aneurysm, TGF-beta, Fibrillin

Received: August 29, 2007 Accepted: June 19, 2008

Özet

Marfan sendromu ile lenfoma kombinasyonu oldukça enderdir. Bu rapor, göğüs rahatsızlığı ile gelen ve aort anevrizması ve tesadüfen ilave bir mediastinal kitlesi olduğu tespit edilen bir Marfan sendromu olgusunu anlatmaktadır. Daha ileri bir tetkik ile bu mediastinal kitlenin diffüz büyük B hücreli lenfoma olduğu açığa çıkmıştır. Marfan sendromunda lenfoma oluşumunu açıklayabilen bir hipotez ileri sürdük. (*Turk J Hematol 2009; 26: 31-3*)

Anahtar kelimeler: Marfan sendromu, Hodgkin dışı lenfoma, aort anevrizması, TGF-beta, Fibrillin

Geliş tarihi: 29 Ağustos 2007 Kabul tarihi: 19 Haziran 2008

Introduction

The combination of Marfan syndrome with lymphoma is extremely rare. Marfan syndrome can present with different complications, of which aortic dissection and valvular aortic regurgitation are perhaps the most dreaded.

Case Report

A 66-year-old man presented with light-headedness and discomfort in his throat and chest and minimal

weight loss. The findings on physical examination were consistent with Marfan syndrome: height of 184 cm and the lower segment was disproportionately longer, with a high-arched palate, mild dolichocephaly and positive thumb sign. He did not have any evidence of anemia, hepatosplenomegaly or clinically significant lymphadenopathy.

On echocardiography, he was found to have an aortic regurgitation with possible aortic aneurysm. On further imaging (T2-weighted magnetic resonance imag-

ing [MRI]-fast spoiled gradient-echo [FSPGR]), it was found that he had an aneurysm of the ascending aorta (7.3x7.2 cm) and additionally a mass in the anterior mediastinum (9.6x5.2 cm). A computerized tomography (CT)-guided biopsy of the mass revealed a diffuse large B-cell lymphoma. The lymphoid cells examined showed CD 20, BCL 2 and BCL 6 positivity. The tumor had a high proliferation rate and almost all cells were Ki67 positive.

He underwent chemotherapy (rituximab CHOP) and on follow-up scan the lymphoid mass had almost disappeared (10x6 mm) and no longer had high metabolic activity as established by positron emission tomography (PET) scan.

The aneurysm remained stable and is being followed. Currently, the patient is on no medications and is doing well.

Discussion

Marfan syndrome is a disorder of connective tissue and is associated with ectopia lentis, flat cornea, increased axial length of globe, hypoplastic iris or hypoplastic ciliary muscles, and various skeletal abnormalities. Cardiovascular abnormalities include aortic dissection and aortic regurgitation. Those with Marfan syndrome have a greater chance of spontaneous pneumothorax, striae atrophicae, recurrent or incisional hernia, and lumbosacral dural ectasia. The diagnosis is based on the revised diagnostic criteria for Marfan syndrome [1].

The clinical presentation may be chest discomfort because of an aortic aneurysm. Though in this case it was difficult to ascertain the exact cause of the chest discomfort, it could well have been due to either the aortic aneurysm with aortic regurgitation or the mediastinal mass (lymphoma). The diagnosis of the aortic dissection was made initially by echocardiography and confirmed by MRI.

Diffuse large B-cell lymphoma is treated with combination chemotherapy. In this case, the patient had complete remission with combination chemotherapy.

The combination of Marfan syndrome with lymphoma is extremely rare. The first report of the said association was published in Italian [2]. The second case was recently reported from Greece [3]. Our patient, it would appear, is the third to be reported in the world literature.

What could possibly be the connection between Marfan syndrome and lymphoma? Is there any common underlying mechanism that can unify the two? The answer is not yet known.

We know that Marfan syndrome is an autosomal dominant disorder and is caused by an abnormality in the fibrillin-1 gene located on chromosome 15. Fibrillin-1 is normally present in the matrix and regulates activation of transforming growth factor (TGF)- β . Dysregulation of TGF- β activation is said to contribute to the pathogenesis of Marfan syndrome. Aberrant activation of TGF- β by dysfunctional fibrillin-1 has also been thought to be the central abnormality in the pathogenesis of aortic aneurysm and myxomatous valve changes in Marfan syndrome [4]. Studies have also linked mutation in genes encoding TGF- β receptor 2 with familial aortic aneurysm and dissection [5]. Similar mutations have been reported in Marfan syndrome [6].

TGF- β s are multifunctional growth factors that have a critical role in cell proliferation, cell cycle arrest, differentiation, programmed cell death, and matrix deposition. It is an important negative regulator of normal lymphocytes and can induce apoptosis. TGF- β s are synthesized as pre-propolypeptides and then processed in Golgi apparatus to produce mature TGF- β and its propeptide (latency associated peptide [LAP]). Dimers of mature TGF- β and LAP form a complex - small latency complex (SLC) - which is covalently bound to another protein called latent TGF- β binding protein (LTBP), forming a large latent complex (LLC) that is secreted into the extracellular space where it binds to the extracellular matrix. Fibrillin-1 normally present in the extracellular matrix binds LLC and acts to limit the activation of TGF- β [7]. It seems that alteration in fibrillin-1 in Marfan syndrome diminishes the ability of fibrillin-1 to sequester the LLCs and this releases excess TGF- β into the matrix, leading to abnormal matrix.

Smad proteins play a key role in signal transduction of family members of TGF- β . Through Smad-1, TGF- β affects proliferation, survival and differentiation of cells (including malignant lymphocytes). Aberrant Smad pathway signalling has a pathophysiological role in non-Hodgkin's lymphomas (Figure 1).

TGF- β binds to cell surface receptors (TGFBR1). The complex so formed recruits and phosphorylates TGFBR1 receptor to form a Type I/Type II receptor complex. The activated Type I receptor provides anchorage for receptor Smad protein (R-Smad) and induces phosphorylation of R-Smads and associated Smad-1 and Smad-4 (serine-threonine change in C-terminal end). The phosphorylated Smad translocates to the nucleus and regulates gene expression and causes increased proliferation of the malignant cells.

TGFBR1 blocking antibodies inhibit Smad-1 phosphorylation and Smad-1/Smad-4 complex formation, and inhibits events further downstream.

In high-grade lymphomas, TGF- β expression is twice that seen in low-grade non-Hodgkin's lymphoma. As mentioned above, phosphorylation of Smad-1 is normally mediated by TGF- β in the microenvironment [8].

Studies have confirmed the role of the TGF- β high-producer genotype as a risk factor of non-Hodgkin's lymphoma. In addition, it has been shown that such patients have clinically and histologically more aggressive disease. The TGF- β gene polymorphism, in addition, has been shown to influence the course of disease in non-Hodgkin's lymphoma patients. Those with certain mutations (TCGG or TTGG) tend to present with two or more extranodal site involvements [9]. Thus, it would seem that TGF- β plays a key role in the pathogenesis and course of disease in non-Hodgkin's lymphoma patients.

It has been reported recently that there is probably a role of fibrillin-1 and TGF- β in the pathogenesis and course of hepatocellular carcinoma in patients with coexistent aortic dissection [10].

Further research is needed for a better understanding of a possible unifying pathogenesis.

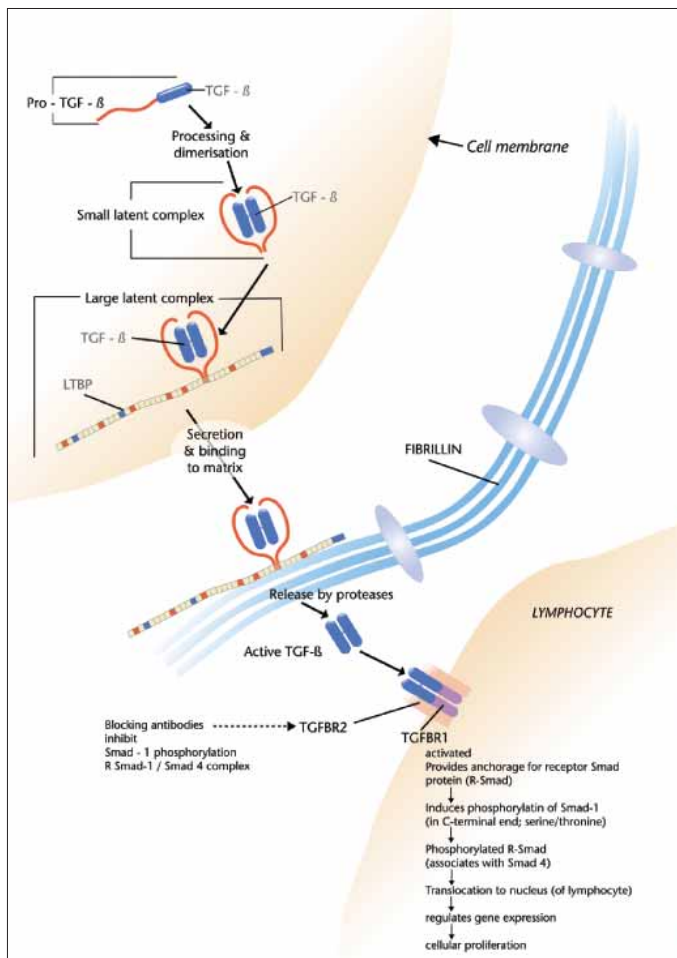


Figure 1. In Marfan syndrome, there is abnormal fibrillin; therefore, there is impaired binding of large latent complex to fibrillin. Thus, more active TGF-beta is released by proteases

Acknowledgement

We are highly indebted to Sarah Syme (Medical photography, NHS Ayrshire and Arran) for her help with the illustration.

References

1. De Paepe A, Devereux RB, Dietz HC, Hennekam RC, Pyeritz RE. Revised diagnostic criteria for the Marfan syndrome. *Am J Med Genet* 1996 Apr 24;62:417-26.
2. Corso A, Pagnucco G, Morra E, Bernasconi C. The diagnosis of non-Hodgkin's lymphoma in a patient with Marfan's syndrome [Article in Italian]. *Minerva Med* 1993;84:417-9.
3. Lachanas E, Tomos P, Fotinou M, Miyakis S. Lymphoma presenting as chronic dissection in Marfan syndrome. *Ann Hematol* 2006;85:181-2.
4. Neptune ER, Frischmeyer PA, Arking DE, Myers L, Bunton TE, Gayraud B, Ramirez F, Sakai LY, Dietz HC. Dysregulation of TGF-beta activation contributes to pathogenesis in Marfan syndrome. *Nat Genet* 2003;33:407-11.
5. Pannu H, Fadulu VT, Chang J, Lafont A, Hasham SN, Sparks E, et al. Mutations in transforming growth factor-β receptor type II cause familial thoracic aortic aneurysms and dissections. *Circulation* 2005;112:513-20.
6. Mizuguchi T, Collod-Beroud G, Akiyama T, Abifadel M, Harada N, Morisaki T, et al. Heterozygous TGFBR2 mutations in Marfan syndrome. *Nat Genet* 2004;36: 855-60.
7. Kaartinen V, Warburton D. Fibrillin controls TGF-beta activation. *Nat Genet* 2003;33:331-2.
8. Munoz O, Fend F, de Beaumont R, Husson H, Astier A, Freedman AS. TGFbeta-mediated activation of Smad1 in B-cell non-Hodgkin's lymphoma and effect on cell proliferation. *Leukemia* 2004;18:2015-25.
9. Mazur G, Bogunia-Kubik K, Wrobel T, Kuliczowski K, Lange A. TGF-beta1 gene polymorphism influences the course of the disease in non-Hodgkin's lymphoma patients. *Cytokine* 2006;33:145-9.
10. Takagi H, Manabe H, Sekino S, Kato T, Matsuno Y, Umemoto T. Coexistent aortic dissection and hepatocellular carcinoma with elevated plasma transforming growth factor beta level: possible roles of fibrillin 1 and transforming growth factor beta. *J Thorac Cardiovasc Surg* 2005;129:462-3.