

Acute massive myelofibrosis with acute lymphoblastic leukemia

Akut masif myelofibrozis ve akut lenfoblastik lösemi birlikteliği

Zekai Avcı¹, Barış Malbora¹, Meltem Gülşan¹, Feride İffet Şahin², Bülent Celasun³, Namık Özbek¹

¹Department of Pediatrics, Başkent University Faculty of Medicine, Ankara, Turkey

²Department of Medical Genetics, Başkent University Faculty of Medicine, Ankara, Turkey

³Department of Pathology, Başkent University Faculty of Medicine, Ankara, Turkey

Abstract

Acute myelofibrosis is characterized by pancytopenia of sudden onset, megakaryocytic hyperplasia, extensive bone marrow fibrosis, and the absence of organomegaly. Acute myelofibrosis in patients with acute lymphoblastic leukemia is extremely rare. We report a 4½-year-old boy who was diagnosed as having acute massive myelofibrosis and acute lymphoblastic leukemia. Performing bone marrow aspiration in this patient was difficult (a “dry tap”), and the diagnosis was established by means of a bone marrow biopsy and immunohistopathologic analysis. The prognostic significance of acute myelofibrosis in patients with acute lymphoblastic leukemia is not clear. (*Turk J Hematol 2009; 26: 204-6*)

Key words: Acute myelofibrosis, acute lymphoblastic leukemia, dry tap

Received: April 9, 2008

Accepted: December 24, 2008

Özet

Akut myelofibrozis ani gelişen pansitopeni, kemik iliğinde megakaryositik hiperplazi, belirgin fibrozis ve organomegali olmaması ile karakterize bir hastalıktır. Akut myelofibrozis ile akut lenfoblastik lösemi birlikteliği çok nadir görülmektedir. Burada akut masif myelofibrozis ve akut lenfoblastik lösemi tanısı alan 4,5 yaşında erkek hasta sunuldu. Kemik iliği aspirasyonu yapılamayan (“kuru ilik”) hastanın tanısı, ancak kemik iliği biyopsisi ve immünohistopatolojik inceleme ile konabildi. Akut myelofibrozinin akut lenfoblastik lösemide prognostik önemi tam bilinmemektedir. (*Turk J Hematol 2009; 26: 204-6*)

Anahtar kelimeler: Akut myelofibrozis, akut lenfoblastik lösemi, kuru ilik

Geliş tarihi: 9 Nisan 2008

Kabul tarihi: 24 Aralık 2008

Introduction

Idiopathic primary myelofibrosis is a chronic disorder characterized by bone marrow fibrosis, extramedullary hematopoiesis, and a leukoerythroblastic blood profile, and it is usually classified as a myeloproliferative syndrome. A rapidly progressive form of myelofibrosis, called “malignant myelofibrosis”

or “acute myelofibrosis (AMF)”, is characterized by pancytopenia of sudden onset, megakaryocytic hyperplasia, excessive marrow fibrosis, and the absence of hepatosplenomegaly [1-3]. Primary myelofibrosis also occurs in those with acute leukemia (especially the myelocytic types); however, AMF that develops in individuals with acute lymphoblastic leukemia (ALL) is extremely rare. We report a 4½-year-old boy diagnosed with AMF and ALL.

Case Report

A 4½-year-old boy who presented with a one-month history of fever, fatigue, and abdominal pain was initially diagnosed as having typhoid fever and was treated with ceftriaxone for seven days. He was referred to our clinic because of coexisting anemia and leukopenia. This child was a monozygotic twin born to healthy nonconsanguineous parents, and his growth and development were within normal limits. His vital signs at admission were as follows: body temperature 38.4°C, blood pressure 100/60 mmHg, and pulse rate 120 bpm. The initial physical examination did not reveal lymphadenopathy or hepatosplenomegaly. This patient demonstrated no phenotypic signs of Down syndrome or mosaicism. The results of a complete blood count revealed the following values: white blood cell count, $3.6 \times 10^9/L$ (26% neutrophils, 7% monocytes, 64% lymphocytes, and 3% blasts); hemoglobin, 8.9 g/dl; platelet count, $315 \times 10^9/L$; and reticulocyte count, 0.93%. The results of serum biochemical analyses were all within the normal range, except for the serum lactate dehydrogenase level, which was 634 IU/L (normal range: 150-500 IU/L). The sedimentation rate was 120 mm/h, and the level of C-reactive protein was 168 mg/dl (normal range, 0-10 mg/dl). Direct Coombs' test and an antinuclear antibody test were negative, and the levels of serum immunoglobulins G, M, and A as well as complements 3 and 4 were within the reference range. Chest radiograph and abdominal ultrasonographic findings were unremarkable. The results of viral serologic testing, including that for Epstein-Barr virus (EBV), cytomegalovirus (CMV), parvovirus B19, human immunodeficiency virus (HIV), and hepatitis A, B, and C, were negative, as were the results of the Widal test for *Salmonella* and the Wright agglutination test for *Brucella*. The bone marrow aspiration was a dry tap in each of three consecutive attempts. The bone marrow biopsies revealed a diffuse blastic infiltration (Figure 1). On immunohistopathologic examination, the blasts were positive for CD34, CD10, TdT, CD20, and CD79a. The results of staining for CD3, CD41, CD43, CD56, CD117, and myeloperoxidase were negative. The reticulin fibers were increased in number, especially at sites in which neoplastic infiltration was intense (Figure 2). Conventional cytogenetic and fluorescent *in situ* hybridization (FISH) analyses were performed from deparaffinized bone marrow biopsy. Unstimulated bone marrow lymphocyte

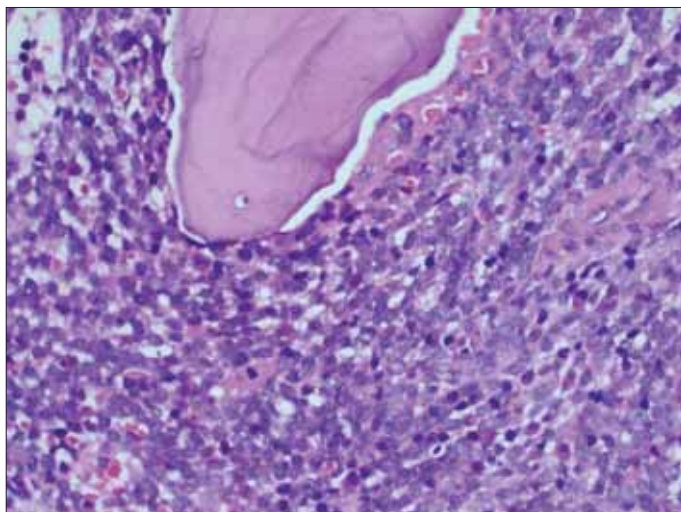


Figure 1. Bone marrow biopsy showing a diffuse infiltrate of lymphoblasts (hematoxylin-eosin stain, original magnification x 400)

cultures were set up for incubation time of 48 and 72 hours, and metaphase spreads were examined after harvesting and GTG banding according to standard protocols. Three metaphases were found and revealed a 46, XY karyotype. FISH studies were also performed with probes specific for 5q31, 7q31, *BCR-ABL* fusion, and t(15;17) (Vysis, Downers Grove, IL, USA), and revealed normal signals except for an extra signal with the translocation probe t(8;21) (Vysis, Downers Grove, IL, USA) for chromosome 21q22 region in 22% of the cells. With the extra signal for 21q22, we decided to perform chromosome analysis from peripheral blood and skin biopsy samples of the patient, which revealed normal karyotypes.

The patient was diagnosed as having B-cell ALL with acute massive myelofibrosis. He is currently being treated according to the Berlin-Frankfurt-Munster (BFM) 95 treatment protocol for ALL. On day 15 of the chemotherapy, repeated bone marrow aspiration was a dry tap. A bone marrow biopsy showed necrosis between bone trabeculae and significant fibrosis, as well as an increased number of reticulin fibers and no hematopoietic cells. At day 33 of the chemotherapy regimen, a bone marrow biopsy revealed persisting necrosis with foci of immature bone formation and massive collagen fibrosis. No hematopoietic cells were noted. At day 70 of the chemotherapy and before continuation therapy, a bone marrow aspiration and biopsy showed normal hematopoietic cells and no fibrosis. At the time of this writing (20 months after diagnosis), the patient is still in clinical remission and is being treated with a continuation chemotherapy regimen.

Written informed consent was obtained from the patient and the family.

Discussion

Acute myelofibrosis is known to progress to various types of acute myeloid leukemia and chronic myelogenous leukemia. Of particular interest is the rare termination of AMF as ALL, which has been reported in two pediatric patients. In one of those children, AMF terminated as ALL of T-cell origin, and in the other, AMF terminated as null-type ALL [4,5]. In addition to those two cases, Abl and Ye [1] recently reported a child with B-ALL and AMF. They did not know whether or not myelofibrosis was present previously and terminated to ALL in that patient, but his massive

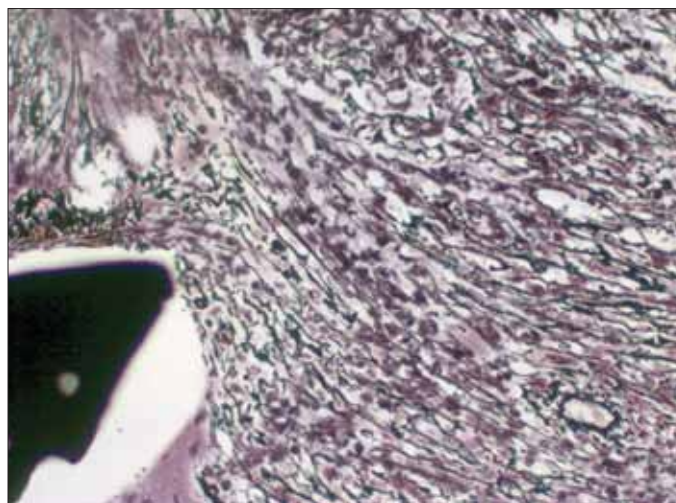


Figure 2. Reticulin stain showing an increased number of fibers at the time of diagnosis (original magnification x 400)

myelofibrosis was most likely due to secretion of cytokines from blastic cells. The same situation was probably present in our case. To our knowledge, only four adult patients with AMF terminating as ALL have been described in the literature [2,3,6,7]. Three of seven reported cases including both children and adults in the literature died within two months of diagnosis. However, it is difficult to determine the prognostic significance of AMF in patients with ALL due to small number of cases reported to date.

Cytogenetic studies of patients with myelofibrosis have shown that the presence of 13q-, 20q-, +8, and abnormalities of chromosomes 1,7 and 9 constitute more than 80% of the chromosomal changes in those individuals and suggest that in many patients, gene loss and/or inactivation may be an important pathogenetic mechanism in the development of myelofibrosis [8]. Cytogenetic analysis of peripheral blood and skin fibroblast cultures in our patient revealed a 46,XY genotype. However, the results of a FISH analysis from bone marrow confirmed the presence of trisomy 21 in 22% of the cells in our patient. It is well known that AMF is associated with Down syndrome [9]. Our patient did not have any phenotypic or karyotypic feature of Down syndrome. Although we did not detect a karyotype abnormality in the peripheral blood and skin fibroblast culture, we concluded that there could be a cryptic chromosome abnormality limited to the leukemic cell population, and the extra copy of chromosome region 21q22 could be responsible for the myelofibrosis.

Finally, it should be remembered that dry taps are caused by a marked increase in reticulin fibrosis. In patients who experience that difficulty, bone marrow biopsy can be of great help in making an accurate diagnosis, as in our patient.

No author of this paper has a conflict of interest, including specific financial interests, relationships, and/or affiliations relevant to the subject matter or materials included in this manuscript.

References

1. Abla O, Ye CC. Acute lymphoblastic leukemia with massive myelofibrosis. *J Pediatr Hematol Oncol* 2006;28:633-4.
2. Amjad H, Gezer S, Inoue S, Bollinger RO, Kaplan J, Carson S, Bishop CR. Acute myelofibrosis terminating in an acute lymphoblastic leukemia: a case report. *Cancer* 1980;46: 615-8.
3. Dunphy CH, Kitchen S, Saravia O, Velasquez WS. Acute myelofibrosis terminating in acute lymphoblastic leukemia: case report and review of the literature. *Am J Hematol* 1996;51:85-9.
4. Chen JS, Lin DT, Chuu WM, Lin KH, Su IJ, Lin KS. Acute myelofibrosis terminating in acute lymphoblastic leukemia: report of one case. *Zhonghua Min Guo Xiao Er Ke Yi Xue Hui Za Zhi* 1992;33:136-43.
5. Marino R, Altshuler G, Humphrey GB. Idiopathic myelofibrosis followed by acute lymphoblastic leukemia. *Am J Dis Child* 1979;133:1194-5.
6. Polliack A, Prokocimer M, Matzner Y. Lymphoblastic leukemic transformation (lymphoblastic crisis) in myelofibrosis and myeloid metaplasia. *Am J Hematol* 1980;9:211-20.
7. Amberger DM, Saleem A, Kemp BL, Truong LD. Acute myelofibrosis-a leukemia of pluripotent stem cell. A report of three cases and review of the literature. *Ann Clin Lab Sci* 1990;20:409-14.
8. Reilly JT. Cytogenetic and molecular genetic aspects of idiopathic myelofibrosis. *Acta Haematol* 2002;108:113-9.
9. Awasthi A, Das R, Varma N, Ahluwalia J, Gupta A, Marwaha RK, Garewal G. Hematological disorders in Down syndrome: ten-year experience at a tertiary care centre in North India. *Pediatr Hematol Oncol* 2005;22:507-12.