



Original Article

Effects of young-coconut juice on increasing mandibular cancellous bone in orchidectomized rats: Preliminary novel findings

Pranee Suwanpal¹, Nisaudah Radenahmad^{2*}, Muhammadbakhoree Yusuh², Mutita Eksomtramate¹, Praphansri Ruangsri¹, and Anachak Chantanasuksilpa¹

¹ Department of Conservative Dentistry, Faculty of Dentistry,

² Department of Anatomy, Faculty of Science,
Prince of Songkla University, Hat Yai, Songkhla, 90112 Thailand.

Received 4 March 2010; Accepted 4 October 2011

Abstract

Androgens play a very important role in building the skeleton in young adults and help to prevent bone loss and osteoporosis in aging men. In addition, in hypogonadism or elderly men, bone mass has been related to estrogen levels rather than to testosterone. Estrogen replacement therapy has therefore been proposed to prevent bone loss in males as well as in females. Estrogen, however, has been considered to be one of the hormonal risk factors for benign prostatic hyperplasia and prostate cancer and also has other side effects. Young coconut juice (Y CJ) presumably containing phytoestrogen was investigated in the present study for its possible beneficial effects on delaying osteoporosis using a male rat model, and by this to test the possibility that it might be able to replace estrogen replacement therapy without side effects. In this study, mandibular cancellous bone was used as the osteoporotic model. Using the same model, we have previously found that total cartilage thickness particularly the hypertrophic zone of mandibular condylar cartilage was thicker in the sham-operated rats receiving Y CJ orally fed for a 14 day period, compared with sham, orchidectomized animal, orchidectomized rats receiving estradiol benzoate, and orchidectomized rats receiving Y CJ. The present study confirmed our former study that mandibular cancellous bone in the sham-operated rats and in the orchidectomized rats receiving Y CJ orally fed for a 14-day period were thicker than those of the sham and orchidectomized rat groups. This study results are novel and they indicate that Y CJ may have beneficial effects in the treatment of osteoporosis in andropause men.

Keywords: young coconut juice, *Cocos nucifera*, osteoporosis, bone, mandible

1. Introduction

Osteoporosis has become a major healthcare problem because of a rapidly increasing aging population. Osteoporosis is characterized by low bone mass and deterioration of bone tissue with susceptibility to fractures in vertebrae, appendicular extremities and also jaw bones (White and Rudolph, 1999; Dervis, 2005; Lee and White, 2005). It has

been calculated that by 2020 osteoporosis in American men and women is expected to rise to more than 61 million because of increasing longevity (Foundation National Osteoporosis, 2002). In Thailand, the prevalence of osteoporosis among Thai men in 2005 was 4.6% and 12.6% for the lumbar spine and femoral neck, respectively (Pongchaiyakul *et al.*, 2006), and this is expected to increase as the population ages.

Animal models have been used to define the relationship between systemic and oral bone loss. Rats have been the most widely used animal model for osteoporosis (Egermann *et al.*, 2005). Studies on the dentulous mandibles of estrogen deficient rats caused by ovariectomy (ovx) showed a thinning

* Corresponding author.

Email address: nisaudah@gmail.com

of the alveolar bone and the interradicular septum of the first molar (Tanaka *et al.*, 2002). The trabecular bone in both the mandible and the tibia in rats 16 weeks after ovx was micro-architecturally altered (Yang *et al.*, 2003). A decrease in bone mass in the mandible of male rats was also associated with orchidectomy (orx) (Lerouxel *et al.*, 2004).

In male rats, orx produce an androgen deficiency that was associated with an accelerated bone turnover and imbalance between bone resorption and bone formation, resulting in bone loss. In adult or aged rats, orx induce a high-turnover of cancellous osteopenia (Erben *et al.*, 2000) and cortical osteopenia with cortical porosity and a decrease of periosteal bone formation (Prakasam *et al.*, 1999). In normal elderly men, however, one study has demonstrated that estrogen was the dominant sex steroid regulating bone resorption rather than testosterone (Falahati-Nini *et al.*, 2000). These results indicated that estrogen also plays an important role in regulating the aged male skeleton. Estrogen replacement therapy has therefore been proposed to prevent bone loss in males as well as in females (Ockrim *et al.*, 2003). Estrogen, nevertheless, has been considered to be one of the hormonal risk factors for benign prostatic hyperplasia and prostate cancer, the most frequent cancerous tumor in males (Mercier and Inoue, 1981; Mohajery and Brooks, 1988). It is possible that phytoestrogen derived from plants may be an alternative source of estrogen for hormone replacement therapy and might also help prevent osteoporosis and other risk factors associated with estrogen therapy.

Phytoestrogens are considered to be an effective alternative estrogenic substance that can prevent bone loss caused by the deficiency of either estrogen and/or androgen (John and Sandford, 1997). There have been many research reports that have used female animal models that have demonstrated a preventive effect on bone loss by phytoestrogen e.g. soy bean (Albertazzi, 2002; Ishimi *et al.*, 2002; Button and Patel, 2004), *Pueraria lobata* (Fanti *et al.*, 1998; Ishida *et al.*, 1998; Ishimi *et al.*, 2000; Picherit *et al.*, 2000; Wang *et al.*, 2003). In contrast, there have been only a few studies in male animal models e.g. Urasopon *et al.* (2007) who found that *P. mirifica* extracts inhibited absolutely the bone loss found in orx male rats. In this study, we have investigated other plant products from *Cocos nucifera* that are known to contain phytoestrogens for bone therapy.

According to folk medicine, coconut juice (*Cocos nucifera* L., Arecaceae), contains several active compounds with various therapeutic properties. Phytoestrogens seems to have beneficial effects that include enhancement of cutaneous wound healing. Among the constituents of phytoestrogens are flavonoids, like kaemferol, isoflavones, luteoline and apigenin (Spilkova and Hubik, 1992; Havsteen, 2002). Our previous studies have demonstrated that young coconut juice (YCJ) had a wound healing effect (Sayoh *et al.*, 2008; 2011 submitted) and also indicated that one of the active compounds is likely to be a member of the flavonoid group. Furthermore, our previous study showed that, YCJ increased the thickness of mandibular condyle cartilage

(Yusuh *et al.*, 2010). The aim of this study, therefore, was to investigate any role for YCJ that presumably contains phytoestrogen, for its possible beneficial effects on delaying osteoporosis in male rats.

2. Materials and Methods

2.1 Plant material

Throughout this study, young coconut juice was collected from 6-month old fruits from one area (100 square yards) in Tungngai District, Hat Yai, Songkhla, Thailand. A large quantity of YCJ was freeze dried and the powder was kept at -30°C until used. This powder was freshly reconstituted and prepared for oral feeding every day. The complete description of YCJ, including its preparation and administration, is provided in a previous publication (Radenahmad *et al.*, 2006).

2.2 Animals

All animals used were adult two-month old male Wistar rats weighing approximately 230 g. The animals were housed in a controlled environment at 25±1°C with an illumination schedule of 12 hrs light/12hrs dark. Rats had unrestricted access to standard pellet food and water. The study was approved by the Ethics Committee on Animal Care, Reference 07/51, and was carried out in accordance with the *Guiding Principles for the Care and Use of Research Animals* promulgated by Prince of Songkla University.

2.3 Experimental design

There were five groups of rats (6 per group) included in this study. The first group consisted of sham-operated rats, the second group consisted of orx rats, and the third group consisted of orx rats injected intraperitoneally with exogenous estrogen (2.5 µg/kgBW of estradiol benzoate, EB) five days a week for two weeks. The fourth group consisted of orx rats that received YCJ (100 mL/kgBW/day) and the fifth group was sham-operated rats receiving YCJ (100 mL/kgBW/day). The dose of EB and YCJ in this study was also the same as in our earlier study (Radenahmad *et al.*, 2006). In this study, the administration of EB and YCJ was started two weeks after orchidectomy was performed. Rats belonging to the first and second groups were forced fed with deionized water.

2.4 H and E staining of the mandibular cancellous bone and morphological analysis

After sacrifice, the left mandibles were dissected, fixed in 10% formalin and decalcified with 10% formic acid solution for 30 days. Saturated ammonium oxalate solution was used to determine the completeness of decalcification. After routine histological laboratory procedures, tissues were blocked in

paraffin and coronal sections of 5 µm were cut and stained with H and E for histological examination. Three sections from the middle part of a mandible were selected for this study. Histomorphometric analysis from six random areas on each section using a trabecular bone volume (%) formula was measured as described by Parfitt (1988) and Parfitt *et al.* (1987) as follows:

$$\text{Bone volume (\%)} = \frac{\text{area of trabeculae}}{\text{area of trabeculae} + \text{marrow space}}$$

Measurements were performed using an optical microscope (Axioskop 40) coupled to a digital video camera (NOPL-A662, Media Cybernetics, Silver Spring, MD, USA) and connected to an image analysis system (Image Pro Plus 5.0 for Window, Media Cybernetics, Silver Spring, MD, USA). Slides were viewed by a researcher who had no knowledge of their origins. Readings from the three sections from each rat were then added and the average was determined.

2.5 Serum estradiol and testosterone

All the rats were sacrificed on the first day of the fifth week. Their serum was collected for estradiol (E2) and testosterone measurements using the chemiluminescent immuno assay (CIA) technique, as set out by the manufacturer (ECLIA, Modular E 170C, Estradiol II 03000079 122, Roche, Germany) and (ECLIA, Modular E 170C, testosterone 11776061 122, Roche, Germany), respectively. Details of the CIA technique have been explained in our previous publication (Radenahmad *et al.*, 2009).

2.6 Statistical analysis

Statistical analysis was performed using the Kruskal-Wallis and the Mann-Whitney U-tests available in the statistical program SPSS version 11.5. The Altman's nomogram for sample size calculations was used to determine the sample size. Random selection of the microscopic fields was achieved using a computer generated list of random numbers (Excel version 5.0). Results were reported as means ± SEM. P<0.05 was considered to be significantly different.

3. Results

3.1 Serum E2 levels

Our results showed that the sham or orx rat groups that received YCJ had serum E2 levels that were not significantly (P>0.05) different from the orx or sham operated groups (Figure 1). The serum E2 level of the orx+EB group was significantly higher (p<0.05) when compared with the other groups (Figure 1).

3.2 Serum testosterone level

Our results showed that the sham group or the sham

group receiving YCJ had serum testosterone levels significantly higher than the other groups at p<0.01 and p<0.05, respectively. Forced feeding of YCJ to the sham group caused an approximate 40% reduction in the testosterone level compared to that of the sham group (Figure 2).

3.3 Effects of YCJ on histological changes of rat mandibular bone

There was no evidence that orx by itself had any effect on the measured bone volume of mandibular cancellous bone of the male rats. After 14 days of treatment with YCJ, the mandibular cancellous bone measured as a percentages of bone volume (%BV) was thicker in the sham+YCJ, orx+YCJ

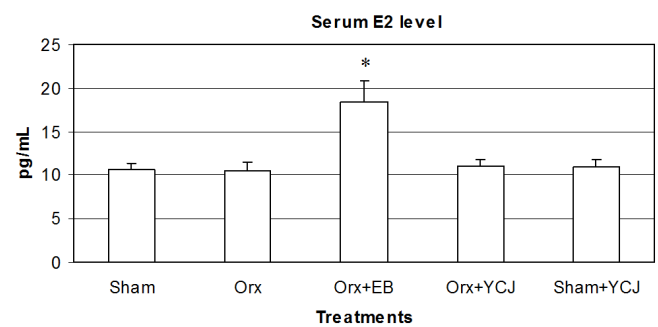


Figure 1. Serum estradiol (E2) levels (mean±SEM) in the five groups of male rats examined. Sham: sham-operated group; orx: orchidectomized group; orx+EB: orchidectomized group receiving estradiol benzoate; orx+YCJ: orchidectomized group receiving young coconut juice; sham+YCJ: sham-operated group receiving young coconut juice. n=6 in each group. *p<0.05 compared with sham, orx, orx+YCJ, and sham+YCJ groups. Note, data has been previously reported in Yusuh *et al.* (2010) for a different purpose.

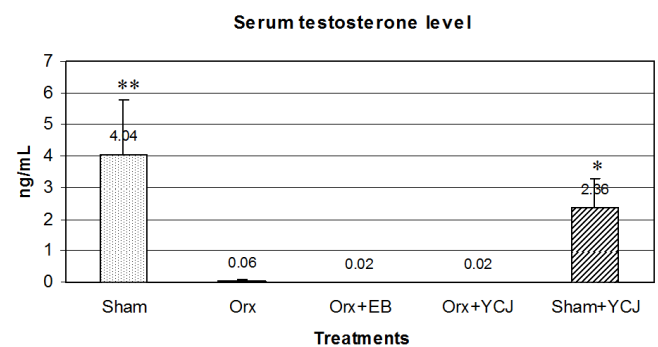


Figure 2. Serum testosterone levels (mean±SEM) in the five groups of male rats examined. Sham: sham-operated group; orx: orchidectomized group; orx+EB: orchidectomized group receiving estradiol benzoate; orx+YCJ: orchidectomized group receiving young coconut juice; sham+YCJ: sham-operated group receiving young coconut juice. n=6 in each group. *p<0.05, **p<0.01 compared with orx, orx+EB, and orx+YCJ groups. Note, data has been previously reported in Yusuh *et al.* (2010) for a different purpose.

and orx+EB groups than that of the sham and orx groups (Figure 3 and 4). The %BV of the orx+EB group was significantly higher than that of the sham group at $p < 0.05$. The %BV of the orx+YJC and sham+YJC groups was significantly higher than that of the orx group at $p < 0.05$ (Figure 3 and 4).

4. Discussion

Elderly men or men with hypogonadism are likely to suffer from osteoporosis and the number has been increasing. Estrogen, one of the treatments given, has been reported to have some risk factors such as development of benign prostatic hyperplasia and prostate cancer (Harkonen and Makela, 2004; Soronen *et al.*, 2004). Therefore, many studies have investigated the estrogenic effects of phytoestrogen for alternatives treatments for osteoporosis.

The present study was designed to evaluate the effect of YCJ, presumably containing phytoestrogen, on protecting male rats against orchidectomy-induced bone loss. In this study, estrogen and testosterone levels were measured using a CIA technique. The results were discussed in our previous publication (Yusuh *et al.*, 2010). Feeding of YCJ to sham and orx rats improved trabecular volume to a level that was not significantly different from the group fed with EB. The percentages of bone volume (%BV) of the orx+YJC and sham+YJC groups were also significantly higher than those of the orx group. This study has provided similar results to previous studies that used different plant materials. For example, Wang *et al.* (2005) studied the metaphysis of the femur, and found that *Puerariae radix* (Chinese herbal medicine) did prevent bone loss at a low dose and increased the percentages of

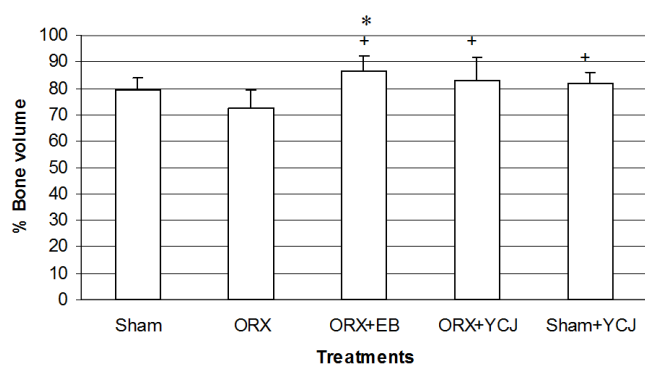


Figure 3. Histomorphometric analysis (% bone volume) of mandibular cancellous bone. The percentage of bone volume (%BV) of the orx+EB group was higher than that of the sham operated group at $p < 0.05$. The percentage of bone volume (%BV) of the orx+EB, sham+YJC, orx+YJC groups were higher than that of orx group at $p < 0.05$. Sham: sham-operated group; orx: orchidectomized group; orx+EB: orchidectomized group receiving estradiol benzoate; orx+YJC: orchidectomized group receiving young coconut juice; sham+YJC: sham-operated group receiving young coconut juice. $n=6$ in each group. *, + $p < 0.05$ compared with sham and orx groups, respectively.

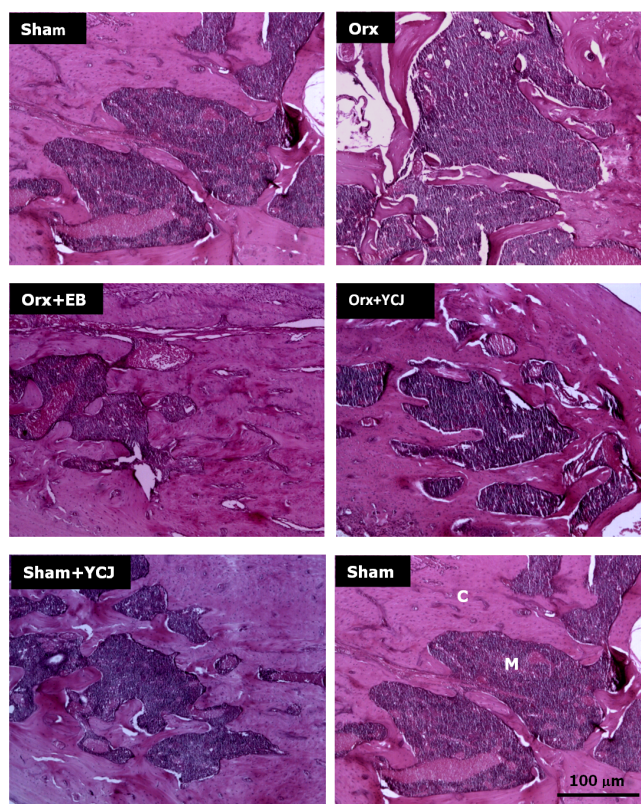


Figure 4. Coronal sections of rat mandibular bone (magnification $\times 50$). The sections were stained with hematoxylin and eosin. The percentage of bone volume (%BV) of the orx+EB, orx+YJC, and sham+YJC groups were larger than that of the sham and orx groups. The bottom right picture shows an area of cancellous bone (C) and bone marrow (M) of a "sham" rat mandibular bone. Sham: sham-operated group; orx: orchidectomized group; orx+EB: orchidectomized group receiving estradiol benzoate; orx+YJC: orchidectomized group receiving young coconut juice; sham+YJC: sham-operated group receiving young coconut juice. Scale bar=100 μm for all pictures.

bone volume/total volume (BV/TV) to levels higher than those of a high dose in a sham operated group. In agreement with the present study, those preventive effects of *P. radix* on bone loss were similar to those of E2 in orx animals. Urasopon *et al.* (2007) found that *Pueraria mirifica* can prevent bone loss and its preventive effect was significant and comparable to 17α -ethinylestradiol. Devareddy *et al.* (2007) found that blueberry juice prevented bone loss in experimental animals by inducing osteoclast apoptosis and suppressing osteoclastogenesis, thereby reducing bone resorption and a similar effect was observed with soy isoflavones. Ishimi *et al.* (2002) found that genistein, a soybean isoflavone, affected bone marrow lymphopoiesis and prevented bone loss in castrated male mice. Furthermore, our previous study confirmed that YCJ could have effects on increasing the mandibular bone volume by increasing the thickness of mandibular condyle cartilage, particularly the hypertrophic zone (Yusuh *et al.*,

2010), that is composed of differentiated chondrocytes and are the main sources of the subchondrol bone (Furseth, 1996). A similar study has been reported in orx young rats that showed a rapid decrease in cancellous bone volume in age-matched rats and that a lower bone mass was detected as early as 4-5 weeks after the surgery (Turner *et al.*, 1989; Gunness and Orwoll, 1995). That decrease in bone volume may be attributed to both increased bone resorption and reduced bone formation.

Although orx produces an androgen deficiency, the direct substances controlling the bone metabolism seems to be estrogens. The preventive effects of bone loss by specific phytoestrogens, daidzein and genistein, on the cortical part were previously reported in cortical bone cultures of female rats by an increasing calcium content and alkaline phosphatase activity in the bone tissue (Gao and Yamaguchi, 1999).

Using a radioimmunoassay technique, Pungmatharith (1988) found that 1 mL of coconut juice contained 2.45 pg of 17 β -estradiol and other sex hormone-like substances. Results from thin-layer chromatography studies have also confirmed that YCJ contains substances similar to estrone, such as 17 β -estradiol, and β -sitosterol (Pungmatharith, 1988). Such studies also found that subcutaneous injection of an ethereal extract of YCJ reconstituted at a dose equivalent to 7,500 mL of young coconut juice/kgBW/day for three consecutive days significantly increased the uterine wet weight of immature rats. Furthermore, YCJ has been found to contain β -sitosterol as well as other sterols like stigmastatrienol, stigmasterol, fucosterol etc. β -sitosterol is structurally related to animal cholesterol, and could possibly act as a precursor of sex steroids (Moghadasian, 2000). In the present study, β -sitosterol and stigmasterol (plant sterols known to be precursors of steroid hormones *in vivo*) could be responsible for the estrogenic effect of the YCJ. This remains to be confirmed.

YCJ may, however, not work in male animals in which their testes are still intact and secrete testosterone. It can be seen in Figure 2 that the testosterone levels in sham and sham+YCJ groups are much higher than in either the orx, orx+EB, or orx+YCJ groups. The effect of YCJ may be counteracted by the presence of testosterone or some unknown substance secreted by the testis. It is known that in elderly men the testosterone level decline gradually but slowly during their last stage of life. It means that the elderly men still have some certain level of testosterone in their blood and the treatment with YCJ may not work. However, YCJ may work in castrated men or hypogonadism men, who have very low level of testosterone.

Estrogenic compounds express their activities by binding to different estrogen receptors (ERs), ER α and ER β . ER α dominates in a few specific tissues whereas ER β is expressed in other tissues including bone (Gustafsson, 1999). While endogenous or exogenous estrogens are specific to ER α rather than to ER β , YCJ presumably containing phytoestrogen reacts specifically with ER β rather than ER α (Kuiper *et al.*, 1998; Sayoh *et al.*, 2008; 2011 submitted).

Subsequent studies on the immunochemistry of both ER receptors are needed to confirm this. Specific change patterns of other bone types: axial bones and long bones are being prepared for further investigations.

Conclusions

The novel data provided in this report demonstrates that biomarkers for osteoporosis in living animals can be influenced by compounds derived from a plant (namely YCJ) with possible estrogen-like ingredients. Based on the available data from this study, YCJ might be as effective for preventing bone loss caused by hormone deficiency as is hormone replacement therapy and might be a future alternative choice for treating osteoporosis in elderly or andropause men.

Conflict of Interest

The authors hereby declare that there is no conflict of interest related to this study.

Acknowledgements

Appreciation to B. Hodgson for his assistance with the English language. Special thanks to T. Nuntanarant and J. Jantaramano for their assistance with image analysis. This study was supported by the Department of Anatomy, Faculty of Science; Department of Conservative Dentistry, Faculty of Dentistry; and Nutraceutical and Functional Food Research and Development Center, Prince of Songkla University, Hat Yai, Thailand.

References

- Albertazzi, P. 2002. Clinical use of soy products. International congress series 1229, 189–193.
- Button, B. and Patel, N. 2004. Phytoestrogens for Osteoporosis. *Clinical Reviews in Bone and Mineral Metabolism*. 2, 341–356.
- Dervis, E. 2005. Oral implications of osteoporosis. *Oral Surgery, Oral Medicine, Oral Pathology, Oral Radiology, and Endodontology* 100, 349-356.
- Devareddy, L., Hooshmanda, S., Collins, J., Lucas, E., Chaia, B. and Arjmandi, B. 2008. Blueberry prevents bone loss in ovariectomized rat model of postmenopausal osteoporosis. *Journal of Nutritional Biochemistry*. 19, 694–699.
- Egermann, M., Goldhahn, J. and Schneider, E. 2005. Animal models for fracture treatment in osteoporosis. *Osteoporosis International*. 16, 129-138.
- Erben, R.G., Eberle, J., Stahr, K. and Goldberg, M. 2000. Androgen deficiency induces high turnover osteopenia in aged male rats: a sequential histomorphometric study. *Journal of Bone and Mineral Research*. 15, 1085-1098.
- Falahati-Nini, A., Riggs, B.L., Atkinson, E.J., O'Fallon, W.M.,

- Eastell, R. and Khosla, S. 2000. Relative contributions of testosterone and estrogen in regulating bone resorption and formation in normal elderly men. *Journal of Clinical Investigation*. 106, 1553-1560.
- Fanti, P., Monier-Faugere, M.C., Geng, Z., Schmidt, J., Morris, P.E., Cohen, D. and Malluche, H.H. 1998. The phytoestrogen genistein reduces bone loss in short-term ovariectomized rats. *Osteoporosis International*. 8, 274-81.
- Foundation National Osteoporosis. 2002. America's Bone Health: The state of osteoporosis and Low Bone Mass in our Nation National Osteoporosis Foundation.
- Furseth, K.R. 1996. The structure of the mandibular condyle in the monkey (*Macaca mulatta*). *Micron*. 27, 381-387.
- Gao, Y.H. and Yamaguchi, M. 1999. Anabolic effect of daidzein on cortical bone in tissue culture: comparison with genistein effect. *Molecular and Cellular Biochemistry*. 194, 93-97.
- Gunness, M. and Orwoll, E. 1995. Early induction of alterations in cancellous and cortical bone histology after orchidectomy in mature rats. *Journal of Bone and Mineral Research*. 10, 1735-1744.
- Gustafsson, J.A. 1999. Review: estrogen receptor- β a new dimension in estrogen mechanism of action. *Journal of Endocrinology*. 163, 379-383.
- Harkonen, P.L. and Makela, S.I. 2004. Role of estrogens in development of prostate cancer. *Journal of Steroid Biochemistry and Molecular Biology*. 92, 297-305.
- Havsteen, B.H. 2002. The biochemistry and medical significance of the flavonoids. *Pharmacology & Therapeutics*. 96, 67-202.
- Ishida, H., Uesugi, T., Hirai, K., Toda, T., Nukaya, H., Yokotsuka, K. and Tsuji, K. 1998. Preventive effects of the plant isoflavones, daidzin and genistin, bone loss in ovariectomized rats fed a calcium-deficient diet. *Biological & Pharmaceutical Bulletin*. 21, 62-66.
- Ishimi, Y., Arai, N., Wang, X., Wu, J., Umegaki, K., Miyaura, C., Takeda, A. and Ikegami, S. 2000. Difference in effective dosage of genistein on bone and uterus in ovariectomized mice. *Biochemical and Biophysical Research Communications*. 274, 697-701.
- Ishimi, Y., Yoshida, M., Wakimoto, S., Wu, J., Chiba, H., Wang X, Takeda, K. and Miyaura, C. 2002. Genistein, a soybean isoflavone, affects bone marrow lymphopoiesis and prevents bone loss in castrated male mice. *Bone*. 31, 180-185.
- Jafangiri, L., Kim, A. and Nishimura, I. 1997. Effect of ovariectomy on the local residual ridge remodeling. *Journal of Prosthetic Dentistry*. 77, 435-453.
- John, J.B.A. and Sanford C.G. 1997. The effects of phytoestrogens on bone. *Nutrition Research*. 17, 1617-1632.
- Kuiper, G.G., Lemmen, J.G., Carlsson, B., Corton, J.C., Safe, S.H., van der Saag, P.T., van der Burg, B. and Gustafsson, J.A. 1998. Interaction of estrogenic chemicals and phytoestrogens with estrogen receptor beta. *Endocrinology*. 139, 4252-4263.
- Lee, B. and White, S. 2005. Age and trabecular features of alveolar bone associated with osteoporosis. *Oral Surgery, Oral Medicine, Oral Pathology, Oral Radiology, and Endodontology*. 100, 92-98.
- Lerouxel, E., Libouban, H., Moreau, M.F., Basle, M.F., Audran, M. and Chappard, D. 2004. Mandibular bone loss in an animal model of male osteoporosis (orchidectomized rat): a radiographic and densitometric study. *Osteoporosis International*. 15, 814-819.
- Mercier, P. and Inoue, S. 1981. Bone density and serum minerals in cases of residual alveolar ridge atrophy. *Journal of Prosthetic Dentistry*. 46, 250-255.
- Moghadasian, M.H. 2000. Pharmacological properties of plant sterols. In vivo and in vitro observations. *Life Science*. 67, 605-615.
- Mohajery, M. and Brooks, S.L. 1988. Oral radiographs in the detection of early signs of osteoporosis. *Oral Surgery, Oral Medicine, Oral Pathology, Oral Radiology, and Endodontology*. 73, 112-117.
- Ockrim, J.L., Lalani, E.N., Laniado, M.E., Carter, S.St.C. and Abel, P.D. 2003. Transdermal estradiol therapy for advanced prostate cancer forward to the past. *Journal of Urology*. 169, 1735-1737.
- Parfitt, A.M. 1988. Bone remodeling: Relationship to the amount and structure of bone, and the pathogenesis and prevention of fractures. In Riggs B.L. and Melton L.J. III, editors, *Osteoporosis: Etiology, Diagnosis, and Management*. Raven Press, New York, N.Y., U.S.A., pp. 45-99.
- Parfitt, A.M., Drezner, M.K., Glorieux, F.H., Kanis, J.A., Malluche, H., Meunier, P.J., Ott, S.M. and Recker, R.R. 1987. Bone histomorphometry: Standardization of nomenclature, symbols, and units. Report of ASBMR Histomorphometry Committee. *Journal of Bone and Mineral Research*. 2, 595-610.
- Picherit, C., Coxam, V., Bennetau-Pelissero, C., Kati-Coulibaly, S., Davicco, M.J., Lebecque, P. and Barlet, J.P. 2000. Daidzein is more efficient than genistein in preventing ovariectomy-induced bone loss in rats. *Journal of Nutrition*. 130, 1675-1681.
- Pongchaiyakul, C., Apinyanurag, C., Soontrapa, S., Soontrapa, S., Pongchaiyakul, C., Nguyen, T.V. and Rajatanawin, R. 2006. Prevalence of Osteoporosis in Thai Men. *Journal of the Medical Association of Thailand*. 89, 160-169.
- Prakasam, G., Yeh, J.K., Chen, M.M., Castro-Magana, M., Liang, C.T. and Aloia, J.F. 1999. Effects of growth hormone and testosterone on cortical bone formation and bone density in aged orchidectomized rats. *Bone*. 24, 491-497.
- Punghmatharith, B. 1988. Sex hormone-like substances in young coconut juice and their effects on uterine growth in rats. *Songklanakarin Journal of Science and Technology*. 10, 221-226.
- Radenahmad, N., Saleh, F., Sawangjaroen, K., Rundornm, W., Withyachumnarnkul, B. and Connor, R.J. 2009. Young

- coconut juice significantly reduces histopathological changes in the brain that is induced by hormonal imbalance: A possible implication to postmenopausal women. *Histology and Histopathology: Cellular and Molecular Biology*. 24, 667-674.
- Radenahmad, N., Vongvatcharanon, U., Withyachumnarnkul, B. and James, R.C. 2006. Serum level of 17 β -estradiol in ovariectomized rats fed young-coconut-juice and its effect on wound healing. *Songklanakarin Journal of Science and Technology*. 28(5), 897-910.
- Sayoh, I., Radenahmad, N., Sawangjaroen, K., Subhadhira-sakul, P., Boonyang, P., Rundurm, W. and Mitranun, W. 2008. Histopathological assessment of young coconut juice on cutaneous wound healing of ovariectomized rats. *Proceeding of 31th Annual Conference of the Anatomy Association of Thailand 2008*. Pethburi, Thailand, April 30-May 2, 2008, 62-66.
- Sayoh, I., Radenahmad, N., Sawangjaroen, K., Subhadhira-sakul, P., Boonyoung, P., Rundorn, W. and Mitranun, W. 2011. Effects of young coconut juice on the cutaneous healing of female rat wounds. (submitted).
- Soronen, P., Laiti, M., Torn, S. Harkonen, L., Patrikainen, Y., Li, A., Pulkka, R., Kurkela, A., Herrala, H., Kaija, V., Isomaa, V. and Vihko, P. 2004. Sex steroid hormone metabolism and prostate cancer. *Journal of Steroid Biochemistry and Molecular Biology*. 92, 281-286.
- Spilkova, J. and Hubik, J. 1992. The biological actions of flavonoids. II. *Pharmazie in unserer Zeit*. 2, 174-182.
- Tanaka, M., Ejiri, S., Toyooka, E., Kohno, S. and Ozawa, H. 2002. Effects of ovariectomy on trabecular structures of rat alveolar bone. *Journal of Periodontal Research*. 37, 161-165.
- Turner, R.T., Hannon, K.S., Demers, L.M., Buchanan, J. and Bell, N.H. 1989. Differential effects of gonadal function on bone histomorphometry in male and female rats. *Journal of Bone and Mineral Research*. 4, 557-563.
- Urasopon, N., Hamada, Y., Asaoka, K., Cherdshewasart, W. and Malaivijitnond, S. 2007. *Pueraria mirifica*, a phytoestrogen-rich herb, prevents bone loss in orchidectomized rats. *Maturitas*. 56, 322-331.
- Wang, X., Wu, J., Chiba, H., Yamada, H. and Ishimi, Y. 2003. *Puerariae radix* prevents bone loss in ovariectomized mice. *Journal of Bone and Mineral Metabolism*. 21, 268-275.
- Wang, X., Wu, J., Chiba, H., Yamada, H. and Ishimi, Y. 2005. *Puerariae radix* prevents bone loss in castrated male mice. *Metabolism Clinical and Experimental*. 54, 1536-1554.
- White, S.C. and Rudolph, D.J. 1999. Alterations of the trabecular pattern of the jaws in patients with osteoporosis. *Oral Surgery, Oral Medicine, Oral Pathology, Oral Radiology, and Endodontology*. 88, 628-635.
- Yang, J., Pham, S.M. and Crabbe, D.L. 2003. Effects of estrogen deficiency on rat mandibular and tibial micro-architecture. *Dentomaxillofacial Radiology*. 32, 247-251.
- Yusuh, M., Phochanukoon, N., Radenahmad, N., Eksomtramate, M., Ruangsri, P., Chantanasuksilpa, A., Niti-ruangjaras, A. 2010. Changes of condyle cartilage in orchidectomized rats fed with young coconut juice: Novel preliminary findings. *Songklanakarin Journal of Science and Technology*. 32(4), 333-339.