

SEBORRHEIC DERMATITIS EYE LID INVOLVEMENT (SEBORRHEIC BLEPHARITIS) IN CHILDREN NOT A RARE CLINICAL OBSERVATION

ŁOJOTOKOWE ZAPALENIE SKÓRY POWIEK (SEBORRHEIC
BLEPHARITIS), NIE RZADKIE OBSERWACJE U DZIECI

Anca Chiriac¹, Anca E. Chiriac², Alina Murgu³, Liliana Foia⁴

¹*CMI Dermatology, Iasi-Romania*

²*Univ. of Medicine Gr T Popa Iasi-Romania*

³*Univ. Hospital of Pediatrics Sf Maria, Iasi, Romania*

⁴*Univ. of Medicine Gr T Popa, Biochemistry Department, Iasi-Romania*

Corresponding author: Anca Chiriac, MD, PhD

ancachiriac@yahoo.com

Our Dermatol Online. 2012; 3(1): 52-53

Date of submission: 01.11.2011 / acceptance: 21.11.2011

Conflicts of interest: None

Abstract

We present a typical case of seborrheic dermatitis, with no cutaneous manifestations, rarely reported in children, frequently misdiagnosed (especially by ophthalmologists), simply confirmed by microscopic examination of scales and with wonderful therapeutic results with antifungal agents (topical and/or systemic treatments).

Streszczenie

Prezentujemy typowy przypadek łojotokowego zapalenia skóry, bez skórnej manifestacji zmian, rzadko opisywany u dzieci, często błędnie diagnozowany (zwłaszcza przez okulistów), łatwo potwierdzony przez badanie mikroskopowe i dający wspaniałe wyniki leczenia po zastosowaniu leków przeciwgrzybiczych (miejscowych i / lub systemowych).

Key words: seborrheic dermatitis; *Malasezia* spp; Ketoconazole

Słowa kluczowe: seborrheic dermatitis; *Malasezia* spp; Ketoconazol

Introduction

Seborrheic dermatitis is a chronic inflammatory disease that mainly affects seborrheic areas of skin. An inflammatory response to the yeast *Pityrosporum ovale* has been thought to be important in the etiology of the condition. Not very rare, especially in children, there is a seborrheic blepharitis, often misdiagnosed. We present a case of a child with typical eye lid involvement of seborrheic dermatitis without skin manifestations.

Case Report

A 5-year-old boy, with no significant past medical history, presented with a 1-year history of mild erythema, scaling and pruritus on the eye lid, without any other manifestations on the skin and ocular area. He was in very good health state, with no medication and without an allergy history.

He has received many different medications so far: antibiotics (Oxacillin, Metronidazole), antihistamines, topical corticosteroids, with no improvement.

We diagnosed him with seborrheic blepharitis, he received Ketoconazole orally 10 days and topical imidazole, with complete disappearance of the lesions.

The diagnosis was confirmed with microscopic examination of scales soaked in 10%-15% potassium hydroxide (KOH): characteristic thick-walled spherical or oval yeast forms and coarse septate mycelium, often broken up into short filaments.

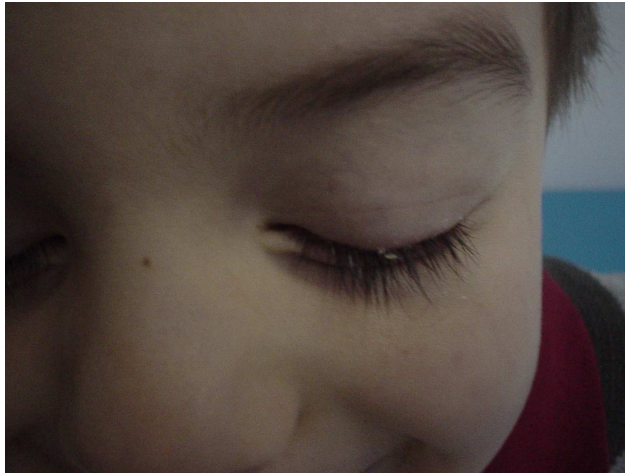


Figure 1. Discrete scaling on the eyelid margin

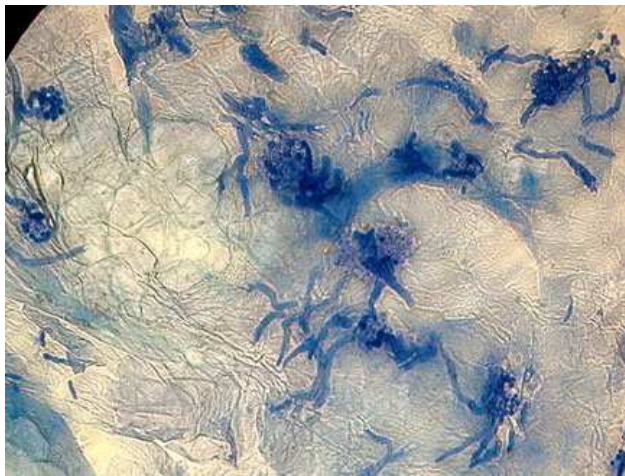


Figure 3. Clear adhesive tape were pressed to collect hyphae and spores. The tape was then lightly pressed onto a glass slide, and a drop of methylene blue was placed at the edge of the tape. The spores and hyphae easily are seen against a background cluster of keratinocytes and glue

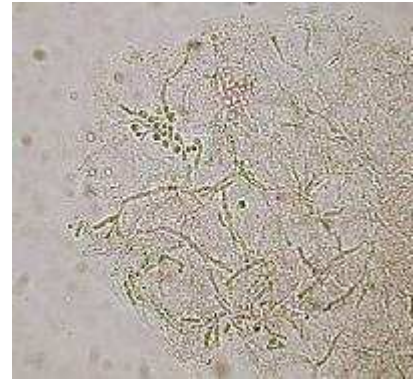

Figure 2. Combination of mycelium strands and numerous spores is commonly referred to as "spaghetti and meatballs"

Discussion

Blepharitis is a chronic inflammatory process of the eyelid margin. It is a common eye disorder throughout the world and can affect any age group.

Common symptoms associated with blepharitis are burning sensation, irritation, tearing, photophobia, blurred vision and red eyes. Seborrheic blepharitis is rarely reported, especially in children, although we believe it is misdiagnosed.

Although the pathophysiology of seborrheic blepharitis is not completely understood, correlation of flares with proliferation of *Malassezia species (spp)* and clinical response to antifungal agents (i.e., ketoconazole, ciclopirox) have led many researchers and clinicians to believe that *Malassezia spp* play a role in its pathogenesis.

The frequency of bathing, use of skin care products, lubricants and use of any occlusive agents have all been associated with colonization of infantile skin with *Malassezia spp*.

We describe a very subtle clinical aspect of seborrheic blepharitis, with a great impact on normal life of a child, despite its minimal manifestations, with very simple treatment and an overlooked diagnosis.

REFERENCES

1. Folia Zisova LG: Folia Medica Treatment of malassezia species associated seborrheic blepharitis with fluconazole (Plovdiv). 2009; 51: 57-9.
2. Bernardes TF, Bonfioli AA: Blepharitis, Seminars in Ophthalmology. 2010; 25: 79-83.
3. Bruce Sylvester: Ketoconazole 2% foam effective and safe for Seborrheic Dermatitis: Presented at AAD meeting 2009.