



## Bone bruise of the knee associated with the lesions of anterior cruciate ligament and menisci on magnetic resonance imaging

Koštana modrica na kolenu udružena sa lezijama prednje ukrštene veze i meniskusa na snimku magnetnom rezonancom

Djordje Jelić\*, Dragan Mašulović†

Diagnostic Imaging Center „Eurodijagnostika“, Belgrade, Serbia;

†Clinical Center Serbia, Institute of Radiology, Belgrade Serbia

### Abstract

**Background/Aim.** Bone bruise is a common finding in acutely injured knee examined by magnetic resonance (MR). The aim of the study was to determine the association of bone bruise frequency with postinjury lesions of anterior cruciate ligament (ACL) and menisci. Bone bruise involves post-traumatic bone marrow change with hemorrhages, edema and microtrabecular fractures without disruption of adjacent cortices or articular cartilage. MR imaging is a method of choice for detecting bone bruises which can not be seen on conventional radiographic techniques. **Methods.** A representative review of 120 MR examinations for the acute knee trauma was conducted. All the patients were examined within one month of trauma. All MR examinations were performed by using a 0.3T MR unit. **Results.** Posttraumatic bone bruise was seen in 39 (32.5%) patients out of 120. Three patients had fracture of the cortex, so-called “occult” fracture (not seen on plain radiography). We analyzed only bone bruises without these fractures of the cortex. Bone bruise was associated with the lesion of ACL in 27 (69%) patients. In 28 (72%) patients bone bruise was in combination with the lesion of menisci. Only two patients with bone bruise had neither ACL nor menisci lesions. There were 78 patients without bone bruise but 33 (43%) of them had lesions of ACL and 49 (63%) had lesions of menisci. **Conclusion.** Bone bruise is best seen in STIR (Short TI Inversion Recovery) images and is very often found in acute knee trauma. Very often it is associated with posttraumatic lesions of ACL and menisci, so attention must be paid to this when bone bruise is seen. The difference in frequency of internal structures of the knee lesions in patients with bone bruise is highly statistically significant as compared to patients with no bone bruise.

### Key words:

knee injuries; bone and bones; contusions; magnetic resonance imaging; sensitivity and specificity.

### Apstrakt

**Uvod/Cilj.** Koštana modrica predstavlja uobičajen nalaz kod akutne povrede kolena na magnetnoj rezonanci (MR). Cilj rada bio je da se proceni stepen udruženosti koštane modrice (KM) sa posttraumatskim lezijama prednje ukrštene veze (*ligamentum cruciatum anterior* – LCA) i meniskusa. Koštana modrica je posttraumatska promena koštane srži koja je posledica kombinacije hemoragije, edema i mikrotrabekularne frakture bez prekida kontinuiteta korteksa. Magnetna rezonanca je metoda izbora za prikazivanje koštanih modrica koje se ostalim radiološkim metodama ne mogu prikazati. **Metode.** Magnetnom rezonancom pregledano je 120 bolesnika sa akutnom traumom kolena. Svi bolesnici pregledani su u prvih mesec dana nakon traume. Pregledi su obavljani na 0,3T MR aparatu. **Rezultati.** Posttraumatska KM viđena je kod 39 (32,5%) bolesnika od ukupno 120. Kod tri bolesnika uočeno je prisustvo i frakture korteksa, takozvana okultna fraktura koja nije uočena na radiografiji. Analizirali smo samo čiste koštane modrice bez frakture korteksa. Nalaz KM bio je u kombinaciji sa lezijom LCA kod 27 (69%) bolesnika. Kod 28 (72%) bolesnika KM je bila u kombinaciji sa lezijom meniskusa. Kod dva bolesnika nalaz KM bio je bez patološkog nalaza na LCA i meniskusima. Bez KM bilo je 78 bolesnika, ali njih 33 (43%) imalo je lezije LCA, a 49 (63%) lezije meniskusa. **Zaključak.** Koštana modrica najbolje se uočava u *Short TI Inversion Recovery* (STIR) sekvenci i čest je nalaz kod akutne traume kolena. Veoma često je udružena sa posttraumatskim lezijama LCA i meniskusa, pa na njih posebno treba obratiti pažnju pri pregledu sa nalazom KM kolena. Razlika učestalosti lezija unutrašnjih struktura kolena kod bolesnika sa nalazom KM je statistički visokoznačajna u odnosu na bolesnike bez nalaza KM.

### Ključne reči:

koleno, povrede; kost; kontuzije; magnetna rezonanca, snimanje; osetljivost i specifičnost.

## Introduction

Bone bruise is a common finding in acutely injured knee examined by magnetic resonance (MR). Bone bruise is post-traumatic bone marrow change which is caused by the combination of hemorrhage, edema and microtrabecular fracture without disruption of adjacent cortex. Magnetic resonance imaging is a method of choice for detecting bone bruises which usually can not be seen using other radiological methods<sup>1</sup>. The terms: bone bruise, bone contusion and posttraumatic edema of the bone marrow have been seen for the last ten years in scientific literature and are in fact synonyms in the case of posttraumatic findings of bone marrow contusion. It must be emphasized however that edema of the bone marrow is not specific and that it can be present not only in trauma but also in infection, ischemia, migratory osteoporosis, early osteonecrosis, as a reaction to a neoplasm or even it can be idiopathic<sup>2-5</sup>. Sensitivity of MR imaging for detecting bone bruise of the knee is 83%–96% and specificity is 86%–96%<sup>6</sup>. Bone bruise of the knee is very important as a reason for acute pain and reduced knee function in patients<sup>7,8</sup>. Precise analysis of bone bruise location can explain the injury pattern which enables better insight in associated lesions of the internal knee structures<sup>9-11</sup>. Magnetic resonance findings show decreased signal intensity in T1 sequence, increased in T2 sequence and hyperintensity of the signal in STIR (Short T1 Inversion Recovery) sequence. Bone bruise is best seen in STIR sequence. The aim of this study was to evaluate the diagnostic power of MR in detecting bone bruise of the knee and to show the association anterior cruciate ligament (ACL) and menisci lesions with bone bruise of the knee.

## Methods

Magnetic resonance imaging of the knee was performed in 120 patients with the acute trauma. All the patients were examined within one month of the trauma. There were 88 (73%) male patients and 32 (27%) women, average age 31 years. All scans were performed by using 0.3T MR with SE T1W1, FS T2W1 and STIR.

On MR imaging bone bruise is characterized by focal abnormal signal of the bone marrow of femoral condyles or tibial plateau. On T1 weighted images the alterations in signal are characterized by ill-defined low signal intensity. On T2-weighted images these lesions are characterized by areas of high signal intensity. Bone bruise is best differentiated in STIR sequence where the signal of bone marrow fat is significantly suppressed while there is a bright, hyperintense signal of bone bruise.

The meniscal tear is diagnosed as linear or irregular hyperintense signal which can be spread to the margins of hypointense meniscal triangle.

Anterior cruciate ligament injuries are characterized by a low signal intensity on T1-weighted images and hyperintensity of the signal on T2-weighted images. A complete rupture of the ACL is diagnosed when there is a complete lack of the fibers on the ligament spread and the partial rupture when there are some fibers left intact.

For the statistical analysis of the results we used descriptive statistical methods and the Mc Nemar test for the evaluation of statistical significance between the patients with and without bone bruise.

## Results

Bone bruise was seen in 39 (33%) out of 120 patients who had been submitted to MR imaging. In 15 patients bone bruise was located on femoral condyles. Out of these 15 patients, in 13 patients bone bruise was on lateral femoral condyle and in 2 patients on medial femoral condyle (Figure 1a–c). In 11 (28%) patients bone bruise was located on tibial plateau; 7 (18%) patients had both bone bruise on femur and tibia, so-called kissing bone bruises and among them 5 (71%) patients had them in lateral compartment and 2 (29%) patients in medial compartment; 5 (13%) patients had three or more bone bruises and among them 3 patients had them in lateral compartment and 2 in medial (Figure 2).

Overall, bone bruises were more often seen in the lateral than in the medial compartment.

Bone bruise was associated with LCA injury in 27 (69%) patients: more than two thirds of the patients (72%) had lesions of menisci. Out of 28 patients, 4 (14%) patients had lesion of the lateral meniscus, 15 (54%) patients had medial meniscal lesion and 9 (32%) patients had lesions of both menisci; 19 patients or almost half of patients with bone bruise had a combination of bone bruise, ACL and menisci lesions. Only in 2 (5%) patients bone bruise was identified without ACL or menisci pathology (Table 1).

In 3 patients, so-called occult fractures (not seen on plain radiography) were diagnosed.

A total of 78 (65%) patients or of examined patients had no bone bruise while 33 (43%) patients of these 78, had ACL lesion, 49 (63%) patients had menisci lesion, 13 (26%) patients on lateral menisci and 25 (51%) on medial and 10 patients on both menisci.

The differences between the incidence of LCA and lesions of menisci between the patients with and without bone bruise were highly statistically significant ( $p < 0.005$ ) (Table 2).

## Discussion

Bone bruise, as a unique entity on MR, was first identified by Mink et al<sup>12</sup> in 1987. Few years later, bone bruises and occult fractures were divided<sup>13</sup>. Occult fractures usually can not be seen on conventional radiography but have MR characteristics very similar to those of bone bruises with one major difference and that is a disruption of adjacent cortex or osteochondral surface. Conventional radiological techniques are rather limited in showing bone marrow. Because of that, analysis of bone marrow characteristics especially bone bruises, is based on MR imaging. Normal intensity signal of bone marrow is the same as the signal of subcutaneous fat. It is hyperintense on T1-weighted images and medium intense on T2-weighted images. Bone bruise on MR is presented as focal abnormal signal of the bone marrow of the femoral condyles or tibial plateaus. It is seen as a reduction of signal

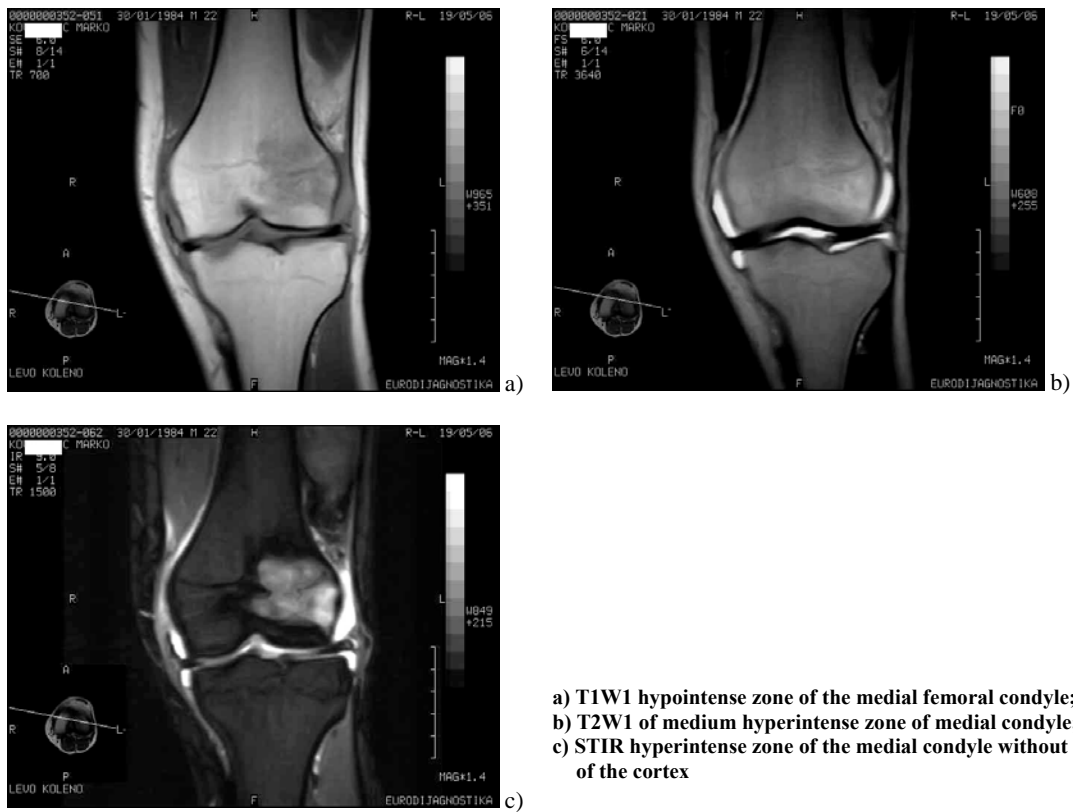


Fig. 1 – Extensive bone bruise of the medial femoral condyle

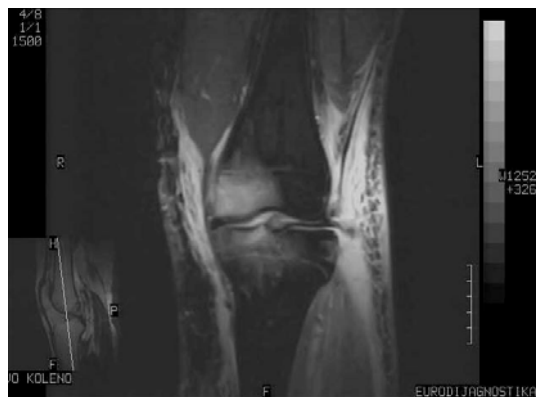


Fig. 2 – Kissing contusion of the medial condyle and medial tibial plateau with smaller subcortical bone bruise on the lateral edge of the lateral tibial plateau on STIR sequence

Table 1

Distribution of internal knee structure abnormalities in patients with bone bruise

Localization	Bone bruise (n = 39)	Localization of the internal knee structure abnormalities (n)				
		ACL (n = 27)	Men (n = 28)	BMen (n = 9)	MMen (n = 15)	LMen (n = 4)
Femur	15	7	10	2	6	2
LCon	13	6	8	2	4	2
MCon	2	1	2	0	2	0
Kissing BB	7	6	5	1	3	1
LKiss	5	4	3	1	1	1
MKiss	2	2	2	0	2	0
Tibia	11	9	9	4	5	0
LPla	7	5	5	2	3	0
MPla	4	4	4	2	2	0
Three and more BB	5	5	4	2	1	1
Mlat	3	3	2	1	1	0
MMed	2	2	2	1	0	1

BB – bone bruise; ACL – anterior cruciate ligament; Men – meniscus; BMen – Both menisci; MMen – Medial meniscus; LMen – lateral meniscus; LCon – lateral condyle; MCon – medial condyle; LKiss – lateral kissing bone bruise; MKiss – medial kissing bone bruise; LPla – lateral tibial plateau; MPla – medial tibial plateau; MMed – more medial bone bruise; Mlat – more lateral bone bruise

Table 2

## Intraarticular abnormalities in patients with and without bone bruise (BB)

Intraarticular abnormalities	Without BB n (%)	With BB n (%)	<i>p</i>
Total number of patients	78 (100)	39 (100)	<i>p</i> < 0.005
Lesion of menisci or ACL	56 (71.8)	37 (94.9)	<i>p</i> < 0.005
Medial meniscus	25 (32)	15 (38.5)	<i>p</i> < 0.005
Lateral meniscus	13 (16.7)	4 (10)	<i>p</i> < 0.005
Both menisci	10 (12.7)	9 (23)	<i>p</i> < 0.005
ACL	33 (42.2)	27 (69.1)	<i>p</i> < 0.005
ACL with lesion of menisci	28 (35.9)	19 (48.7)	<i>p</i> < 0.005

ACL – anterior cruciate ligament

intensity on T1-weighted images and augmentation of signal intensity on T2-weighted images. The best appearance of bone bruise is described on STIR sequence where the signal of normal bone marrow is suppressed and bone bruise is characterized by the hyperintensity of the signal. This change in signal intensity is caused by posttraumatic edema which is one of the major pathohistological features of bone bruise. The two others are hemorrhage and microtrabecular fracture. Owing to these pathohistological features, it is considered that bone bruise is one of the causes of a painful knee. Owing to the pathohistological analysis of bone bruise, different degrees of subchondral and articular cartilage changes can be observed<sup>13,14</sup>. Pathogenesis of bone marrow edema which is characteristic for bone bruise is connected with acute or chronic knee injuries, but bone bruises can be seen with no obvious trauma. Bone bruise of the knee usually lasts 12–14 weeks, which is much more than previously thought<sup>15</sup> and sometimes can even be seen up to one year after trauma<sup>16</sup>. Bone bruises associated with posttraumatic lesions of the internal knee structures last more than isolated bone bruises<sup>17</sup>. In the overlying cartilage, degenerative changes including necrosis are described, whereas loss of proteoglycans and different degrees of osteocyte necrosis was seen in the bone matrix. These findings are the basis for further research in the field of late complications of bone bruises such as posttraumatic arthritis<sup>18</sup>. Latest studies show that bone marrow edema seen on MR imaging is a result of different atypical histological changes and that intensity of the signal does not depend only on bone marrow edema<sup>19</sup>. The main finding in bone bruise is posttraumatic edema which is most responsible for signal intensity.

Location and size of bone bruise usually speak for the mechanism of knee injury. Analysis of the force direction can be helpful in analyzing and describing associated knee lesions<sup>9–11</sup>. There are five different mechanisms of knee trauma which give different patterns of bone marrow edema and they are: pivot shift injury, dashboard injury, hyperextension injury, clip injury, and lateral patellar dislocation.

There have not been many studies which analyze the incidence of bone bruises following knee injury<sup>10,20,21</sup>. Some of them show the incidence of 20%<sup>22</sup> and some up to 27%<sup>21</sup>. In our study 33% of the patients with knee trauma had bone bruise. Our study was designed so to analyze the presence of bone bruise in acute knee trauma as well as the association with internal knee lesions of LCA and menisci. We analyzed combined posttraumatic lesions of bone mar-

row, LCA and menisci as very important for acute clinical features and late complications such as osteoarthritis.

In our study the association of bone bruise with injury of LCA was seen in 69% of the patients, similar as in study reported by Davis et al.<sup>15</sup>, where they found this association in 67%. This study is very important because MR of the knee was done twice in order to confirm diagnosis. In the study of Lynch et al.<sup>22</sup>, bone bruise incidence was 20% and the association with LCA rupture was seen in 77% of the patients. The highest association of bone bruise with LCA rupture was seen in study of Atkinson et al.<sup>17</sup> and it was 78%. The term LCA injury is used because in our study we had no arthroscopy done in our patients in order to distinguish partial from a complete rupture of the anterior cruciate ligament. Under the term “menisci injury” or “menisci lesion” we consider all pathological posttraumatic MR findings such as traumatic tears as well as degenerative posttraumatic changes without grading menisci degeneration in three degrees (degree 1, 2, 3). In our study the association of bone bruise with menisci lesions was observed in 72% of the patients. It is very important to emphasize that in acute knee injury it is very hard to distinguish traumatic menisci tears from the degenerative ones which was not the aim of our study.

Cothran et al.<sup>23</sup> were the first to introduce the MR characteristics of posttraumatic contusion menisci lesions. It is therefore essential to consider menisci lesions not only as a cause of a painful knee and a diminished knee function but also as a predictor of further osteoarthritis<sup>24</sup>. There have been many studies with the aim to confirm the associations of bone bruise and LCA lesions. Almost all analyzed this association but placing LCA as primary outcome for the study. There have been fewer studies which analyze the association of bone bruises and menisci lesions<sup>17,25</sup>. Our study analyzed both the association of bone bruise and the internal knee structures lesions but placing bone bruise finding as primary.

### Conclusion

Bone bruise is a very common finding in acute knee injury. It is more often on the lateral knee compartment. In acutely injured knee, bone bruise can indicate the injury pattern and it can be very helpful in detecting associated posttraumatic internal knee lesions. By the precise analysis of bone bruise and the pattern of bone injury we can focus on analysis of internal knee structures lesions. The golden stan-

dard for visualizing posttraumatic contusion knee lesion on MR is the STIR sequence. In this way finding of bone bruise on MR leads to finding the expected but less well seen le-

sions of internal structures of the knee. Patients with bone bruise have significantly more lesions of LCA and menisci than patients without bone bruise.

## R E F E R E N C E S

1. *Kijowski R, Blankenbaker DG, Klaers JL, Shinki K, De Smet AA, Block WF.* Vastly undersampled isotropic projection steady-state free precession imaging of the knee: diagnostic performance compared with conventional MR. *Radiology* 2009; 251(1): 185–94.
2. *Fowkes LA, Toms AP.* Bone marrow oedema of the knee. *Knee* 2010; 17(1): 1–6.
3. *Hofmann S, Kramer J, Breitenseher M, Pietsch M, Aigner N.* Bone marrow edema in the knee. Differential diagnosis and therapeutic possibilities. *Orthopade* 2006; 35(4): 463–75. (German)
4. *Fotiadou A, Karantanas A.* Acute nontraumatic adult knee pain: the role of MR imaging. *Radiol Med* 2009; 114(3): 437–47.
5. *Li X, Ma BC, Bolbos RI, Stahl R, Lozano J, Zuo J, et al.* Quantitative assessment of bone marrow edema-like lesion and overlying cartilage in knees with osteoarthritis and anterior cruciate ligament tear using MR imaging and spectroscopic imaging at 3 Tesla. *J Magn Reson Imaging* 2008; 28(2): 453–61.
6. *Arndt WF 3rd, Truax AL, Barnett FM, Simmons GE, Brown DC.* MR diagnosis of bone contusions of the knee: comparison of coronal T2-weighted fast spin-echo with fat saturation and fast spin-echo STIR images with conventional STIR images. *AJR Am J Roentgenol* 1996; 166(1): 119–24.
7. *Vincken PW, Ter Braak BP, van Erkel AR, Coerkamp EG, Malens WM, Bloem JL.* Clinical consequences of bone bruise around the knee. *Eur Radiol* 2006; 16(1): 97–107.
8. *Aigner N, Meizer R, Meraner D, Becker S, Radda C, Landsiedl F.* Tapping test in patients with painful bone marrow edema of the knee. *Clin J Pain* 2008; 24(2): 131–4.
9. *Sanders TG, Medynski MA, Feller JF, Lawhorn KW.* Bone contusion patterns of the knee at MR imaging: footprint of the mechanism of injury. *Radiographics* 2000; 20(Suppl 1): S135–51.
10. *Sanders TG, Paruchuri NB, Zlatkin MB.* MRI of osteochondral defects of the lateral femoral condyle: incidence and pattern of injury after transient lateral dislocation of the patella. *AJR Am J Roentgenol* 2006; 187(5): 1332–7.
11. *Viskontas DG, Giuffre BM, Duggal N, Graham D, Parker D, Coolican M.* Bone bruises associated with ACL rupture: correlation with injury mechanism. *Am J Sports Med* 2008; 36(5): 927–33.
12. *Mink JH, Reicher MA, Crues IH.* Magnetic resonance imaging of the knee. New York: Raven; 1987.
13. *Vellet AD, Marks PH, Fowler PJ, Munro TG.* Occult posttraumatic osteochondral lesions of the knee: prevalence, classification, and short-term sequelae evaluated with MR imaging. *Radiology* 1991; 178(1): 271–6.
14. *Davies NH, Niall D, King LJ, Lavelle J, Healy JC.* Magnetic resonance imaging of bone bruising in the acutely injured knee—short-term outcome. *Clin Radiol* 2004; 59(5): 439–45.
15. *Mandalia V, Fogg AJ, Chari R, Murray J, Beale A, Henson JH.* Bone bruising of the knee. *Clin. Radiol* 2005; 60(6): 627–36.
16. *Frobell RB, Le Graverand MP, Buck R, Roos EM, Roos HP, Tamez-Pena J, et al.* The acutely ACL injured knee assessed by MRI: changes in joint fluid, bone marrow lesions, and cartilage during the first year. *Osteoarthritis Cartilage* 2009; 17(2): 161–7.
17. *Atkinson PJ, Cooper TG, Anseth S, Walter NE, Kargus R, Haut RC.* Association of knee bone bruise frequency with time postinjury and type of soft tissue injury. *Orthopedics* 2008; 31(5): 440.
18. *Felson DT, McLaughlin S, Goggins J, LaValley MP, Gale ME, Toteraman S, et al.* Bone marrow edema and its relation to progression of knee osteoarthritis. *Ann Intern Med* 2003; 139(5 Pt 1): 330–6.
19. *Zanetti M, Bruder E, Romero J, Hodler J.* Bone marrow edema pattern in osteoarthritic knees: correlation between MR imaging and histologic findings. *Radiology* 2000; 215(3): 835–40.
20. *Roemer FW, Frobell R, Hunter DJ, Crema MD, Fischer W, Bohndorf K, et al.* MRI-detected subchondral bone marrow signal alterations of the knee joint: terminology, imaging appearance, relevance and radiological differential diagnosis. *Osteoarthritis Cartilage* 2009; 17(9): 1115–31.
21. *Terzidis IP, Christodoulou AG, Ploumis AL, Metsovitis SR, Koimtzis M, Givissis P.* The appearance of kissing contusion in the acutely injured knee in the athletes. *Br J Sports Med* 2004; 38(5): 592–6.
22. *Lynch TC, Crues JV 3rd, Morgan FW, Sheehan WE, Harter LP, Ryu R.* Bone abnormalities of the knee: prevalence and significance at MR imaging. *Radiology* 1989; 171(3): 761–6.
23. *Cottrill RL Jr, Major NM, Helms CA, Higgins LD.* MR imaging of meniscal contusion in the knee. *AJR Am J Roentgenol* 2001; 177(5): 1189–92.
24. *Berthiaume MJ, Raynauld JP, Martel-Pelletier J, Labonté F, Beaudoin G, Bloch DA, et al.* Meniscal tear and extrusion are strongly associated with progression of symptomatic knee osteoarthritis as assessed by quantitative magnetic resonance imaging. *Ann Rheum Dis* 2005; 64(4): 556–63.
25. *Bergin D, Hochberg H, Zoga AC, Qazi N, Parker L, Morrison WB.* Indirect soft-tissue and osseous signs on knee MRI of surgically proven meniscal tears. *AJR Am J Roentgenol* 2008; 191(1): 86–92.

Received on February 1, 2010.

Revised on November 15, 2010.

Accepted on November 16, 2010.