



Monosomy 12 and deletion of 13q34 in a case of chronic lymphocytic leukemia with concomitant lung cancer

Monozomija 12 i delecija 13q34 kod bolesnika sa hroničnom limfocitnom leukemijom i istovremenim karcinomom pluća

Darko Antić, Marija Denčić-Fekete, Dragica Tomin, Irena Djunić

Clinical Center of Serbia, Clinic for Hematology, Belgrade, Serbia

Abstract

Background. We described a patient with chronic lymphocytic leukemia (CLL) and lung cancer and unusual chromosomal aberrations. **Case report.** At the same time with the diagnosis of B-cell CLL, squamocellular lung carcinoma diagnosis was established. Using interphase fluorescence *in situ* hybridization technique (FISH) we detected monosomy 12 and deletion of 13q34 occurred in the same clone. One month after the beginning of examination the patient died unexpectedly during sleep immediately before we applied a specific treatment for CLL or lung carcinoma. **Conclusion.** Simultaneous occurrence of monosomy 12 and deletion of 13q34 in a patient with B-cell CLL has been described only once before, but as a part of a complex karyotype. The prognostic significance of these abnormalities remains uncertain.

Key words:

leukemia, lymphocytic, chronic, b-cell; lung neoplasms; chromosome aberrations.

Apstrakt

Uvod. U ovom radu opisali smo slučaj bolesnika sa B-ćelijskom hroničnom limfocitnom leukemijom (HLL) i karcinomom pluća kod koga je detektovana neuobičajena hromozomska abnormalnost. **Prikaz bolesnika.** U isto vreme, kada je kod bolesnika postavljena dijagnoza HLL, dijagnostikovana je i skvamocelularan karcinom pluća. Korišćenjem tehnike fluorescentne *in situ* hibridizacije (FISH) dokazano je postojanje monozomije 12 i delecije 13q34 u istom klonu. Mesec dana nakon početka ispitivanja bolesnik je iznenada umro u snu pre primene bilo kakvog terapijskog modaliteta. **Zaključak.** Simultana pojava monozomije 12 i delecije 13q34 kod bolesnika sa B-HLL do danas je objavljena samo jednom i to kao deo kompleksnog patološkog kariotipa. Prognostički značaj ovih aberacija još uvek je nepoznat.

Ključne reči:

leukemija, b-ćelije, hronična; pluća, neoplazme; hromosomi, aberacije.

Introduction

Chronic lymphocytic leukemia (CLL) is a disease with variable clinical course. While some patients die within a few months after diagnosis, others survive for more than a decade.

Clinical staging systems are widely used and have been proven to be of prognostic significance. Other independent prognostic parameters are the absolute peripheral blood lymphocyte count, lymphocyte doubling time, bone marrow histology and, not the least, the presence and the type of chromosomal abnormalities¹.

The most frequent aberrations are deletions in 13q, 11q, or 17p and trisomy 12. The detection of del 17p or del 11q is associated with poor risk, while del 13q as a sole abnormality is associated with good-risk disease^{2,3}.

Also, previous studies have indicated that patients with CLL have an increased risk of subsequent cancer, in particular cancers of the skin and lung⁴.

Case report

A 69-year old man, nonsmoker, presented a two-months history of fatigue and nocturnal sweating. Physical examination showed the presence of splenomegaly and cervical, axillary and inguinal lymphadenopathies. The blood count showed: hemoglobin 15.6 g/dL, platelets $143 \times 10^9/L$, white blood cells $160 \times 10^9/L$. The differential count showed neutrophils 3%, lymphocytes 96%, and monocytes 1%.

The diagnosis of CLL was confirmed by immunophenotypic analysis, performed on peripheral blood mononuclear cells, which demonstrated the expression of mature B-

cell markers (CD19, CD22), the coexpression of CD5 and CD23 and the absence of sIg, CD79b, FMC7 and CD38 expression. Cytogenetic study was performed on lymphoid cells from peripheral blood. Unfortunately, no metaphases were found on the prepared slides.

The bone marrow aspirate was hypercellular with 80% infiltration by small lymphocytes. Trephine biopsy showed a diffuse pattern of infiltration. According to Binet staging system the patient was considered in the stage B. Ultrasonography of the abdomen showed the enlarged spleen of 160 cm with the accessory spleen 1.9×1.7 cm. Chest X-ray and computed tomography (CT) of the chest showed infiltrate in the hilar region of the right lung associated to multiple lesions in the pulmonary parenchyma. Transbronchial lung biopsy was performed and the diagnosis of squamocellular lung carcinoma was established. One month after the beginning of examination the patient unexpectedly died during sleep immediately before we applied a specific treatment for CLL or lung carcinoma. Autopsy was not performed.

Conventional karyotyping was done on the peripheral blood cell chromosome preparations by standard cytogenetic techniques. This included overnight culture of cells in RPMI 1640 medium supplemented with 20% fetal calf serum, and lipopolysaccharide (LPS) mitogen stimulation. Harvesting at 24 and 72 hours was accomplished using colchicine incubation for 40 minutes. The preparations were fixed with methanol and acetic acid in ratio of 3 to 1. Cell suspensions were dropped to air-dried clean slides. Conventional Giemsa trypsin (GTG) banding and analysis were performed. Unfortunately, no metaphases were found on the prepared slides.

The CLL FISH Probe Panel, consisting of Set 1, and Set 2, was used (Vysis, Downers Grove, IL). Probe Set 1 contains Spectrum Orange LSI p53 probe (17p13.1) and Spectrum Green, LSI ATM (11q22.3) probe. Probe Set 2 is composed of Spectrum Orange D13S319 (13q14.3) probe, Spectrum Aqua LSI13q34 (13q34) probe, and Spectrum Green CEP 12 probe which contains the D12Z3 alpha satellite sequence located at the centromere of chromosome 12. The FISH procedure was performed on peripheral blood cell chromosome preparations according to the manufacturer's instructions.

Two hundred nuclei were analyzed for each probe. The cutoff value for positivity was $> 10\%$ for monosomies of D13S319, 13q34, ATM and p53, and $> 10\%$ for trisomy 12.

The slides were examined using a Zeiss fluorescent microscope.

FISH analysis with the LSI ATM/p53 probes showed normal FISH pattern in all the analyzed cells, suggesting that deletions of both 11q22.3 and 17p13.1 regions were not present (data not shown).

FISH analysis with the D13S319/13q34/CEP12 probes showed an abnormal FISH pattern in the part of analyzed cells. Approximately 70% of nuclei were positive for monosomy 12 and 15% of 200 nuclei were positive for monosomy of 13q34 region. Nuclei with monosomy 12 and normal signal pattern for 13q14.3 and 13q34 were also detected (Figure 1), but monosomy for 13q34 locus was seen only in association with monosomy 12 (Figure 2).

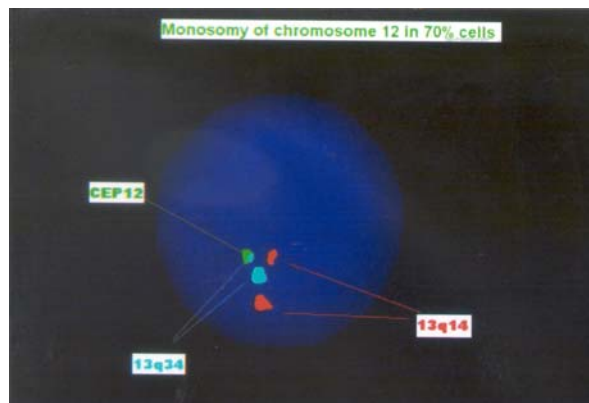


Fig. 1 – FISH result showing monosomy of 12 (labeled with Spectrum Green) and a normal signal pattern for 13q14 (Spectrum Orange) and 13q34 (Spectrum Aqua)

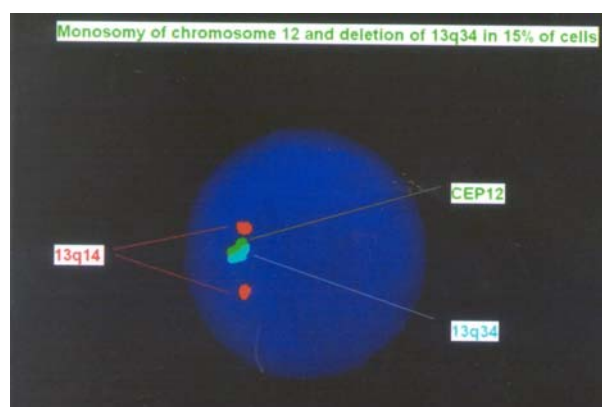


Fig. 2 – FISH result showing monosomy of 12 (labeled with Spectrum Green), deletion of 13q34 (Spectrum Aqua), and a normal signal pattern for 13q14 (Spectrum Orange)

Discussion

Chronic lymphocytic leukemia is the most common adult leukemia. Chromosomal aberrations are reported in 60% to 80% of CLL cases with the use of FISH⁵. Approximately half of patients show single abnormalities, a quarter display two abnormalities, and the remaining cases demonstrate complex chromosome changes¹⁻³.

Trisomy 12 is reported more common in atypical B-CLL than in the typical form and generally is considered as a late event in the pathogenesis of B-CLL. This abnormality is associated with poor prognosis¹.

In this patient, two pathologic clones were identified: one with monosomy 12 and one with monosomy 12 accompanied with deletion of 13q34. Since the aneuploidy of 13q34 region was not seen as a separate clone, it suggested monosomy 12 as primary phenomenon.

The combination of monosomy 12 and deletion 13q34 had been reported previously only once, in the Case Reports section of the Atlas of Genetics and Oncology⁶ in a CLL patient with a $t(1; 14; 6)$, as well as monosomy 6 and marker chromosomes. The author demonstrated that the translocation involved rearrangement of 14q32, and con-

cluded that the 14q32 rearrangement was a clinically relevant abnormality, while the exact significance of monosomy 12 and 13q34 deletion remained unknown. Several genes, possibly relevant to B-cell proliferation, including those coding for insulin-like growth factor-1, stem cell factor, as well as the murine double minute-2 (MDM2) gene and the B-cell leukemia/lymphoma 7 (BCL7) oncogene, were mapped to chromosome 12. Mainly, their role, if any, in the pathogenesis of CLL remains obscure. A small region at 12q13–15, that contains the murine double minute-2 gene (MDM-2) was indicated as possibly relevant in the pathogenesis of CLL, and overexpression of MDM-2 was identified in patients with aggressive disease^{1,7}. Several regions of chromosome arm 13q are detected where tumor-suppressor genes inactivated in head-and-neck squamous cell carcinomas may be located. One such candidate within 13q34 is the ING1 putative tumor-suppressor gene. The ING1 protein (p33) is thought to be a component of the p53 signaling pathway^{8,9}.

In non-small cell lung cancer chromosomal abnormalities are complex. Frequent losses of 3p, 6q, 8p, 9p, 9q, 13q, 17p, 18q, 19p, 21q and 22q have been reported while gains of 1p, 1q, 3q, 5p, 7p, 7q, 8q, 11q and 12q have also been common¹⁰.

Conclusion

Simultaneous occurrence of monosomy 12 and 13q34 deletion in a patient with B-cell chronic lymphocytic leukemia was described second time, but here as the only aberrations in a patient's karyotype. The prognostic significance and underlying pathogenetic event(s) remain unknown. However, karyotypic complexity is an adverse prognostic indicator in a patient with CLL. To our knowledge, the present case is unique, with no similar case reported to date. The incidence and prognostic significance of this karyotypic evolution is difficult to assess and studies of similar cases may give additional insight into this interesting observation.

R E F E R E N C E S

1. Seiler T, Dohner H, Stilgenbauer S. Risk stratification in chronic lymphocytic leukemia. *Semin Oncol* 2006; 33(2): 186–94.
2. Zenz T, Dohner H, Stilgenbauer S. Genetics and risk-stratified approach to therapy in chronic lymphocytic leukemia. *Best Pract Res Clin Haematol* 2007; 20(3): 439–53.
3. Gribben JG. Molecular profiling in CLL. *Hematology* 2008; 2008(1): 444–9.
4. Schollkopf C, Rosendahl D, Pipper C, Rostgaard K, Hjalgrim H. Risk of second cancer after chronic lymphocytic leukemia. *Int J Cancer* 2007; 121(1): 151–6.
5. Mehes G. Chromosome abnormalities with prognostic impact in B-cell. 2. chronic lymphocytic leukemia. *Pathol Oncol Res* 2005; 11: 205–10.
6. Dwivedi A, Casey T, Adhvaryu SG. A case of chronic lymphocytic leukemia (CLL) with a rare chromosome abnormality: t(1;14;6)(q21;q32;p21), a variant of t(6; 14)(p21; q32). *Atlas genet cytogenet oncol haematol* [cited 2007 August 5]. Available from: <http://AtlasGeneticsOncology.org/Reports/0614AdhvaryuID100033.html>
7. Gozzetti A, Marotta G, Lenoci M, Crupi R, Tozzoli D, Calabrese S, et al. Trisomy 12 and t(14; 22) (q32; q11) in a patient with B-cell chronic lymphocytic leukemia. *Hematology* 2004; 9(5-6): 405–7.
8. Gupta VK, Schmidt AP, Pashia ME, Sunwoo JB, Scholnick SB. Multiple regions of deletion on chromosome arm 13q in head-and-neck squamous-cell carcinoma. *Int J Cancer* 1999; 84(5): 453–7.
9. Sanchez-Cespedes M, Okami K, Cairns P, Sidransky D. Molecular analysis of the candidate tumor suppressor gene ING1 in human head and neck tumors with 13q deletions. *Genes Chrom Cancer* 2000; 27(3): 319–22.
10. Panani AD, Roussos C. Cytogenetic and molecular aspects of lung cancer. *Cancer Lett* 2006; 239: 1–9.

Received on July 7, 2009.
Accepted on December 11, 2009.