



Use of Marlex mesh with methylmethacrylate to repair large full-thickness defects after subtotal sternectomy caused by chondroma

Primena Marlex mreže sa metilmetakrilatom za rekonstrukciju velikih punih defekata posle suptotalne sternektomije zbog hondroma

Vojkan Stanić*, Tatjana Vulović†, Davor Stamenović*, Gordana Đorđević‡

Military Medical Academy, *Clinic for Thoracic Surgery, Belgrade; Clinical Center Kragujevac, †Center for Anesthesiology, Kragujevac; ‡School of Medicine, Kragujevac

Abstract

Background. Sternal benign neoplasms are extremely rare. Chondroma is a benign tumor of cartilage and can be single or multiple. **Case report.** We presented a case of 28-year-old woman with chondroma of the sternum treated by “en bloc” resection of the tumor (subtotal sternectomy). The chest wall defect was repaired by the placement of Marlex mesh and methylmethacrylate (“sandwich method”) for stabilization of the thoracic wall. This place was covered with pectoralis major muscle and skin. The postoperative course was uneventful and the wounds healed by primary intention. **Conclusion.** The functional and cosmetic results in the usage of Marlex mesh with methylmethacrylate to repair a large full-thickness defect after subtotal sternectomy caused by chondroma were good and the patient was able to resume her preoperative level of activity.

Key words: chondroma; thoracic surgical procedures; prostheses and implants; treatment outcome.

Apstrakt

Uvod. Sternalne benigne neoplazme izuzetno su retke. Hondromi predstavljaju benigne neoplazme hrskavice i mogu biti pojedinačni ili multipli. **Prikaz bolesnika.** U radu je prikazana bolesnica, stara 28 godina, sa hondromom sternuma koji je lečen *en bloc* resekcijom tumora (suptotalna sternektomija). Defekat zida grudnog koša rekonstruisan je plasiranjem Marlex mreže sa metilmetakrilatom (metoda „sendvič“) radi stabilizacije torakalnog zida. Ovo mesto pokriveno je velikim prektoralnim mišićem i kožom. Postoperativni tok bio je uredan, sa primarnim zarastanjem rane. **Zaključak.** Funkcijski i estetski rezultati primene Marlex mreže i metilmetakrilata u rekonstrukciji velikog defekta zida grudnog koša bili su dobri, pa je bolesnica mogla da se vrati na preoperativni nivo aktivnosti.

Ključne reči: hondrom; hirurgija, torakalna, procedure; proteze i implantati; lečenje, ishod.

Introduction

Chest wall tumors comprise 7–8% of all bony tumors^{1,2}. Most primary chest wall tumors are malignant. Out of the total number, 85–90% occurs in the ribs and 10–15% in the sternum. Primary tumors of the sternum are rare, accounting for approximately 1% of primary bone tumors³. Most of these are malignant and the most common lesion is chondrosarcoma⁴. Chondroma is a benign tumor of cartilage and can be single or multiple. Multiple chondromas are a condition known as Ollier's disease. It affects males and females equally, at around the age of 20–30. When chondromas are formed within the medullar cavity within the bone, they are called enchondroma. Enchondromas have the potential to become malignant chondrosarcomas. In Ollier's disease 30%

of patients have malignant transformation. Overall 1% of enchondromas undergo malignant transformation^{1,2}.

Due to the difficult differentiation between chondroma and chondrosarcoma it is very important that the benign chondroma should be treated like malignant chondrosarcoma. Therefore, performing a wide “en bloc” resection of the tumor is critical. Most surgeons propose that the wide resection must be done in all cases of thoracic wall tumors³.

Case report

Twentyeight-year-old female, was hospitalized in our clinic exhibiting a large mass protruding from the sternal area. She reported that the lesion appeared two years ago without local pain. She denied loosing weight, smoking and

alcoholism. Three months before the hospitalization, the pain appeared at the sternal area. Her previous pathological history is without other illnesses. Physical examination was normal, except for the mass in the sternal area. A thorax computerized tomography was performed, showing an expansive solid lesion in the medium part of sternum with diameter of approximately 4.0 cm evincing density of soft parts and discrete contrast impregnation in the initial phase. The lesion invaded the anterior thoracic wall but not the anterior mediastinum. Skeleton scintigraphy demonstrated a tracer hyperfixating area in the sternum, without other abnormal skeletal areas.

A wide "en bloc" resection was performed to excise the tumor so that the patient was submitted to a subtotal sternectomy. Thoracic wall defect (8×5 cm) was repaired by the placement of a Marlex mesh "sandwich" and methylmethacrylate for stabilization of the thoracic wall. A "sandwich" contained two layers of Marlex mesh with a filler of methylmethacrylate (Figure 1). The edges of the mesh were attached to the ribs on both sides, residual caudal part of the body sternum and the remaining part of the manubrium with nonresorbable Prolen 2-0 sutures (Figure 2). This site was covered with pectoralis major muscles and skin separately. The subcutaneous tissue and the skin edges could be easily approximated. The definitive post-operative histopathological result was a well distinct chondroma.

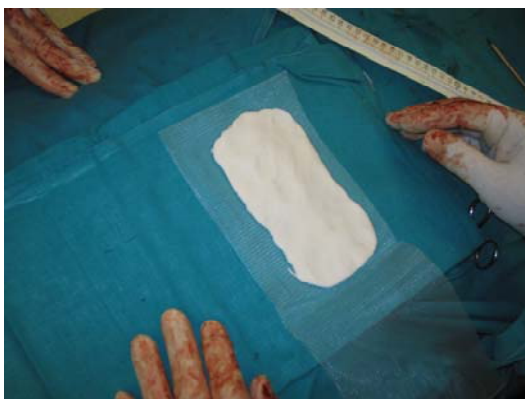


Fig. 1 – A Marlex "sandwich" containing two layers of Marlex mesh with a filler of methylmethacrylate

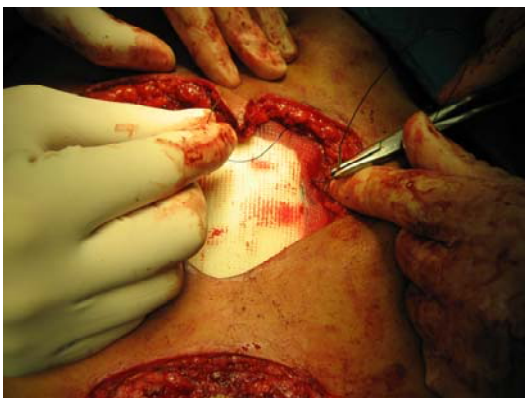

Fig. 2 – Use of Marlex mesh with methylmethacrylate to repair large full-thickness defects after subtotal sternectomy caused by chondroma

The postoperative course was uneventful and the wounds healed by primary intention (Figure 3). At the latest follow-up evaluation (twenty-four months postoperatively), the patient was alive, without signs of local recurrence or distant metastasis and very satisfied with the result (Figure 4).

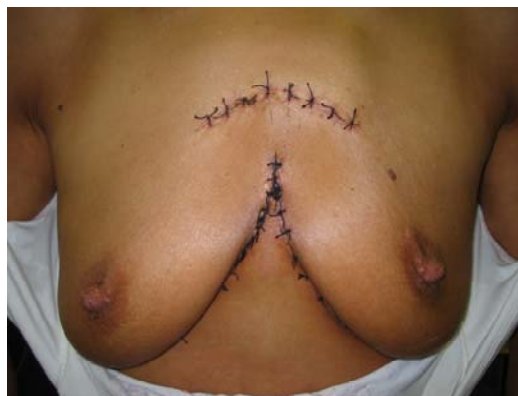

Fig. 3 – The wound appearance after a subtotal sternectomy due to a chondrosarcoma and placement of a Marlex mesh "sandwich" and methylmethacrylate

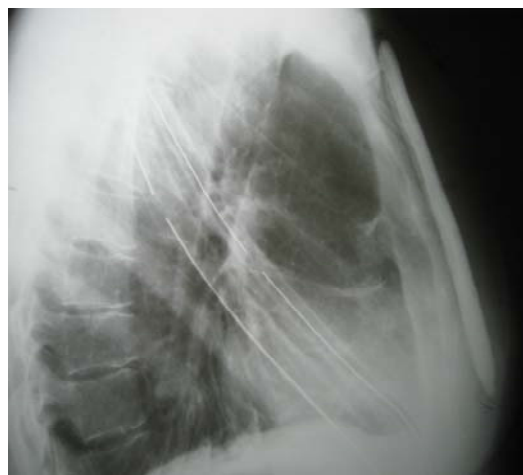


Fig. 4 – Rendgenogram showing no signs of local recurrence or distant metastasis of a chondrosarcoma

The functional and cosmetic results were good and patients were able to resume her preoperative level of activity. There was no limitation in the range of motion of neither shoulder, and there were no motor or sensory deficits affecting the muscles of the shoulder girdle or the arm. The patient stated that there were no differences in her quality of life or her lifestyle compared with the preoperative status.

Discussion

Management of large defects of the chest wall after total or subtotal sternectomy has remained difficult and controversial. Various methods of reconstruction have been described, including the use of steel bars and Marlex mesh, the use of Marlex mesh with or without methylmethacrylate, the use of acrylic resin and Gore-Tex soft-tissue patch^{2, 4}. When primary wound closure had not been possible, various myocutaneous and pedicle omental flaps have been used to close the defect^{2, 5}.

Generally, the surgeons use two main methods for reconstruction sternal defects after total or subtotal sternectomy nowadays. Some authors use only one or two layers of Marlex mesh or, more recently, two layers of Marlex mesh with a filler of methylmethacrylate, thereby creating a rigid prosthesis. Other authors use only myocutaneous flaps, with or without a layer of Marlex mesh. However, doing so resulted in a loss of function of the muscle that was used in the flap. The ideal procedure requires only the minimum quantity of synthetic material and also avoids interfering with function as is seen with the use of muscle flaps.

Nevertheless, because of the absence of any complications intraoperatively in the immediate postoperative period or during the entire duration of follow-up, we believe that operative procedure we performed offers a viable alternative to the above-mentioned techniques^{6,7}.

On the basis of our experience we recommend the use of "sandwich method" to repair full-thickness defects of the anterior chest wall after total or subtotal sternectomy and the

use of pectoralis major muscle to cover this place. By this method we could realize good chest wall stability and create a rigid prosthesis. A "sandwich" of Marlex mesh and the methylmethacrylate and usage of pectoralis major muscle to cover the place provide good cosmetic and functional results and short hospital stays. This is a good method for stabilization of the chest wall avoiding paradoxical respiratory movements.

Conclusion

A combination of prosthetic materials Marlex mesh with methylmethacrylate ("sandwich" method) provide good cosmetic and functional results and short hospital stays in the patient with chondroma treated by subtotal sternectomy. The use of this method is good for stabilization of the chest wall and enough to avoid paradoxical respiratory movements. The patient was able to resume her preoperative level of activity.

R E F E R E N C E S

1. *Waller DA, Newman RJ.* Primary bone tumours of the thoracic skeleton: an audit of the Leeds regional bone tumour registry. *Thorax* 1990; 45(11): 850–5.
2. *Pairolero PC.* Chest wall tumors. In: *Shields TW, LoCicero J, Ponn RB,* editors. *General thoracic surgery.* 5th ed. Philadelphia: Lippincott Williams & Wilkins; 1999. p. 589–98.
3. *Morin B, Le Rochais JP, Galateau F, Icard P.* Costal chondroma and chondrosarcoma. *Ann Chir* 2000; 125(8): 773–5. (French)
4. *Halm HF, Hoffmann C, Winkelmann W.* The use of a Gore-Tex soft-tissue patch to repair large full-thickness defects after subtotal sternectomy. A report of three cases. *J Bone Joint Surg Am* 2001; 83-A(3): 420–3.
5. *Shimizu J, Nakamura Y, Tsuchida K, Watanabe S, Tsuchiyama T, Ikebata Y,* et al. Complete sternectomy for metastatic carcinoma with reconstruction using a latissimus dorsi musculocutaneous flap. *Eur J Cardiothorac Surg* 1995; 9(6): 342–4.
6. *Zisis C, Dountsis A, Dahabreh J.* Giant chest wall tumor. *Eur J Cardiothorac Surg* 2003; 24(5): 825.
7. *Watt AJ.* Chest wall lesions. *Paediatr Respir Rev* 2002; 3(4): 328–38.

The paper received on October 25, 2007.