



Intramuscular hemangioma of the retropharyngeal space

Intramuskularni hemangiom retrofarinksnog prostora

Ivan Boričić*, Zorica Stojšić*, Anton Mikić†, Dimitrije Brašanac*,
Nada Tomanović*, Dragoljub Bacetić*

University of Belgrade, School of Medicine, *Institute of Pathology, †Institute of
Otorhinolaryngology, Belgrade

Abstract

Background. Intramuscular hemangioma (IMH) is a distinctive type of hemangioma occurring within skeletal muscle. Most IMH are located in the lower extremity, particularly in the muscles of the thigh. When present in the head and neck region, the masseter and trapezius muscle are the most frequently involved sites. **Case report.** We reported a case of unusual localization of the head and neck IMH occurring within the retropharyngeal space (RPS). To our knowledge, this is the second such case reported in the English literature. The tumor presented as a left-sided neck mass with bulging of the posterior and left lateral oropharyngeal wall on indirect laryngoscopy. Computed tomography (CT) scan revealed an ill-defined mass in the RPS at the oropharyngeal level. The lesion was excised via a transoral approach and microscopically diagnosed as IMH, the complex malformation subtype. Although surgical margins were positive, no recurrence of the tumor was noted in the 17-month follow-up. **Conclusion.** Intramuscular hemangioma should be considered in the differential diagnosis of deep head and neck masses. The knowledge of the infiltrative nature and recurrence rate of an IMH is useful for appropriate management.

Key words:

hemangioma; oropharynx; muscle neoplasms;
diagnosis; otorhinolaryngologic procedures; treatment
outcome.

Apstrakt

Uvod. Intramuskularni hemangiom (IMH) je poseban tip hemangioma koji se javlja u skeletnom mišiću. Najčešće je lokalizovan u donjem ekstremitetu, naročito u mišićima natkolenice. U regiji glave i vrata, *m. masseter* i *m. trapezius* najčešća su mesta javljanja IMH. **Prikaz bolesnika.** Prikazana je bolesnica sa retkom lokalizacijom IMH u retrofarinksnom prostoru, drugi takav u literaturi na engleskom jeziku. Tumor se manifestovao otokom leve strane vrata kod žene u životnom dobu od 51 godine. Pregled indirektnom laringoskopijom otkrio je izbočinu zadnjeg i levog bočnog zida orofarinksa. Nalaz kompjuterizovane tomografije (KT) ukazao je na nejasno ograničenu masu u retrofarinksnom prostoru u nivou orofarinksa. Lezija je ekscidirana transoralnim pristupom i histološki dijagnostikovana kao intramuskularni hemangiom. Iako je na linijama resekcije delimično postojalo tumorsko tkivo, recidiv nije registrovan u postoperativnom praćenju bolesnice u trajanju od 17 meseci. **Zaključak.** U diferencijalnoj dijagnozi dubokih lezija glave i vrata treba misliti i na IMH. Infiltrativni rast i posledično recidiviranje ovog tumora osobine su od značaja za određivanje odgovarajućeg terapijskog postupka.

Ključne reči:

hemangiom; orofarinks; neoplazme lokalizovane u mišiću; dijagnoza; otorinolaringološke procedure; lečenje, ishod.

Introduction

Intramuscular hemangioma (IMH) is a proliferation of benign vascular channels within skeletal muscle¹. Unlike cutaneous hemangiomas, IMH are very rare, accounting for 4,4% of all vascular tumors². Not more than 15 to 27% of all IMH are located in the head and neck musculature¹⁻⁵, most commonly in the masseter and trapezius muscle^{4, 6-8}. Sporadic cases involving the pterygoid and thyrohyoid⁹, sternocleidomastoid^{4, 7}, orbital⁶ and posterior neck muscles¹⁰ have been also described. To the best of our knowledge, only one

case of IMH situated in the retropharyngeal space (RPS) has been reported in the English literature so far¹¹. We present here the clinical and pathological findings of a further case of IMH occurring in the RPS.

Case report

A 51-year-old woman was referred to our clinic for the assessment of a left-sided neck swelling of a 15-day duration. External examination revealed a 4 × 3 cm firm, non-mobile, painless and non-pulsatile mass in the middle portion

of the left side of the neck below the sternocleidomastoid muscle. Indirect laryngoscopy revealed bulging of the posterior and left lateral oropharyngeal wall. The patient was otherwise in good general health, and the rest of the otolaryngologic, physical and laboratory examinations were normal. The computed tomography (CT) scan with contrast enhancement revealed an ill-defined left-sided retropharyngeal mass. The lesion showed heterogeneous density with a hypodense area inferiorly (Figure 1). There was no

examination revealed the set of characteristic features of IMH, the complex malformation subtype. The lesion was poorly circumscribed with the positive surgical margins. The tumor was composed of numerous variably sized vascular channels set in a fatty-fibrous stroma with scattered, entrapped striated muscle fibres (Figure 2). Most of the vascular channels presented as thick-walled blood vessels and capillaries lined by prominent endothelial cells. The first vascular component corresponded to irregularly shaped large-

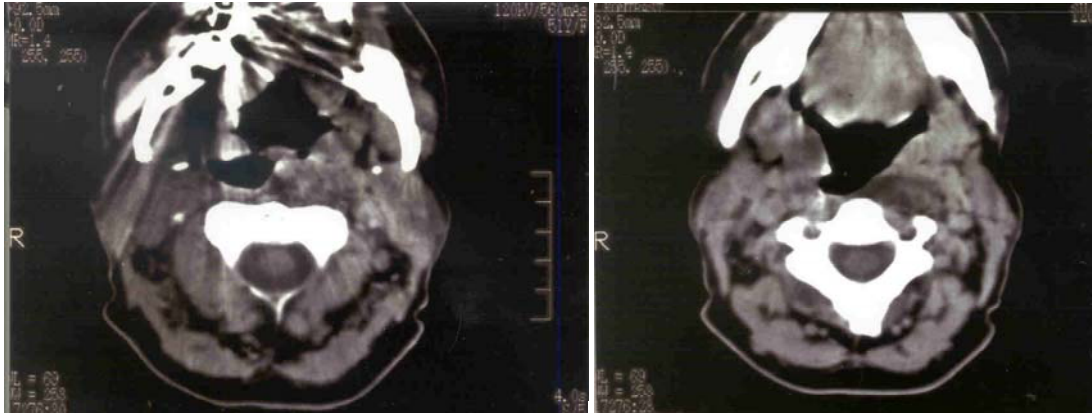


Fig. 1 – Intramuscular hemangioma of the retropharyngeal space. Computerized tomography scan with contrast enhancement (oropharyngeal level) shows an ill-defined mass of heterogeneous density in the left retropharyngeal space (a), with a hypodense area in the inferior portion of the lesion (b)

evidence of any other soft-tissue, bony or vascular abnormalities. The patient underwent surgical excision of the lesion by a transoral approach. Following the incision of the posterior wall of oropharynx and dissection of muscles underneath, a poorly circumscribed tumor became exposed. It was dissected bluntly and excised *en-bloc*. However, the neoplasm appeared to have been resected incompletely.

and medium-sized blood vessels, reminiscent of arteries and veins. Arterial-type vessels exhibited internal elastic lamina, and venous showed marked fibrointimal thickening. In addition, isolated bundles of smooth muscle fibers were present throughout the tumor. Occasionally, these structures showed lumens with endothelial lining and attachments to vessel walls, resembling malformed blood vessels and their

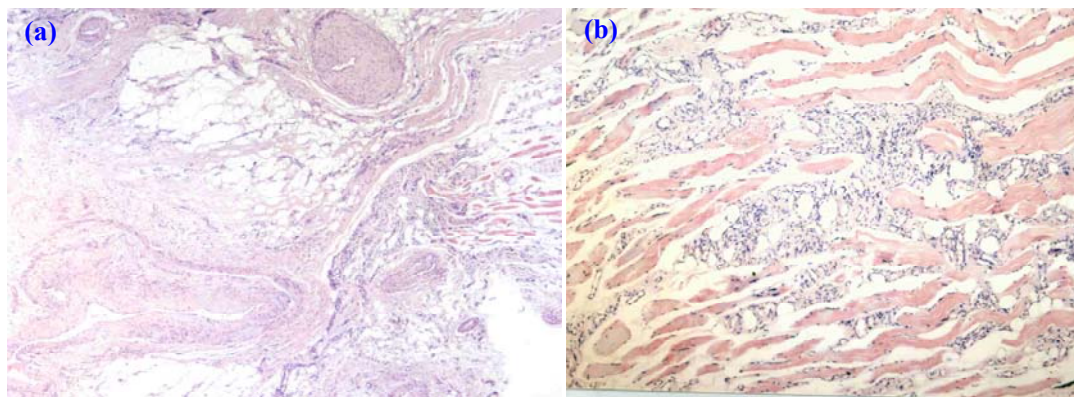


Fig. 2 – Intramuscular hemangioma, the complex malformation subtype, consisting of variably sized thick-walled blood vessels (a), and capillaries (b) intermingled with skeletal muscle fibers. [hematoxylin-eosin, original magnification: (a) $\times 40$; (b) $\times 100$]

The patient's postoperative course was complicated by pharyngeal edema which required tracheostomy. After closure of the tracheal stoma, the patient was discharged. The patient is currently free from disease 17 months after the initial surgery.

The resected tumor was a non-encapsulated, yellowish-white, solid mass measuring $4 \times 2.5 \times 1.2$ cm. Histological

branches, respectively (Figure 3). On serial sections, the presence of arterio-venous shunts could not be confirmed. A variable amount of mature adipose tissue, without lipoblasts, was present throughout the tumor. The fibrous stroma was devoid of myxoid areas, being negative for Alcian blue staining. Thrombosis, phleboliths or metaplastic ossification were not seen.

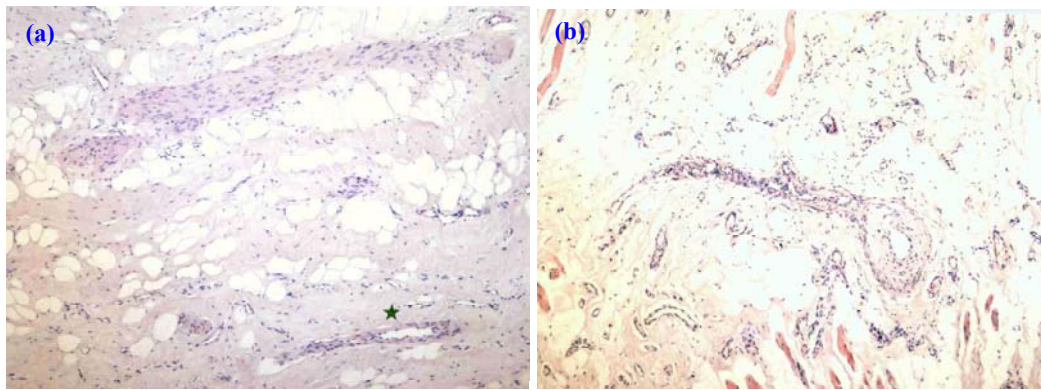


Fig. 3 – Smooth-muscle bundles in intramuscular hemangioma with occasional lumen, reminiscent of a blood vessel (arterisk) (a), and attachment to vessel wall, giving the impression of a vessel branch (b) [hematoxylin-eosin, original magnification: (a) & (b) × 100]

Discussion

Primary neoplasms originating in the RPS are extremely uncommon¹². To the best of our knowledge, only one case of the retropharyngeal IMH, originating in the prevertebral muscles, has been reported in the English literature¹¹. The presented tumor is the second documented case of an IMH of the RPS. Considering the anatomy of the RPS^{12, 13}, we assume that the present case of IMH occurred within the pharyngeal constrictor muscles or the prevertebral muscles, the anterior and posterior border of the RPS, respectively.

The skeletal muscle hemangioma is probably the most common form of hemangioma of deep soft-tissue, but it is rare in the spectrum of benign vascular neoplasms³. The most common site of involvement is the lower limb, followed by the head and neck region¹⁻³. Clinically, IMH is more likely to pose diagnostic problems than superficial hemangioma³. This tumor usually does not exhibit any of the vascular signs such as thrills and pulsations that are characteristic of superficial hemangioma^{3, 4, 6, 11}. A palpable, usually painless mass is the most common initial presentation⁶. The present case had the same clinical appearance as the first reported IMH of the RPS¹¹. Intramuscular hemangioma most commonly affects adolescents and young adults^{1-3, 5}, but can occasionally present in the fifties and sixties², as in the case reported here. Accurate preoperative diagnosis of IMH has been reported in less than 8% of the cases⁵, mostly due to its rarity, deep localization and non-specific clinical manifestations^{1, 4, 9}. Plain radiography is usually non-diagnostic, but may be useful in making a diagnosis by revealing tortuous vascular spaces, phleboliths or metaplastic bone^{4-6, 9}. However, our case lacked these features. Arteriography may delineate the vascular nature of an IMH if it is large enough to show the feeding arteries, but may fail to do so in small tumors^{4, 6, 8}. Although it is superior to most studies, CT may not always clearly indicate the vascularity of the lesion, and can underestimate the full extent of the mass⁶. Computerized tomography scan does not allow precise differentiation between IMH and muscle or surrounding tissue⁷, as in the present case. Magnetic resonance imaging (MRI) is much more useful clinically than other radiographic methods, providing better detection and delineation of the extent of IMH than CT^{6, 8}. Fine needle aspiration cytology of IMH is com-

monly non-diagnostic as a result of excessively bloody specimen⁶⁻⁹.

Definitive diagnosis is usually established by histopathological investigation of the resected lesion. Intramuscular hemangioma usually grows as non-encapsulated mass and due to its infiltrative nature the margins of the tumor are very difficult to define. The infiltrative growth pattern, deep location and difficult control of perioperative bleeding are factors that make surgery difficult and lead to high risk of incomplete resection¹⁰. Local recurrence has been reported as high as 50% of cases^{1, 2, 5}. The recurrence rate is high even after wide surgical excision⁹. Although the tumor of our patient had also been resected incompletely, there was no recurrence noted at the 6-month follow-up.

Histologically, IMH displays a heterogeneous pattern of vessels both in terms of type and size, and a predominant pattern is often evident². Although IMH of the capillary subtype has a greater predilection for the head and neck musculature¹⁻³, our case corresponded to the complex malformation subtype with prevalent arterio-venous component, according to the histological classification of Beham and Fletcher². The same authors deny the prognostic significance of histological subclassification of IMH, by claiming that recurrences correlate only with the adequacy of excision, reflecting the infiltrative nature of all IMH, regardless of the histologic subtype². It has been proposed that IMH are rather vascular malformations than „angiomas“ indicated by the heterogeneity of their histological pattern and the presence of the lipomatous component¹⁻³. All IMH are associated with variable amounts of mature fat, explaining why some of these lesions had been erroneously called angiolipomas. Beham and Fletcher² described irregular smooth muscle fibers, isolated or attached to a vessel wall, in the venous subtype of IMH. These structures were also seen in the present case, occasionally exhibiting lumens. We consider these smooth muscle bundles, at least some of them, to be a part of a spectrum of malformed blood vessels, seen in IMH.

A histological subclassification of IMH is important in view of differential diagnosis. Although histologic diagnosis is usually easy, IMH has to be distinguished from intramuscular lipoma, or well differentiated liposarcoma³. Pure capillary IMH is sometimes confused with angiosarcoma³. Dis-

inction from venous hemangioma is based histologically on the absence of an internal elastic lamina in vessel walls, and infiltrative growth pattern^{1,2}. In angiomatosis, a large segment of the body is affected by diffuse hemangioma in contiguous fashion, and the lesion should be diagnosed both on clinical and radiological parameters^{1,3,14}. The diagnosis of arteriovenous hemangioma also requires clinicopathological and radiological correlation¹. Intramuscular hemangioma shares vascular and adipose component with angiomyxolipoma. However, angiomyxolipoma is a well circumscribed tumor with a myxoid component, lacking the entrapment of nerves and striated muscle fibers¹⁵.

Conclusion

In summary, the presented case is the second reported IMH arising in the RPS in the English literature. Intramuscular hemangioma should be in the differential diagnosis of any soft-tissue mass found in the RPS. Concerning the histology of IMH, we found that some of the previously described smooth muscle structures might be malformed blood vessels. The optimal treatment of an IMH is complete wide resection because of the infiltrative nature of the tumor. Long-term clinical and radiological follow-ups are strongly recommended for early detection of a possible recurrence.

R E F E R E N C E S

1. *Fletcher CD, Unni KK, Mertens F*, editors. World Health Organization: Classification of tumors. Pathology and genetics of tumours of soft tissue and bone. Lyon: IARC Press. 2002.
2. *Beham A, Fletcher CD*. Intramuscular angioma: a clinicopathological analysis of 74 cases. *Histopathology* 1991; 18(1): 53–9.
3. *Weiss SW, Goldblum JR*. Benign tumors and tumor-like lesions of blood vessels. In: *Weiss SW, Goldblum JR*, editors. *Enzinger and Weiss's soft tissue tumors*. 4th ed. St. Louis: C.V. Mosby; 2001. p. 837–90.
4. *Wolf GT, Daniel F, Krause CJ, Kaufman RS*. Intramuscular hemangioma of the head and neck. *Laryngoscope* 1985; 95(2): 210–3.
5. *Allen PW, Enzinger FM*. Hemangioma of skeletal muscle. An analysis of 89 cases. *Cancer* 1972; 29(1): 8–22.
6. *Rositer JL, Hendrix RA, Tom LW, Potts WP*. Intramuscular hemangioma of the head and neck. *Otolaryngol Head Neck Surg* 1993; 108(1): 18–26.
7. *Lee JK, Lim SC*. Intramuscular hemangiomas of the mylohyoid and sternocleidomastoid muscle. *Auris Nasus Larynx* 2005; 32(3): 323–7.
8. *Odabasi AO, Metin KK, Mutlu C, Basak S, Erpek G*. Intramuscular hemangioma of the masseter muscle. *Eur Arch Otorhinolaryngol* 1999; 256(7): 366–9.
9. *Giudice M, Piazza C, Bolzoni A, Peretti G*. Head and neck intramuscular haemangioma: report of two cases with unusual localization. *Eur Arch Otorhinolaryngol* 2003; 260(9): 498–501.
10. *Makeieff M, Maurice N, Mondain M, Crampette L, Guerrier B*. Intramuscular hemangioma of posterior neck muscles. *Eur Arch Otorhinolaryngol* 2001; 258(1): 28–30.
11. *Beecham JE, Behrens HW*. Intramuscular hemangioma of the head and neck: report of a case involving the prevertebral muscles. *Head Neck Surg* 1988; 10(6): 402–5.
12. *Chong VF, Fan YF*. Radiology of the retropharyngeal space. *Clin Radiol* 2000; 55(10): 740–8.
13. *Davis WL, Harnsberger HR, Smoker WR, Watanabe AS*. Retropharyngeal space: evaluation of normal anatomy and diseases with CT and MR imaging. *Radiology* 1990; 174(1): 59–64.
14. *Val-Bernal JF, Martino M, Garces CM, Garijo MF*. Soft-tissue angiomatosis in adulthood: a case in the forearm showing a prominent myxoid adipose tissue component mimicking liposarcoma. *Pathol Int* 2005; 55(3): 155–9.
15. *Mai KT, Yazdi HM, Collins JP*. Vascular myxolipoma ("angiomyxolipoma") of the spermatic cord. *Am J Surg Pathol* 1996; 20(9): 1145–8.

The paper was received on March 13, 2007.