

# Unusual Dyspnea in a Hemodialysis Patient

CASE REPORT

Ching-Hsiang Wang<sup>1</sup>, Jenq-Shyong Chan<sup>2</sup>,  
Chung-Chi Yang<sup>3</sup>, Po-Jen Hsiao<sup>2</sup>

- 1 Department of Internal Medicine, Taoyuan Armed Forces General Hospital, Taiwan.
- 2 Division of Nephrology, Department of Internal Medicine, Taoyuan Armed Forces General Hospital, Taiwan.
- 3 Division of Cardiology, Department of Internal Medicine, Taoyuan Armed Forces General Hospital, Taiwan.

## Abstract

The typical clinical symptoms of hemothorax include a rapid development of chest pain or dyspnea, which may be life-threatening without immediate management. As we know, spontaneous hemothorax, a collection of blood within the pleural cavity without previous history of trauma or other cause, which usually onsets suddenly. The early and accurate diagnosis of spontaneous hemothorax is imperative in clinical practice. We reported a middle-age male undergoing regular hemodialysis was referred to our emergency department due to unknown cause of dyspnea and acute respiratory failure. Chest radiography revealed bilateral patchy infiltration of lung. Pleural tap analysis showed exudative pleural effusion with numerous red blood cells. Video-assisted thoracic surgery (VATS) were performed and confirmed the final diagnosis of spontaneous hemothorax. He was then successfully treated with the surgery of VATS combined chest tube thoracostomy.

## Contact information:

**Po-Jen Hsiao.**

**Address:** Division of Nephrology, Department of Internal Medicine, Taoyuan Armed Forces General Hospital, Taiwan. No.168, Zhongxing Rd., Longtan Dist., Taoyuan City 325, Taiwan, R.O.C.  
**Tel:** +886-3-4799595.  
**Fax:** +886-3-4801625.

✉ [a2005a660820@yahoo.com.tw](mailto:a2005a660820@yahoo.com.tw)

**Chung-Chi Yang.**

**Address:** Division of Cardiology, Department of Internal Medicine, Taoyuan Armed Forces General Hospital, Taiwan. No.168, Zhongxing Rd., Longtan Dist., Taoyuan City 325, Taiwan, R.O.C.  
**Tel:** +886-3-4799595.  
**Fax:** +886-3-4801625.

✉ [t220979@ms16.hinet.net](mailto:t220979@ms16.hinet.net)

## Keywords

Dyspnea; Hemodialysis; Hemothorax.

## Introduction

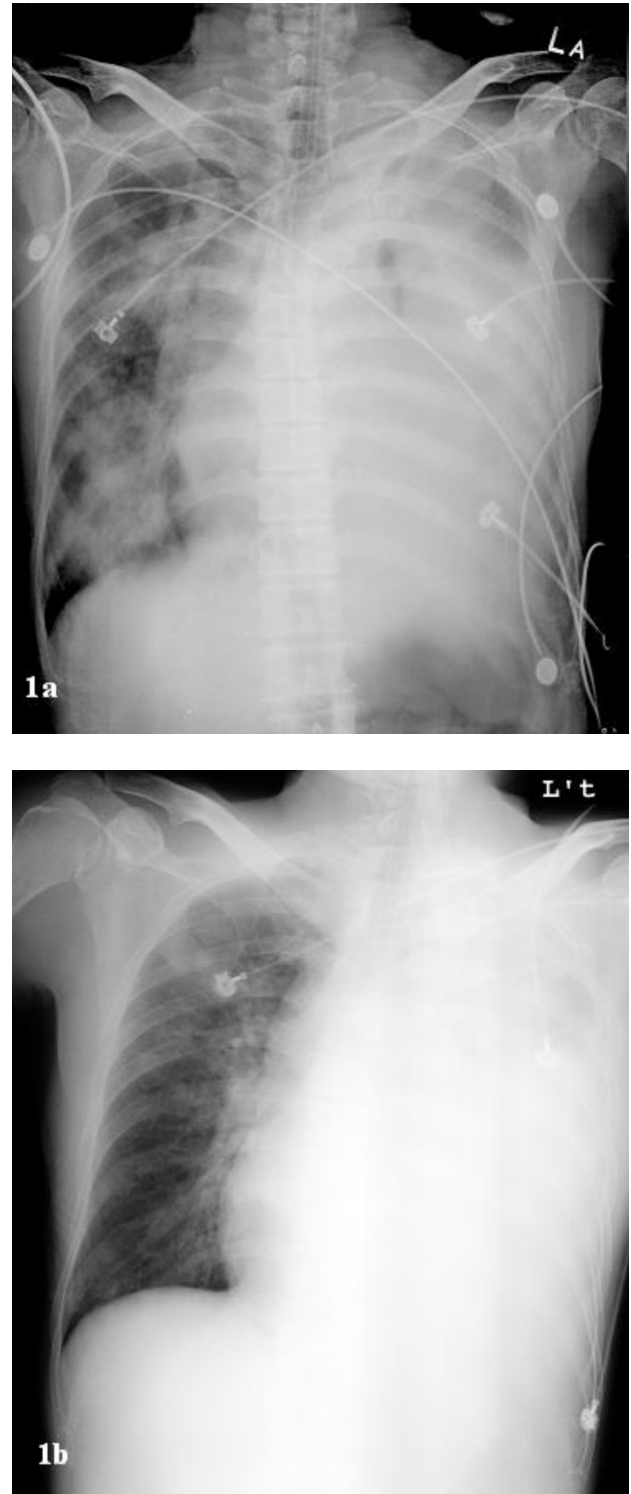
Hemothorax is a condition of a pleural fluid with a hematocrit greater than 50%. The most common cases of hemothorax are related to complications of traumatic injury or iatrogenic causes. The most common symptoms of hemothorax include dyspnea, chest pain, and combined unstable hemodynamic state. Spontaneous hemothorax is relative rare, around 3-7% of hemothorax cases [1-3]. Most causes of spontaneous hemothorax can be attributed to several di-

seases processes such as thoracic malignancies, infections, pulmonary arteriovenous malformation (AVM), pulmonary embolism, vascular rupture, abnormal anatomy, immune-mediated disorders with lung involvement and hematologic abnormalities [1-5]. It can become life-threatening without immediate and appropriate management. Here we reported a rare case of hemodialysis patient complicated spontaneous hemothorax. Finally, he recovered well by the timely treatment.

## Case report

A 53-year-old man undergoing regular hemodialysis was referred to our emergency department (ED) due to acute respiratory failure status post endotracheal intubation in ED before admission to intensive care unit. He has history of hypertensive cardiovascular disease, rheumatic heart disease and chronic atrial fibrillation. There was no detected history of traumatic injury or other medical invasive procedures previously. Auscultation of the chest revealed profound left-side decreasing breathing sounds. The presentation at ED revealed no febrile with a body temperature of 36.5°C, a blood pressure of 144/93 mmHg, a pulse rate of 113 beats per minute, and a respiratory rate of 22 breaths per minute. Chest radiography revealed bilateral patchy infiltration with left-side predominated **Figure 1a**. Laboratory investigation showed white blood cell count of 8940/ul, hemoglobin concentration of 7.5 g/dl, platelet count of  $190 \times 10^3/\text{mm}^3$ . International normalized ratio (INR) was 4.28. He received mechanical ventilation support, regular hemodialysis and empiric antibiotic therapy. However, following chest radiography revealed persistent infiltration in the left lung 3 days later **Figure 1b**. Chest ultrasound revealed multiple mass lesions and moderate pleural effusion in left thoracic cavity. Thus, we arranged thoracentesis and the pleural tap analysis showed as follows: dark-red color, RBC:  $1150000/\text{mm}^3$ , WBC contain-

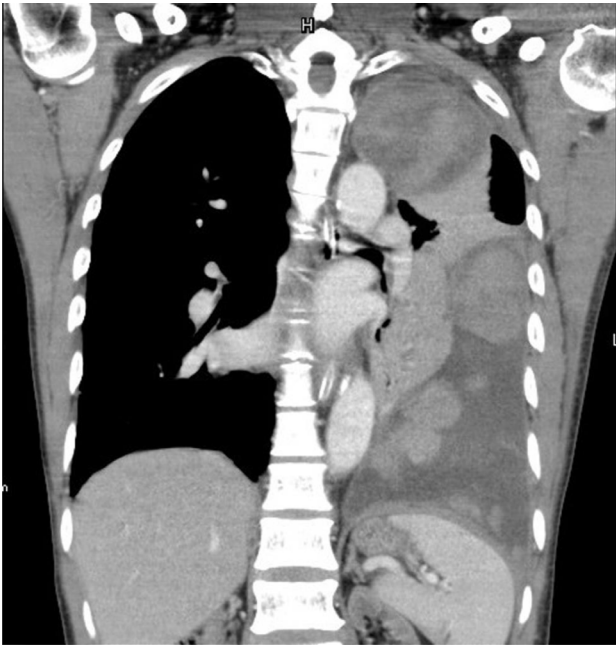Figure 1.



1a: Chest radiography showed bilateral diffuse infiltration at admission.

1b: Chest radiography showed persistent infiltration in left lung 3 days later

**Figure 2.** Contrast-enhanced CT revealed multiple well-defined heterogeneous mass lesions and homogeneous fluid accumulation of blood within the pleural space.



ning 68% PMN and 24% lymphocytes, protein: 6.32 g/dl, LDH: 1251 U/L, glucose: 13.36 mg/dl, and pH: 7.153. Serologic tests for tumor marker were all negative. Contrast-enhanced computed tomography (CT) revealed multiple well-defined mass lesions in the left lung **Figure 2**. He received video-assisted thoracic surgery (VATS) and insertion of an intercostal tube was performed. VATS showed multiple huge bloody clots without visible bleeding source or malignant lesion. All cultures and pathology were unremarkable. The diagnosis of spontaneous hemothorax complicated blood clots formation was made. Following an uneventful post-admission period, he was discharged smoothly. Currently, he presents a good clinical status and has no evidence of relapses.

## Discussion

Common etiology of hemothorax is due to chest trauma or previous invasive procedures. Spontaneous hemothorax is relative uncommon compared to traumatic hemothorax, and occurs most often owing to malignancies, anticoagulant medications, vascular rupture, endometriosis, pulmonary infarctions, and hematologic abnormalities [1-5]. CT scan is a highly accurate diagnostic study for pleural fluid or blood and is particularly helpful for localizing of blood contained. Furthermore, using the Hounsfield units is also useful [5]. In clinical practice, we should always remember to check the haematocrit including blood and pleural effusion when noticeable bloody effusion. Hemothorax may present similar to hemorrhagic effusion with a lower hematocrit due to significant dilution if delayed thoracentesis [1].

When hemothorax occurs, the most important is to maintain vital signs stability of these patients. Emergent chest tube insertion and appropriate blood transfusion should be considered. Thoracoscopic draining is a common procedure for stable patients; early VATS intervention and treatment may prevent fibrothorax and improve restrictive physiology [1, 6, 7]. In our patient, his spontaneous hemothorax could develop owing to coagulopathy, precipitated by uremic state and warfarin therapy. Correction of coagulopathy is mandatory in the case of anticoagulant induced bleeding. Spontaneous hemothorax can be potentially life-threatening, and a delayed suspicion and diagnosis can lead to poor clinical outcomes. Clinicians should be aware of the associated risk factors. Rapid recognition and prompt supportive measures are imperative.

## Contributorship Statement

Participated in drafted the manuscript and revised the manuscript: Ching-Hsiang Wang, Jenq-Shyong Chan, Chung-Chi Yang and Po-Jen Hsiao.

Contributed equally to this work (co-corresponding author): Chung-Chi Yang and Po-Jen Hsiao

### Funding

This study was supported from the grants of AF-TYGH-10801, Taoyuan Armed Forces General Hospital, Taiwan.

### Competing interests

None declared.

## Acknowledgements

We thank the patient's consenting to publish the clinical information.

## References

1. Patrini D, Panagiotopoulos N, Pararajasingham J, et al. Etiology and management of spontaneous haemothorax. *J Thorac Dis.* 2015 Mar; 7(3): 520-6.
2. Camarillo-Reyes LA, Marquez-Córdova RI, Surani S, et al. Hemothorax induced by severe cough: An unusual presentation. *SAGE Open Med Case Rep.* 2019 Apr 26; 7: 2050313X19846043.
3. Yen CW, Hsu LS, Chen CW, et al. Hepatocellular carcinoma with thoracic metastases presenting as hemothorax: A case report and literature review. *Medicine (Baltimore).* 2018 Jun; 97(22): e10945.
4. Fan J, Feng R, Hou X, et al. IgG4-related disease can present as recurrent spontaneous hemothorax: a case report. *BMC Pulm Med.* 2019 Feb 1; 19(1): 26.
5. Li PS, Tsai CL, Hu SY, et al. Spontaneous hemothorax caused by ruptured multiple mycotic aortic aneurysms: a case report and literature review. *J Cardiothorac Surg.* 2017 Dec 2; 12(1): 109.
6. Marcel Rodriguez-Guzman, Belen Gallegos-Carrera, Sara Vicente-Antunes, et al. Spontaneous Hemothorax in a Patient With von Recklinghausen's Disease. *J Clin Med Res.* 2014 Apr; 6(2): 149-52.
7. Tong YL, Lu YQ, Jiang JK, et al. Spontaneous rupture of the branches of left subclavian artery: A case report and review of the literatures. *Medicine (Baltimore).* 2018 Apr; 97(14): e0290.

### Publish in International Archives of Medicine

International Archives of Medicine is an open access journal publishing articles encompassing all aspects of medical science and clinical practice. IAM is considered a megajournal with independent sections on all areas of medicine. IAM is a really international journal with authors and board members from all around the world. The journal is widely indexed and classified Q2 in category Medicine.