



Atypical proliferating mucinous tumors of gigantic dimensions

Atipični proliferativni mucinozni tumor ogromnih dimenzija

Ivana Likić Lađević*, Nebojša Lađević†, Aleksandar Stefanović*,
Saša Kadija*, Katarina Jeremić*, Otaš Durutović‡, Spasoje Petković*,
Jasmina Atanacković*

Clinical Center of Serbia, *Institute of Gynecology and Obstetrics, †Institute of Anesthesiology and Intensive Care, ‡Institute of Urology and Nephrology, Belgrade

Abstract

Background. Ovarian tumors of low malignant potential (LMP) are also known as atypically proliferating tumors. Ovarian tumors of LPM account for approximately 15% of all epithelial ovarian cancers. Mean age of occurrence is 40 years and they are 15–20 cm in diameter. **Case report.** A 32-year-old female patient was hospitalized as an urgent case with a large tumor mass that filled the entire abdomen. Cyst was 100 × 70 cm dimensions belonging to the right ovary and filled with 18 liters of content. Right adnexectomy, resection of the second ovary, as well as biopsy of the omentum were performed. Lymphadenectomy of the right iliac and obturator area was also performed. After receiving definitive histopathological results it was decided to perform a radical reoperation. On the 10th postoperative day relaparotomy, total hysterectomy and left adnexectomy were performed. The patient was released on the 6th postoperative day. She used to come to regular examinations up to date. **Conclusion.** This case is a proof that LMP tumors have low malignant potential, they grow slowly and can reach great proportions.

Key words:

ovarian neoplasms; gynecologic surgical procedures; histology; reoperation.

Apstrakt

Uvod. Tumori ovarijuma niskog malignog potencijala (*low malignant potential* – LMP) poznati su i kao atipični proliferativni tumori. Ovi tumori ovarijuma predstavljaju otprilike 15% svih epitelijalnih ovarijalnih karcinoma. Najčešće se javljaju oko 40. godine života i prečnika su oko 15–20 cm. **Prikaz bolesnika.** Bolesnica, stara 32 godine, sa velikom tumorskom masom koja je ispunjavala ceo abdomen, hospitalizovana je kao hitan slučaj. Cista je pripadala desnom ovarijumu, dimenzija 100 × 70 cm sa tečnim sadržajem od 18 litara. Urađena je desna adnektomija sa resekcijom levog jajnika i biopsijom omentuma. Takođe, urađena je limfadenektomija desnog ilijačnog i opturatornog regiona. Posle dobijanja definitivnog patohistološkog rezultata odlučeno je da se uradi radikalizacija prethodne operacije. Desetog postoperativnog dana izvedena je relaparotomija, totalna histerektomija i leva adnektomija. Bolesnica je otpuštena šestog postoperativnog dana. Do danas je na redovnim kontrolama. **Zaključak.** Ovaj slučaj dokaz je da atipični proliferativni mucinozni tumori imaju nizak maligni potencijal, da sporo rastu i da mogu dostići velike razmere.

Ključne reči:

jajnik, neoplazme; hirurgija, ginekološka, procedure; histologija; reoperacija.

Introduction

Ovarian tumors of low malignant potential (LMP), also known as atypically proliferating tumors, comprise a group of tumors showing greater epithelial proliferation than seen in benign serous cystadenoma, although they are by definition noninvasive. Ovarian tumors of LMP account for approximately 15% of all epithelial ovarian cancers. Mean age of occurrence is 40 years¹. Ovarian LMP tumors range between benign adenoma and ovarian cancer, where the absence of stromal invasion is an absolute criterion for setting of diagnosis². About 5–10% of LMP tumors behave

very aggressively as ovarian carcinoma, while the rest behave as benign ovarian tumors³. These neoplasms do not differ macroscopically from benign changes. They are multilocular, cystic lesions with a smooth surface of an average diameter of 15–20 cm.

Case report

A 32-year-old female patient was hospitalized at the Institute for Gynecology and Obstetrics of the Clinical Center of Serbia in April 2006 as an urgent case with a large tumor mass that filled the entire abdomen. The abdomen was ex-

tremely painful, and the skin on the stomach had cracked and become infected due to overstretching (Figure 1).

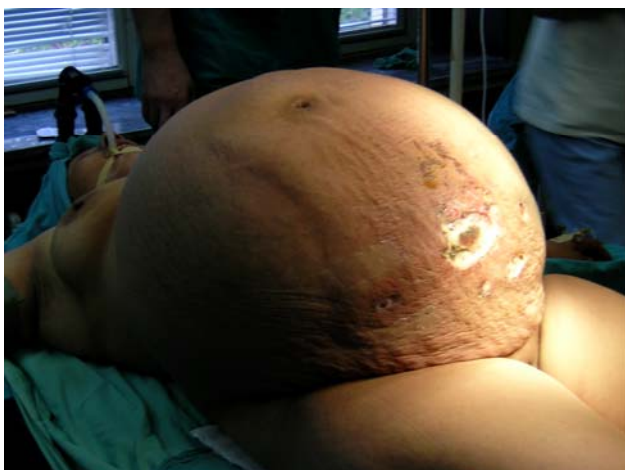
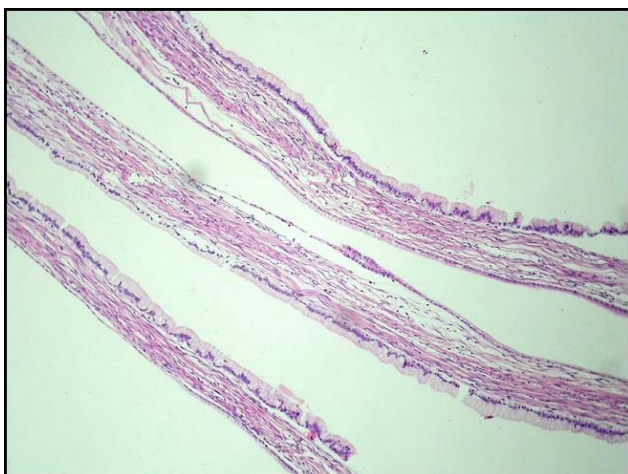
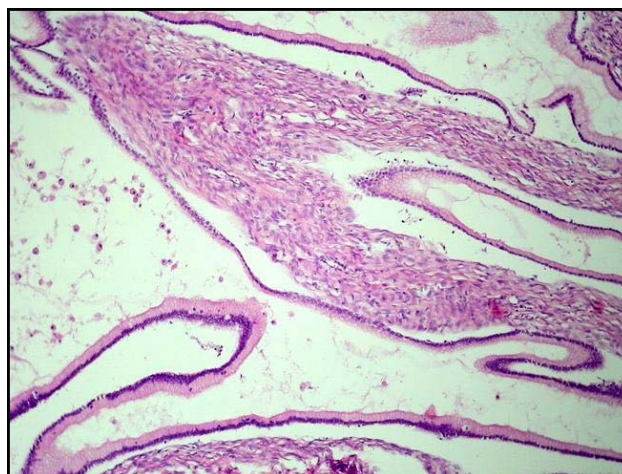
Fig. 1 – Preoperative picture of abdomen and cracked skin

The patient had noticed growth of her stomach over the past two years, but had not reported it earlier to a doc-

tor. Her stool and urine were regular. She gave birth five times, the last time three years ago. Laboratory analyses on admission to the hospital indicated increases values of leukocytes, sedimentation rate, platelets, C-reactive protein and fibrinogen. Tumor markers Ca 125 and Ca 19.9 exhibited slightly higher values. Ca 125 was 53.3 U/ml (referential values < 21 U/ml) while Ca 19.9 was 108 U/ml (referential values 0–33 U/ml). *Staphylococcus aureus* was isolated bacteriologically from the skin changes on the stomach. Antibiotic and anticoagulant therapy was initiated. After the infection was cured the patient was operated. Upon opening the stomach a cyst was located, with dimensions 100 cm × 70 cm of a smooth pearl white colored capsule belonging to the right ovary. The left ovary and uterus exhibited normal characteristics upon macroscopic inspection. During the operation, in order to permit evacuation of the tumor from the stomach, 18 liters of thick, mucous, chocolate colored content was extracted from the cyst and was sent for cytological analysis (Figures 2 and 3). Right adnexectomy was performed, resection of the second ovary, as well as biopsy of the omentum. Lymphadenectomy of the right iliac and obturator area was also performed.

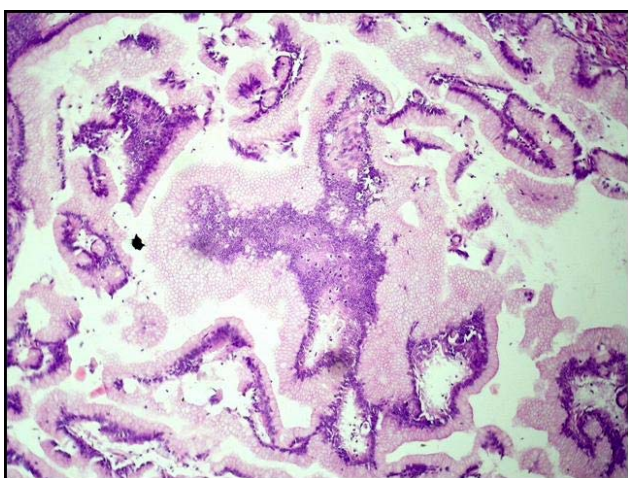


a)

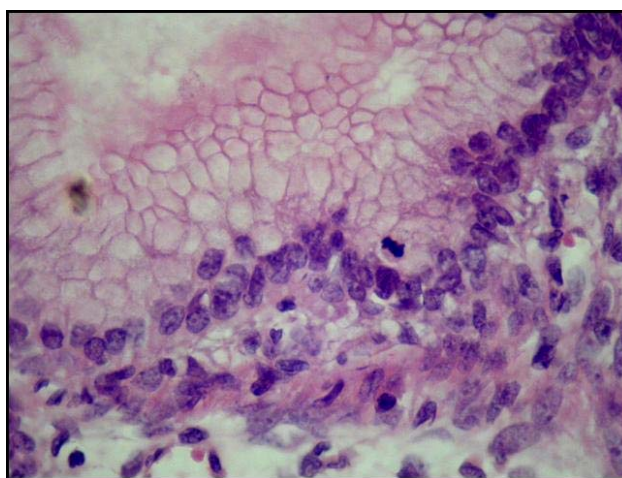


b)

Fig. 2 – Benign mucinous cystadenoma (HE × 40)



a)



b)

Fig. 3 – Benign mucinous cystadenoma borderline (HE × 40)

The histopathological report described a macroscopic oval cystic formation with a growths mass of 1 330 grams previously opened and emptied with a smooth surface and without growths (Figure 4). The interior surface was pre-

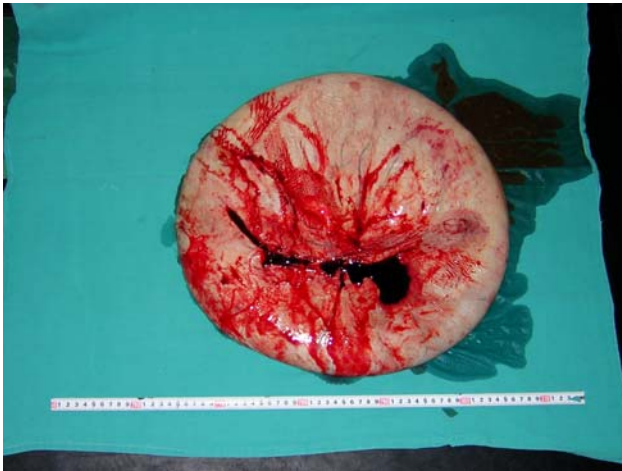


Fig. 4 – Macroscopic oval cystic formation, emptied

dominantly smooth with two polypoid formations of 25 and 50 mm, with honeycomb-like cross-sectional appearance. The cyst walls were lamellar, ranging in thickness from 5 to 10 mm. Along the exterior surface there was an unchanged tube with the length of 110 mm and diameter 5 mm. Microscopic analysis indicated a mucinous cystadenoma with partially present areas containing numerous papilar prominences with pseudostratified epitheloma exhibiting signs of nuclear and cellular irregularities and occasional presence of mitosis. There were no signs of epithel invasion in the ovary stroma, nor there was any penetration of the capsule of the ovary. Two samples of the omentum with a total mass of 100 grams only indicated signs of fibrosis. In the 14 analyzed lymph nodes only reactive changes were noted. A follicular cyst was removed from the left ovary. The definitive histological diagnosis was “Atypically proliferating mucinous tumor of the right ovary (Border line)”. The stage of the tumor disease was designated as FIGO Ia classification.

After receiving definitive histopathological results it was decided to perform a radical reoperation. On the 10th postoperative day a relaparotomy was performed, total hysterectomy and left adnexectomy. In the histological preparation following radicalization normal microscopic characteristics of the uterus and the second ovary were described. The postoperative period was normal. The scar healed *per primam*. The patient was released on the 6th postoperative day. The patient used to come to regular examinations up to date.

Discussion

Papillary serous low malignant potential tumors are characterized by malignant features and metastatic potential, yet display a benign clinical course⁴. Mucinous LMP tumors are bigger than serous ones with average diameter from 17 to 20 cm and they are rarely bilateral⁵. The patient presented in this paper had tumor localized at only one side ovary. Ovarian LMP tumor was bigger than any described in the literature. We removed the contents of 18 liters (Figure 1). Patients usually refer with pelvic mass and complain of abdominal and pelvic pain, increased abdominal diameter or abnormal bleeding. Ultrasound and computerized tomography could help in diagnosis of ovarian mass. Serum Ca 125 is not always elevated and can be near the normal range even if tumor is present⁶. Only high malignant tumors produce significant increase of serum Ca 125. The patient presented here had only a elevation of serum Ca 125. The patient had abdominal *staphylococcus* skin infection. Primary surgical treatment for patients with LMP tumors and already given births are similar as for invasive ovarian disease and include total abdominal hysterectomy, bilateral salpingoophorectomy and disease staging. We performed radical operation because the patient already had had five deliveries.

Conclusion

This case is a proof that atypical proliferating mucinous tumors have low malignant potential. They grow slowly and can reach great proportions, as in the presented patient.

R E F E R E N C E S

1. Liu Trimble C, Trimble EL. Management of epithelial ovarian tumors of low malignant potential. *Gynecol Oncol* 1994; 55(3 Pt 2): S52–61.
2. Fukumoto M, Nakayama K. Ovarian epithelial tumors of low malignant potential: are they precursors of ovarian carcinoma? *Pathol Int* 2006; 56(5): 233–9.
3. McKenney JK, Balzer BL, Longacre TA. Patterns of stromal invasion in ovarian serous tumors of low malignant potential (borderline tumors): a reevaluation of the concept of stromal microinvasion. *Am J Surg Pathol* 2006; 30(10): 1209–21.
4. Bonome T, Lee JY, Park DC, Radonovich M, Pise-Masison C, Brady J, et al. Expression profiling of serous low malignant potential, low-grade, and high-grade tumors of the ovary. *Cancer Res* 2005; 65(22): 10602–12.
5. Twaalfhoven FCM, Peters AA, Trimbos JB. The accuracy of frozen section diagnosis of ovarian tumors. *Gynecol Oncol* 1991; 41(3): 189–92.
6. Schem Ch, Bauerschlag DO, Meinhold-Heerlein I, Fischer D, Friedrich M, Maass N. Benign and borderline tumors of the ovary. *Ther Umsch* 2007; 64(7): 369–74.

The paper was received on March 6, 2008.