

APPLICATION OF IMAGING METHODS IN THE DIAGNOSTICS OF MALIGNANT NECK LYMPH NODES

Slađana Petrović, Maja Jocić, Dragan Stojanov

The presence of malignant lymph nodes in the neck is a prognostic factor in planocellular carcinomas of the head and neck which are the most common primary tumors of this region. Determination of neck lymph nodes involvement is necessary for deciding on surgical treatment and planning chemotherapy and radiation therapy.

Metastases in the neck lymph nodes reduce patient survival to a half. Localization of metastatic lymph nodes, their number and size are also very important factors which correlate with distant metastases. Besides clinical examination which includes inspection and palpation of the neck, the diagnostics of metastatic neck lymph nodes also uses imaging techniques: ultrasound (US), computerized tomography (CT) and magnetic resonance imaging (MRI). Precision and reliability of these methods depends on the application of adequate radiological criteria in the diagnostics of malignant lymph nodes of the neck. *Acta Medica Medianae 2013;52(2):45-50.*

Key words: *lymph nodes of the neck, tumors of the head and neck, US, CT, MRI, metastases*

University of Niš, Faculty of Medicine, Niš, Serbia⁴

Contact: Maja Jocić
University of Niš, Faculty of Medicine
Bulevar Zorana Đinđića 81, 18000 Niš, Serbia
E-mail: maja.stojanovic016@gmail.com

Introduction

The presence of malignant lymph nodes on the neck is the most important prognostic factor in planocellular carcinomas of the head and neck which are the most common primary tumors of this region. The size of malignant tumors of the head and neck provides lymphogenic metastasis of the neck. Depending on localization of the primary tumor, up to 80% of patients with malignant tumors of mucosal space of the upper aerodigestive tract have metastatic lymph nodes on the neck (1).

Besides inspection and palpation of the neck as part of clinical examination, the diagnostics of primary tumor and malignant lymph nodes of the neck also requires the application of radiological methods whereby the size and local spread of the primary tumor are determined, as well as invasion of the neck lymph nodes and presence of distant metastases (2,17). Determining the invasion of the neck lymph nodes is necessary in patients with head and neck carcinomas as it is used as a prognostic factor and for determining surgical strategy and planning chemotherapy and radiation therapy (3).

In patients diagnosed with carcinomas of the head and neck, the presence of unilateral metastatic lymph nodes reduces the five-year survival by 50%, whereas the presence of bilateral metastases reduces the five-year survival

by another 25% (4,5). Metastatic lymph nodes on the neck and neck carcinomas are usually located on the side of the neck where the primary tumor is and it is in line with the primary tumor. Therefore, distribution of metastatic lymph nodes in patients with unknown primary tumor is very important because it can show the location of the primary neoplastic process. In addition, metastatic lymph nodes in unexpected places point to the presence of biologically more aggressive primary tumor (4).

Evaluation of morphology of the neck lymph nodes with the aim of determining the metastases represents one of the greatest challenges for radiologists.

The diagnostics of metastatic neck lymph nodes uses imaging methods: ultrasound, computerized tomography and magnetic resonance imaging.

Ultrasound criteria

The ultrasound is the first method in the diagnostic algorithm of malignant lymph nodes of the neck. The advantages of this method include availability, absence of ionizing radiation, harmlessness and repeatability. The negative points are inability to diagnose the majority of deep primary tumors and lymph nodes.

The ultrasound can detect neck lymph nodes by grey-scale sonography (B mode) and Doppler effect. To determine whether a lymph node is benign or malignant, the following parameters are used: size, shape, borders, level of echogenicity, echogenic hilus, presence of necrosis and calcification, extracapsular spread, vascularization (6).

The size is one of the criteria for estimation of malignancy. Depending on anatomical level,

axial diameter of the lymph nodes has different values (5, 8, 10mm). In general, the lymph nodes above 10mm are considered enlarged, i.e. they have higher incidence of malignancy (5,6,11). However, size cannot be used as an independent factor in the differentiation of reactively enlarged metastatic lymph nodes because the reactive nodes can also be enlarged. Size is a useful parameter when an increase in size of the lymph nodes in patients diagnosed with carcinoma points to lymphogenic spread, whereas reduction in size is useful for estimating the response to treatment.

The shape of the lymph node can also be a malignancy indicator. The metastatic nodes are frequently round and the short/long ratio is above 0.5; reactive lymph nodes are elliptic and their short/long ratio is less than 0.5 (4-6). This criterion helps in the detection of malignant lymph nodes but it should not be forgotten that, for instance, submandibular and parotid nodes have a round shape. In any case, this is one of the useful signs in the detection of malignant lymph nodes.

Contrary to general opinion, metastatic lymph nodes have clear borders while the borders of benign nodes are irregular. The clear borders of metastatic lymph nodes develop due to infiltration which causes an increase in acoustic impedance between the node and surrounding tissue (5). However, metastatic lymph nodes in late stage can display indistinct borders which points to extracapsular spread. This parameter is not reliable as an independent criterion in the estimation of benign-malignant character in the routine clinical practice. However, the presence of indistinct borders in diagnosed lymph nodes points to extracapsular spread and it is a useful parameter in disease prognosis.

Metastatic lymph nodes are hypoechogenic compared to the surrounding muscles. But the metastases of papillary carcinoma of the thyroid are usually echogenic as a consequence of the presence of deposits of thyroglobulin which comes from the primary tumor (6-9).

The ultrasound of normal lymph nodes shows centrally localized echogenic hilus which is presented as an echogenic structure which is in continuity with the surrounding fat tissue. Echogenic hilus is a consequence of the presence of multiple medullary sinuses which represent an acoustic border and partially reflect ultrasonic waves so that they are presented as echogenic structure (4,5,10). In a normal neck, about 90% of nodes with maximum transversal diameter above 5mm are presented with echogenic hilus and its presence is generally considered a sign of benign character (6). Some studies show that echogenic hilus can also be found in malignant lymph nodes.

Necrosis can be seen as cystic (cystic or liquefactive necrosis) or echogenic (coagulative necrosis) zone within the lymph node. Cystic necrosis is a more common form of necrosis

which is presented as echolucent zone within the node. Coagulative necrosis is rare and it is represented as an echogenic focus in the lymph node but it is not in continuity with the surrounding fat tissue and it does not have an acoustic shadow. Necrosis can also be found in metastatic and tuberculous lymph nodes and, regardless of the node size, it is considered pathological (4,6).

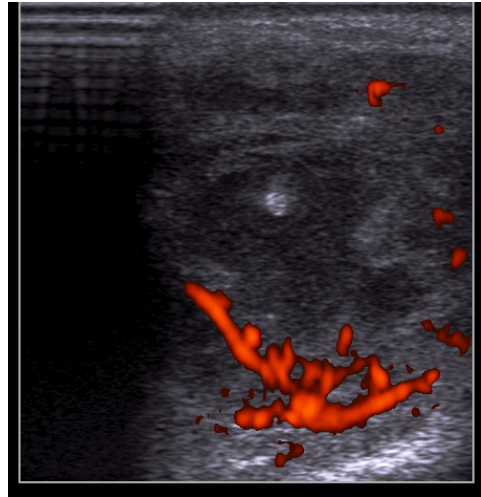


Figure 1. Power doppler sonogram of malignant lymph node on the neck with necrotic focus in tongue carcinoma (findings confirmed by PH analysis)

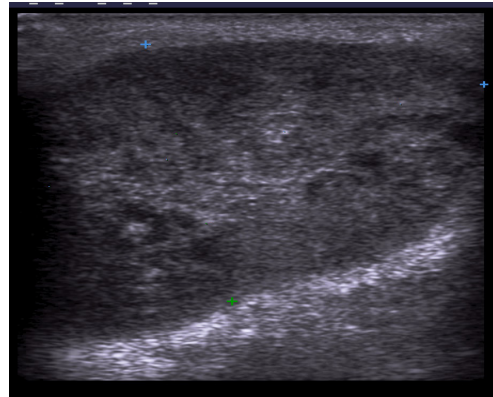


Figure 2. Grey-scale sonography shows an enlarged lymph node on the neck in adenocarcinoma of parotid salivary gland (findings confirmed by PH analysis)

Calcification is rare but metastatic lymph nodes in papillary carcinoma of the thyroid usually show the presence of calcification. Calcification is commonly punctiform, peripherally localized and they have an acoustic shadow. A relatively higher incidence of calcification in metastatic nodes of papillary carcinoma of the thyroid makes it a useful sign in the determination of adenopathy and direct search for primary tumor in the thyroid (4-10).

Vascularization was shown to be a useful factor in the detection of malignancy and/or benignancy of the lymph nodes of the neck. Pathohistological research has shown that arteries

and veins enter the lymph node through the hilus and they spread longitudinally. About 90% of normal lymph nodes with maximum transversal diameter above 5mm show hilar vascularization on the power doppler sonography (7). Normal and reactive lymph nodes usually show hilar vascularization or they are avascular. Contrary to this, the majority of metastases show the presence of aberrant blood vessels which enter the node through the capsule peripherally. Therefore, malignant lymph nodes can have peripheral or mixed (hilar-peripheral) vascularization. For this reason, the presence of peripheral blood vessels in lymph nodes is a useful indicator of malignancy (6,7).

Using the spectral analysis on the Doppler sonography it is possible to determine vascular resistance in the lymph node. It is shown as resistance index (RI) or in pulsatility index (PI). In metastatic lymph nodes vascular resistance increases because blood vessels are compromised by tumor cells. It was shown that vascular resistance in malignant lymph nodes is higher than in benign and the border values are different according to various authors. Most commonly used border values are 0.7 for RI and 1.4 for PI. For these values of RI and PI, the Doppler sonography shows 86% and 80% sensitivity and 70% and 86% specificity in the detection of malignant neck lymph nodes (4-6).

None of the stated sonographic criteria are absolutely specific and cannot be used independently in determining the benign or malignant character of the lymph nodes on the neck. Normal lymph nodes are oval hypoechoic structures with different amount of the hilar fat; they show hilar vascularization or they are hypovascular. However, lymph node diameter above 10mm, round shape, absence of hilus, irregular and spicular contours, necrosis and peripheral vascularization are highly suspicious signs of malignancy, particularly when they are present in the same lymph node. Using these criteria, the ultrasound is 89-94% accurate (17).

The major disadvantage of this method is that it can show only superficial structures up to the depth of 4-6 cm, so that deep lymph nodes are not available for examination, as well as most of primary neck tumors.

In all cases, when there is suspicion of malignancy, ultrasound-guided fine needle aspiration is indicated. Sensitivity of ultrasound-guided aspiration is 82% and specificity is 97% (8).

Computerized tomography (CT) and magnetic resonance (MRI)

CT and MRI methods are also applied in the diagnostics of malignant neck lymph nodes before surgical treatment. CT and MRI findings in combination with lymphadenopathy classification enable surgeons to plan the surgical treatment. CT and MRI enable detection of anatomical

structures based on which it is possible to classify neck lymphadenopathies. Imaging-based classification of neck lymph nodes was produced in cooperation with head and neck surgeons so that the level of lymph nodes is determined with the application of the most frequently used clinically based classification of lymph nodes into six levels depending on their localization. The most frequently included levels depend on primary localization of malignant tumor (12, 13).

CT and MRI are radiological methods mostly used with the aim of determining the stage of tumor development, that is, in detection of primary neck tumors and lymph node status. These methods are applied with the aim of pre-operative diagnostics of head and neck malignancies for outlining a precise surgical plan and monitoring the effects of treatment.

CT is nowadays used routinely in pre-operative preparation and it increased the diagnostic incidence of occult neck lymphadenopathies which could not be detected by clinical examination. The development of multislice CT scans (MSCT) improved spatial and temporal resolution and this technique enabled quick scanning of a large body volume in a short time period of holding the breath. Besides, the application of multiplane and three-dimensional images contributed to a better diagnostics and determination of tumor borders in all three planes and to a higher sensitivity in detecting malignant lymph nodes of the neck. MSCT of the neck includes the two-phase scanning; the first being native and the second post-contrast phase. The negative side of this method is ionizing radiation. Allergies to iodine contrasting agents which are applied in CT diagnostics are fortunately rare, considering that nowadays modern iodine contrast agents are used.

MRI is a radiological method which has excellent resolution in differentiation of soft tissue and its advantage is that it has no ionizing radiation. However, there are contraindications to MRI examination in patients with ferromagnetic implants and pacemakers, as well as in claustrophobic patients. Different protocols are used in MRI of the neck but the basic sequences are T1w, T2w and T1w after the application of contrasting agent – gadolinium chelate (11).

MRI has surpassed CT as a method used for evaluating primary head and neck carcinomas such as malignancies of the tongue and salivary glands. It is also sensitive in the detection of neck metastases.

Estimation of lymph node malignancy by CT and MRI is based on morphological criteria. In these imaging techniques normal lymph nodes are usually smaller than 1cm (12) in diameter, they have clear, well-defined borders, they show homogeneous density or signal intensity and they are usually oval in shape. Majority of benign lymph nodes has centrally positioned fat hilus in CT and MRI.

The most frequently used criterion for determining the nature of lymph nodes is the shorter axial diameter. Lymph nodes are considered metastatic if the shorter axial diameter is bigger than 11mm for lymph nodes in submandibular triangle and bigger than 10mm for other areas of the neck, which is the commonly used border value of the shorter diameter (14). It should be noted that lymph nodes with a diameter smaller than 10mm can also be altered by infiltration.

It has been determined that MRI is less sensitive than CT in the detection of malignant lymph nodes of the neck particularly in the detection of lymph glands metastases of subcentimeter dimensions (18).

Oval shape is also one of the criteria for differentiating malignant lymph nodes of the neck. It has been determined that round nodes are more often altered by infiltration than oval nodes. MRI has an advantage in determining the stage of development of the primary tumor but CT is quicker, less expensive and more accurate than MRI in determining the inclusion of the neck lymph nodes. According to various authors, CT and MRI sensitivity in the detection of metastatic lymph nodes ranges from 36% to 94%, while specificity ranges from 50% to 98% (15-17).

Although size as a criterion is the most frequently used for determining neck metastases, the accuracy of this criterion is insufficient due to false positive and false negative results.

Central necrosis is the most sensitive radiological criterion for diagnosing the metastatic lymph nodes of the neck, however, its absence does not exclude the presence of metastases. Necroses is presented in CT as a focal zone with low attenuations in the lymph node (Figure 3 and 4). In T2w of the MRI this zone is represented as the area of high and intermediary signal intensity (Figure 5). Necrosis can also be hyper-signaling (induces cytic necrosis) or hypo-signaling (induces keratinization). Lymph node signal homogeneity should be estimated on post-contrasting Tw1 scans. Homogeneous post-contrasting signal amplification is considered normal. Heterogenic signal amplification develops in metastatic lymph nodes with necrosis. Necrosis detection in malignant lymph nodes of sub-centimeter dimensions is particularly important because it requires a careful analysis of internal structure (11,18).

Presence of central necrosis displayed on non-contrast T1w and T2w MRI sequences is 89% accurate in the diagnosis of metastatic lymph nodes of the neck whereas CT is 91-93% accurate (11). The use of new contrast agents in MRI diagnostics, such as supramagnetic contrast agents as well as advanced MRI techniques, it is possible to increase MRI sensitivity in the diagnostics of metastatic lymph nodes of the neck. Besides being an important radiological criterion, central necrosis is a very significant prognostic factor in patients receiving chemotherapy and radiation therapy.

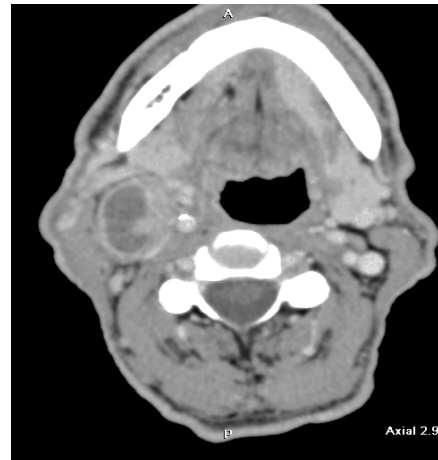


Figure 3. Axial postcontrast MSCT tomogram shows the presence of metastatic alteration of lymph node on the right side of the neck with necrotic center in planocellular carcinoma of the larynx (findings confirmed by PH analysis)

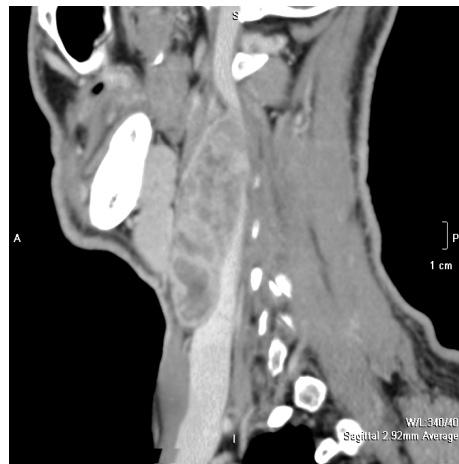

Figure 4. Sagittal postcontrast MSCT tomogram shows a conglomerate of necrotic lymph nodes on the neck in planocellular carcinoma of the hypopharynx (findings confirmed by PH analysis)

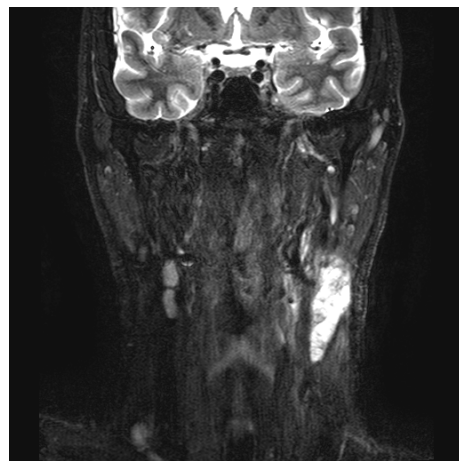


Figure 5. Coronary T2 MRI tomogram with fat suppression shows the presence of conglomerates of necrotic lymph nodes altered by metastasis on the left side of the neck in planocellular carcinoma of the root of the tongue (findings confirmed by PH analysis).

Macroscopic extracapsular spread of the tumor process can be diagnosed in postcontrast CT and MRI T2w images with fat suppression, when it is presented as border irregularity and infiltration of the surrounding fat. It is believed that extracapsular spread exists in large lymph nodes but it can also be present in lymph nodes of subcentimeter dimensions. Therefore, a careful analysis of lymph node borders is necessary since macroscopic extracapsular spread has a higher incidence of recurrence than the presence of microscopic or absence of extracapsular spread.

Conclusion

Reliability and precision of imaging methods depend on the application of adequate radiological criteria in the diagnostics of malignant lymph nodes on the neck.

By the application of morphological criteria and estimation of vascularization, the ultrasound shows high sensitivity in the detection of meta-

static lymph nodes on the neck. The limitations of the method include inability to show deep lymph nodes and majority of primary tumors. Ultrasound-guided biopsy can increase the diagnostic accuracy of the method.

CT and MRI are the most frequently used methods for simultaneous diagnosis of primary tumors of the neck and metastatic lymph nodes. The application of new contrast agents in MRI diagnostics, such as supramagnetic contrast agents as well as advanced MRI techniques, can increase MRI sensitivity in diagnosing metastatic lymph nodes of the neck.

Each of the listed methods has both advantages and weaknesses and it is necessary to consult a radiologist concerning the choice of technique and to adjust it to individual patient needs. However, it needs to be pointed out that surgical biopsies and neck dissections with detailed pathohistological examination are still a golden standard in detecting metastatic lymph nodes of the neck.

References

- Chong V. Cervical lymphadenopathy: what radiologists need to know. *Cancer Imaging* 2004; 4(2) :116-20. [[CrossRef](#)] [[PubMed](#)]
- Ganeshalingam S, Koh DM. Nodal staging. *Cancer Imaging* 2009; 9: 104-11. [[CrossRef](#)]
- Nakamura T, Sumi M, Kimuru Y, Sumi T. Whole-neck imaging for the screening of metastatic nodes. *Japanese Dental Science Review* 2010; 46: 73-7. [[CrossRef](#)]
- Ahuja AT, Ying M, Ho SY, Antonio G, Lee YP, King AD, et al. Ultrasound of malignant cervical lymph nodes. *Cancer Imaging* 2008; 8: 48-56. [[CrossRef](#)]
- Ahuja A, Ying M. Sonography of Neck Lymph Nodes. Part II: Abnormal Lymph Nodes. *Clinical Radiology* 2003; 58(5): 359-66. [[CrossRef](#)]
- Dudea SM, Lenghel M, Botar-Jid C, Vasilescu D, Duma M. Ultrasonography of superficial lymph nodes: benign vs. Malignant. *Med Ultrason* 2012; 14(4): 294-306.
- Ying M, Ahuja AT. Ultrasound of neck lymph nodes: How to do it and how do they look? *Radiography* 2006;12:105-17. [[CrossRef](#)]
- Khanna R, Sharma AD, Khanna S, Kumar M, Shukla RC. Usefulness of ultrasonography for the evaluation of cervical lymphadenopathy. *World J Surg Oncol* 2011;9:29. [[CrossRef](#)]
- Sohn YM, Kwak JY, Kim EK, Moon HJ, Kim SJ, Kim MJ. Diagnostic approach for evaluation of lymph node metastasis from thyroid cancer using ultrasound and fine-needle aspiration biopsy. *Am J Roentgenol* 2010;194:38-4.3
- Ahuja AT, Ying M. Sonographic evaluation of cervical lymph nodes. *Am J Roentgenol* 2005;184(5):1691-9. [[CrossRef](#)]
- Mack MG, Rieger J, Baghi M, Bisdas S, Vogl TJ. Cervical lymph nodes. *Eur J Radiol* 2008; 66 (3): 493-500. [[CrossRef](#)]
- Sham ME, Nishat S. Imaging modalities in head and neck cancer patients-overview. *J of cancer research and exp. Oncology* 2011; 3: 22-5.
- Silverman PM. Lymph node imaging: multidetector CT (MDCT). *Cancer Imaging* 2005; 5: S57-S67. [[CrossRef](#)]
- Petrovic S, Petrovic D, Stojanov D, Kovacevic P. Classification of neck Lymphadenopathies using multidetectors computerized tomography. *HealthMED* 2011; 5(1): 63-72.
- Hung SH, Lin CY, Lee JY, Tseng H. Computed tomography image characteristics of metastatic lymph nodes in patients with squamous cell carcinoma of the head and neck. *Auris Nasus Larynx* 2012; 39(6): 606-10. [[CrossRef](#)]
- Stoekli SJ, Haerle SK, Strobel K, Haile SR, Hany TF, Schuknecht B. Initial staging of the neck in head and neck squamous cell carcinoma: a comparison of CT, PET/CT, and ultrasound-guided fine-needle aspiration cytology. *Head Neck* 2012; 34(4): 469-76. [[CrossRef](#)]
- Torabi M, Aquino SL, Harisinghani MG. Current Concepts in Lymph Node Imaging. *J Nucl Med* 2004; 45(9):1509 -18.
- de Bondt RB, Nelemans PJ, Bakers F, Casselman JW, Peutz-Kootstra C, Kremer B, et al. Morphological MRI criteria improve the detection of lymph node metastases in head and neck squamous cell carcinoma: multivariate logistic regression analysis of MRI features of cervical lymph nodes. *Eur Radiol* 2009; 19(3): 626-3. [[CrossRef](#)]

PRIMENA SLIKOVNIH METODA U DIJAGNOSTICI MALIGNIH LIMFNH ČVOROVA NA VRATU

Slađana Petrović, Maja Jocić, Dragan Stojanov

Prisustvo malignih limfnih čvorova na vratu je najvažniji prognostički faktor kod planocelularnih karcinoma glave i vrata, koji su i najčešći primarni tumori ove regije. Određivanje zahvaćenosti limfnih čvorova na vratu neophodno je zbog određivanja hirurške strategije i plana hemio- i radioterapije.

Metastaze u limfnim čvorovima vrata smanjuju preživljavanje bolesnika za polovinu. Lokalizacija metastatskih limfnih čvorova, njihov broj i veličina takođe su veoma važni. Ovi faktori koreliraju sa udaljenim metastazama. Za dijagnostiku metastatski izmenjenih limfnih čvorova na vratu, pored kliničkog pregleda, koji obuhvata inspekciju i palpaciju vrata, koriste se slikovne-imidžing metode: ultrazvuk (US), kompjuterizovana tomografija (CT) i magnetna rezonanca (MR). Preciznost i pouzdanost ovih metoda zavisi od primene adekvatnih radioloških kriterijuma za dijagnostiku malignih limfnih čvorova na vratu. *Acta Medica Medianae 2013;52(2):45-50.*

Ključne reči: *limfni čvorovi vrata, tumori glave i vrata, US, CT, MR, metastaze*