
Veterinary Research Forum**Vol: 2, No: 1, March, 2011, 59 - 63**

Short Communication**Effects of Parasitic Infections on Erythrocyte Indices of Camels in Nigeria****Jalailudeen Lawal Rabana¹****Hussein Adam Kumshe¹****Joshua Kamani^{2*}****Grema Hafsat¹****Usman A Turaki¹****Harrison K Dilli³**¹*Department of Veterinary Medicine, University of Maiduguri, Nigeria*²*Parasitology Division, National Veterinary Research Institute, Vom, Nigeria*³*Ministry of Livestock Production, Yola, Nigeria*

Received: 5 December 2010, Accepted: 13 February 2011

Abstract

This study was conducted to determine the prevalence and effect of parasitic infection on erythrocyte indices in trade camels slaughtered in Maiduguri, Nigeria. Two hundred adult one humped camels comprised of 87 (43.5 %) males and 113 (56.5 %) females were examined for helminths and hemoparasites at their slaughter time according to the standard procedures. An overall prevalence of 79 % for single and mixed infections was observed. Examination of faecal samples from camels shows 82 (41 %) were harbouring different nematodes, mostly Strongyle, Strongyloides and Hemonchus species. Buffy coat and thin smear examination of blood samples showed Babesia and Anaplasma species. More females (44.5 %) than males (34.5 %) were positive for various parasitic infections. But the percentage was not statistically significant ($P > 0.05$). Packed cell volume (PCV), mean haemoglobin concentration (MCH), mean corpuscular haemoglobin concentration (MCHC) and red blood cell counts were significantly ($P < 0.01$) affected in the infected camels compared to the non-infected ones. Parasite infection in camels leads to macrocytic anaemia.

Key words: Erythrocyte indices, Parasites, Camel, Semi-arid, Nigeria.

***Corresponding author:**

Joshua Kamani, DVM, PhD

Parasitology Division, National Veterinary Research Institute, Vom, Nigeria

Email address: shapumani@yahoo.com

Introduction

The camel forms an integral part of the culture and agriculture of many countries and has existed for thousand of years. It is an important work animal of the arid and semi-arid ecosystem because of its unique adaptive physiological characteristics. There are two members of the old world camels living in Africa and Asia; *Camelus dromedarius* (one humped camel) and *camelus bacitrianus* (two humped). Camels have been used and bred for several thousand years, but the effort to understand their biology and diseases in greater depth has only been done fairly recently, especially in Nigeria.

The one humped camel (*Camelus dromedarius*), with an estimated population of 92,000 is the predominant camel species in Nigeria.¹ In general there has been a steady increase in the population of camels over the last decade. Diseases are the major factor affecting camel production in the most developing countries of the tropics, causing an increased cost of production, lower productivity and, in most cases, often result in loss of the animal. Camels in north-eastern Nigeria are usually raised under a free range nomadic system of management over a wide expanse of uncultivated pasture with low or no veterinary attention. Sometimes camel merchants purchase them from neighbouring Chad and Niger republics and herd them on hoof to Maiduguri where they are slaughtered immediately for meat. However, when they are in poor body condition they are allowed to graze on available pasture until their condition improves. Some are salvaged, even in poor condition, to avoid loss by the merchants. Earlier studies of parasitic conditions of camels in north-eastern Nigeria revealed major problems such as helminthosis, trypanosomosis, and Babesiosis. These conditions constitute a threat to successful camel production in the area.^{2,3} In general, most camel diseases must be considered as

herd problems. Common manifestations of parasitosis in camels are anaemia, emaciation, rough hair coat, retarded growth, reduced ability and ill thrift. Hematological and biochemical analysis of blood can often provide valuable information regarding the health and sickness of animals.^{4,5} There is paucity of information on the effect of parasitosis on the hematology of the one humped camel in Nigeria. This study was conducted to determine the prevalence and effects of parasitosis on erythrocyte indices of trade camels in semi arid regions in Nigeria.

Materials and Methods

Study Area. The study was conducted in Borno State of Nigeria. It is the most north-easterly state in Nigeria, with an area of 69,435 sq. km. The state lies between latitude 10°N and 13°N and longitude 12° E and 15°E.

Animals. Two hundred adult one humped dromedary camels brought to the Maiduguri abattoir for slaughter were randomly sampled over a period of one year for this work.

Blood sampling and analysis. For the hematological analysis, blood was obtained directly from the jugular vein at the point of slaughter. About 5ml of blood was drawn into vacutainers containing disodium ethylenediamine-tetra-acetic acid (EDTA) as an anticoagulant. The anticoagulated blood was used immediately for the determination of erythrocyte count, packed cell volume (PCV), and hemoglobin (Hb) concentration. The hematological indices; mean corpuscular volume (MCV), mean corpuscular hemoglobin (MCH) and mean corpuscular hemoglobin concentration (MCHC), were calculated from the erythrocytic series values.^{6,7} Thin smears were prepared from anticoagulated blood, air dried, fixed in methanol and stained with Giemsa. Microscopic examination was done using Nikon Microscope 1000 X

Faecal sampling and analysis. About 10gm of faeces were collected per rectum of the slaughtered camels into an air tight container and transported to the laboratory for analysis. The samples were analysed by flotation in saturated Sodium Chloride solution and sedimentation methods.⁸ Processed samples were examined microscopically using Nikon Microscope 100 X; identification was done according to the keys of Soulsby.⁸

Statistical analysis. Data were summarized by descriptive statistics for mean and standard deviation. Significance testing was done by one-way ANOVA, using Statistix[®] Software.

Results and Discussion

Two hundred camels comprised of 87 male (43.5 %) and 113 female (56.5 %) were examined for helminths and hemoparasites at slaughter. Overall, 153 (79 %) of the camels examined were infected by parasites. 82 (41 %) of the camels examined were harbouring different nematodes such as Strongyle, Strongyloides, Trichuris and Hemonchus species. Thirty three (16.5 %) of the camels were positive for both helminths and hemoparasites (Table 1). Packed cell volume (PCV), haemoglobin concentration and red blood cell counts were normal for all animals that were free for all parasite infection, but significantly ($P < 0.01$) altered in infected camels. Babesia and Anaplasma species were the common hemoparasites seen in camels examined either singly or in combination. More females (44.5 %) than males (34.5 %) were positive for various parasitic infections. Prevalence of helminths infection was highest (41 %), followed by hemoparasites (21.5 %) and those affected by both endoparasites and hemoparasites (16.5 %). The erythrocyte indices were within the normal range reported in Nigeria for the negative camels; however, the PCV, haemoglobin, mean cell volume (MCV), mean cell haemoglobin (MCH)

and mean cell haemoglobin concentration (MCHC) values were significantly ($P < 0.01$) different for the infected camels. Packed cell volume was severely affected in camels infected by both hemoparasite and helminths compared to those infected by either type of parasite alone (Table 2).

Camels are important animals in the semi arid regions both, as work animals and as a source of animal protein, and are becoming even more relevant due to the threat of desert encroachment and depletion of available pasture for grazing and browsing of cattle, sheep and goats in the northern fringes of Nigeria. Parasitosis causes significant damage to the production and reproduction of livestock in the tropics. They are responsible for reduction in quantity and quality of meat and milk production. There are several reports of the prevalence of parasitosis in camels in Borno State.^{3,9,10} The prevalence of helminths and mix infection (57.5 %) in this study is lower than the 68.9 % earlier reported in the same region.³ There was a significant ($P < 0.01$) effect on the red blood cell indices compared to non-infected camels in the same area (Fig 1).

Anaemia was found in both helminths and hemoparasite infected camels. The PCV in the infected animals was significantly ($P < 0.01$) lower than in non-infected animals, which is usually the case in most parasitic infection. MCV value for infected animals was significantly ($P < 0.01$) higher than in non-infected animals as a result of the large number of immature RBCs release in circulation in response to anaemia.

A similar observation was reported in one humped camels in Sudan.¹¹ The anaemia was macrocytic, which could be attributed to large number of reticulocytes in circulation as a result of the active response from the red bone marrow. This is similar to an earlier report which showed that *Anaplasma marginale* significantly affects the RBC indices of the camels.¹¹

Table 1. Prevalence of parasitic infection in slaughtered camels in Maiduguri, Nigeria

Parameters	Negative	Camels positive (%)			Total
		Helminths	Hemoparasites	Both	
Male	18(.9)	37(18.5)	20(10)	12(6)	87(43.5)
Female	24(12)	45(22.5)	23(11.5)	21(10.5)	113(56.5)
Total	42(21)	82(41)	43(21.5)	33(16.5)	200(100)

Table 2. Haematological indices of infected and non-infected camels slaughtered in Maiduguri

Parameters	Negative	Camels positive (%)		
		Helminths	Hemoparasites	Both
PCV (%) ± SD	37.3 ± 4.9	21.0 ± 2.3*	17.7 ± 3.3*	16.6 ± 3.4*
Hb(g dL ⁻¹)	11.8 ± 1.8	8.6 ± 1.1 *	7.9 ± 0.8 *	8.0 ± 1.7*
RBC(x10 ⁶ /uL)	8.3 ± 0.7	5.8 ± 1.2 *	3.3 ± 0.6*	3.5 ± 0.8*
MCV (fL)	44.9	55.3 *	53.6 *	47.4*
MCH (pg)	14.2	22.6 *	23.9 *	22.8*
MCHC (g dL ⁻¹)	31.6	40.9*	44.6*	48.2*

*Values with asterisk are significantly different from the non infected animals (negative) ($P < 0.01$)

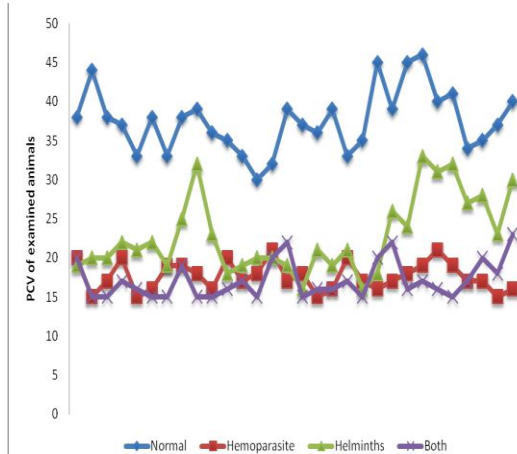


Fig 1. Effects of parasites on PCV of one humped camels

The high MCHC value for infected animals may be due to lysis of the RBC releasing haemoglobin into the plasma. The hemogram generally showed a significant decrease in the red blood cell count, hemoglobin and packed cell volume, reflecting macrocytic normochromic type of anemia, as earlier reported^{12, 13} in Nigeria and Sudan.

Pathogenesis of anemia due to parasitism could be attributed to the direct effect of the parasite on the infected erythrocytes, which may be incriminated, or the decreased life span of RBCs and also the suppression of the hemopoietic system.¹³ Anemia in infected camels could also be due to extensive erythrophagocytosis in the reticulo-endothelial system initiated by parasitic damage to erythrocytes. This study reveals the significance of parasite infection on the erythrocyte indices of camels in Northern Nigeria.

Acknowledgements

We gratefully acknowledge staff of NVRI Outstation Laboratory, Maiduguri for analysing the samples.

References

1. United Nations Industrial Development Organization Technical Report. Prepared for the government of Nigeria based on the mission of

- Gerhard Felsner hides and skins improvement expert. 2002; us/nir/01/e01/11-51
2. FAO. Manual for Primary Health Workers.Ch.7: Camels, Illamas and alpacas, 1994.
 3. Kamani J, Turaki A.U, Egwu G.O, et al. Prevalence of gastrointestinal parasites of camels (*Camelus dromedaries*) slaughtered in Maiduguri, Nigeria. Journal of Camel Practice and Research. 2008a ; 1 (5):181-182.
 4. Khalid A. AL-Busadah. Some Biochemical and Haematological Indices in Different Breeds of Camels in Saudi Arabia. Scientific Journal of King Faisal University (Basic and Applied Sciences) 2007; 8 (1):1428H
 5. Mohammed A.K, Sackey A.K.B, Tekdek L.B, et al. Mean haematological characteristics of healthy adult one humped camel (*Camelus dromedaries*) introduced into a semi-humid climate of Nigeria. Journal of camel Practise 2008; 15 (2):187-190.
 6. Coles EH. Veterinary Clinical Pathology 4th Ed. WB Saunders Co.Philadelphia 1986; 53-55.
 7. Dacie J. V. and Lewis S. M. Practical Hematology. Churchillivingstone. Edinburgh, UK 1991.
 8. Soulsby E.J.L Helminths arthropods and Protozoa of domesticated animals, 7th end. Bailliere Tindall, London 1982.
 9. Kamani J, Turaki A.U, Egwu G.O, et al. Haemoparasites of camels (*Camelus dromedarius*) in Maiduguri, Nigeria. Animal Research International 2008b; 5(2): 838 – 839.
 10. Alsaad K.M Clinical, hematological and biochemical studies of anaplasmosis in Arabian one-humped camels (*Camelus dromadaries*). Journal of Animal and Veterinary Advances 2009; 8(9): 1794 - 1797.
 11. Mohammed A.K., Sackey Z.A, Tekdek B.K. et al. Common health problems of the one humped camel (*Camelus dromedarus*) introduced into Sub-humid climate in Zaria, Nigeria. Res. J. Anim. Sci., 2007; 1: 1-5.
 12. Moghaddar N. Occurance of *Anaplasma marginale* in camels of Shiraz. Proceedings of the 3rd Iranian Veterinary Clinicians Conference, Oct. 29-31, Shiraz University, Mashhad, 2002; 35-38.
 13. Mahran O.M. Some studies on blood parasite in camels (*Camelus dromedaries*) at Shalatin city, Red Sea Governorate. Assiut Vet. J., 2004; 50: 172-183.