



Clinical Article

Congenital Goitre in Goats

A. H. Cheema, A. Shakoor and A. H. Shahzad

College of Veterinary and Animal Sciences, Jhang, Pakistan

ARTICLE HISTORY

Received: July 11, 2009

Revised: August 12, 2009

Accepted: September 01, 2009

Key words:

Goitre

Colloid

Hyperplastic

Goat

Congenital

ABSTRACT

One full-term, dead foetus was successfully removed from a 5-year old, crossbred black and white goat. The goat was stall-fed with green fodder and it delivered two dead foetuses in the previous pregnancy. The foetus had a large swelling in the cranio-ventral neck region. Upon cutting skin, the swelling revealed extremely enlarged thyroid gland having two asymmetrical lobes with the right lobe was 8.10 x 15.0 cm and the left 5.5 x 8.6 cm in size. The skin was devoid of hair, pale-white and thickened with myxedema. Histologically, the enlarged thyroid consisted of colloid goitre and the lungs were oedematous. This case of congenital goitre was unusual and differed from the reported cases in two aspects viz 1) the two lobes were enlarged but unequal and 2) histologically goitre was colloid instead of usual hyperplastic type.

©2010 PVJ. All rights reserved

To cite this article: Cheema AH, A Shakoor and AH Shahzad, 2010. Congenital goitre in goats. Pakistan Vet. J., 30(1): 58-60.

INTRODUCTION

Congenital goitre is a non-inflammatory and non-neoplastic enlargement of thyroid gland in the foetus and is regarded as a common anomaly in goats (Ani *et al.*, 1998). The condition is accompanied by an increase in the size of foetus, myxedema, prolonged gestation and dystocia (McDonald and Pineda, 1989). It has economic significance because the affected foeti seldom survive and the doe often parishes. The present paper describes an unusual case of congenital goitre in a kid in which the thyroid gland was extremely enlarged and the type of goitre was also different from the commonly reported hyperplastic type.

Clinical history and examination

A five-year old full-term pregnant black and white doe of local breed was brought to the Theriogenology Clinic at the College of Veterinary and Animal Sciences, Jhang, Pakistan with the complaint of difficult kidding. The owner had two other goats at home and he claimed to have lost nine kids in the last two years. According to the owner, the kids were born at full term, all had swellings in the cranio-ventral neck region and died within 15 minutes of birth. The goats were stall-fed on fresh green fodder, mostly maize (*Zea mays*) in summer and berseem (*Trifolium alexandrinum*) in winter. The doe under report started straining for kidding a day earlier but it failed to deliver. A veterinary technician was called in for professional help. One dead foetus was successfully

relieved but the second foetus could not be delivered and the animal was brought to the clinic with the history of straining for the last 16 hours.

Both fore-legs of the fetus were hanging from the swollen vulva with a reddish discharge. Clinical examination of the doe revealed 102°F rectal temperature, anorexia, rapid, shallow respiration and inability to stand up. Per-vaginal examination indicated the dead foetus in anterior presentation. The cervix was fully dilated and the head was turned downward between the legs with a large mass on the ventrum of cranial neck region.

Obstetrical procedure

At first, bilateral amputation of the fore-limbs at the shoulder joints was carried out. After an adequate lubrication (liquid paraffin) of birth canal, an obstetrical hook was inserted in the eye socket. Gentle traction resulted in the successful delivery of the remaining foetus. During this procedure, foetus was removed in rested phases to avoid hypovolemic shock to the dam. The placenta was also removed alongwith the foetus and the reproductive tract were examined for any injury or damage and abdominal palpation was carried out for the presence of triplet foetus, if any. Dextrose 5% with normal saline (500 ml) alongwith Dexamethasone (3 ml) was administered intravenously.

Gross pathological observations

The dead foetus was examined immediately after its removal. Later the carcass was opened and the thoracic

and abdominal viscera were examined. The tongue of the foetus was swollen and protruded from mouth along-with an enlargement in the upper neck region (Fig. 1). There was a total alopecia of body coat, except for some hair growth on the dorsal vertebral ridge and on the skull in the poll area. Cutting the soft and thickened skin revealed myxedema. The removal of skin from the swelling in the neck revealed two massive lobes of thyroid gland. The right lobe measured 8.10 x 15.0 cm, while the left lobe was 5.5 cm x 8.6 cm in size. These were firm, solid and dark brown to red in colour. The lungs were filled with clear oedematous fluid. Congenital goitre with alopecia and myxedema was diagnosed on the basis of gross appearance.

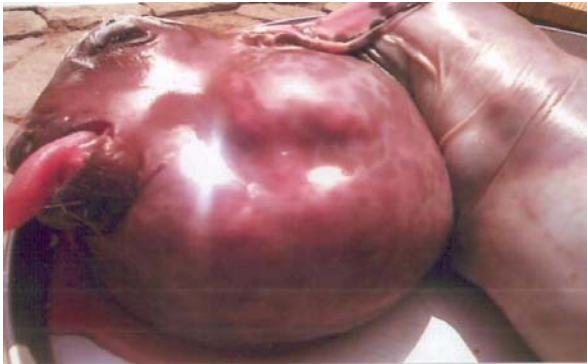

Fig. 1: Head and neck of a full-term dead goat foetus with swollen tongue, enlarged thyroid, alopecia and myxedema.

Histopathology

Tissues from different areas of thyroid, lungs, liver, kidneys and heart were processed by routine histological procedure. Tissue sections were cut at 4 μ m thickness and stained by routine haematoxyline and eosin method (Bancroft and Gamble, 2007). Thyroid tissue consisted of well developed follicles of different sizes and shapes but lined by a single layer of cuboidal epithelium. Marked variation was noted in the contents of follicles and appearance of the lining epithelium in different parts of the gland. Most of the follicles were filled with dense and dark-red colloid (thyroglobulin) and lined by flat cuboidal cells, but many follicles had a light pale or dirty brownish colloid. When the colloid was partially or completely removed, formation of endocytotic vacuoles was observed in many follicles (Fig. 2). Endocytotic vacuoles appeared at the luminal interface between the colloid and epithelium as well as on the vascular side of epithelium and in some follicles on both sides of epithelial cells. As the follicles were depleted of thyroglobulin, the lining epithelial cells were elongated and moved towards centre of the follicle, giving it a collapsed appearance. In some places, the depleted follicles contained loose masses of large cells with a considerable amount of acidophilic cytoplasm (Fig. 3).

In the lungs, the pleura and interlobular septae were thickened with a light-pink proteinaceous material (Fig. 4). Similar material was also present in the alveoli and around the blood vessels. The hepatic sinusoids were distended and there was pooling of erythrocytes in the periacinar

zones. Erythropoietic foci with megakaryocytes were frequent in the liver (Fig. 5).

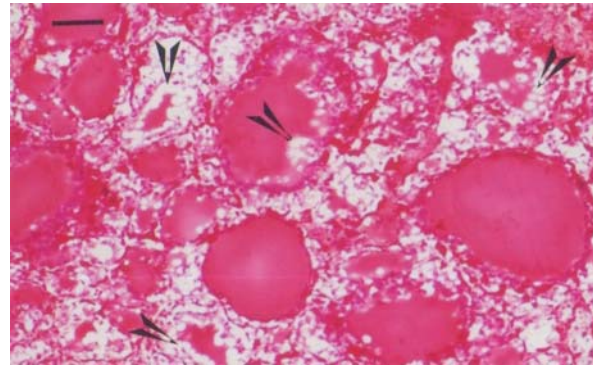


Fig. 2: Isolated thyroid follicles with formation of endocytotic vacuoles (arrows) and partial depletion of colloid (H & E, X 40).

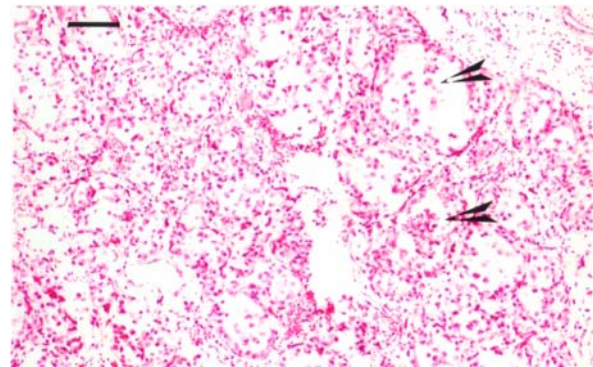


Fig. 3: Completely depleted follicles containing masses of sloughed lining epithelial cells (arrow head) with acidophilic cytoplasm (H & E, X 40).

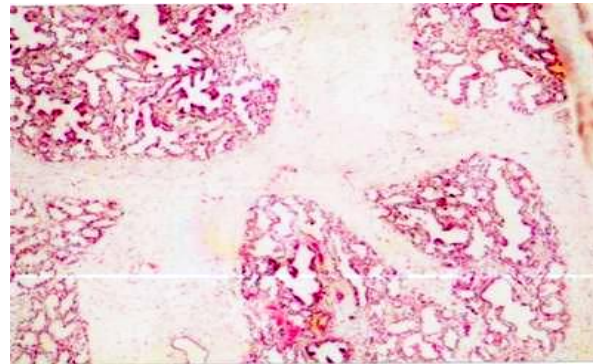


Fig. 4: Lung section from the goiterous foetus. The interlobular septae are distended and filled with a homogenous light-pink material (H & E, X 40).

DISCUSSION

Disorders in the synthesis, storage and secretion of thyroid hormones provide the molecular basis of abnormalities in the thyroid growth or thyroid dishormonogenesis which results in congenital hypothyroidism (Vijlder, 2003). The major pathogenic

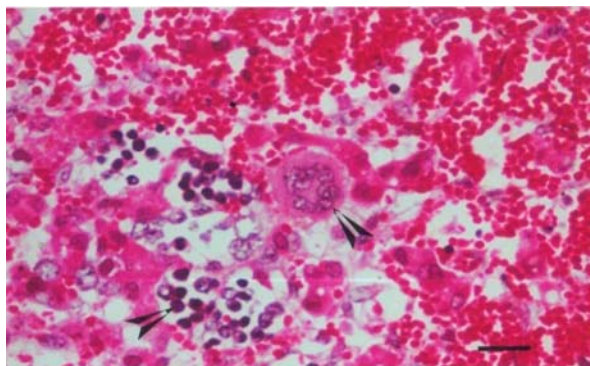


Fig. 5: Liver with distended sinusoids containing erythrocytes, haemopoietic cells and megakaryocytes (arrows, H & E, X 100).

mechanisms responsible for the development of thyroid hyperplasia include iodine deficient diets (Paulikova *et al.*, 2002), goitrogenic compounds and plants, dietary iodine excess and genetic enzyme defects in biosynthesis of thyroid hormones (McDonald and Pineda, 1989). Several types of goitre have been reported in the literature (McDonald and Pineda, 1989; Maxi, 2007) and classified on the basis of gross and microscopic appearance, clinical effects, etiology and pathogenesis. The most commonly reported type of congenital goitre is hyperplastic, in which there is excessive proliferation of thyroid secretory epithelium with the formation of solid clusters and slit-like follicles, with formation of papillary processes and villi into the follicular lumen. Bires *et al.* (1996) reported such condition in Slovak Republic. The epithelial cells are columnar in shape and there is a minimal amount of colloid in the follicles (Ani *et al.*, 1998; McDonald and Pineda, 1989; Maxi, 2007). However, the histopathological description of the case reported here fits the description of colloid goitre (McDonald and Pineda 1989) which has been described as the involutory phase of diffuse hyperplastic goitre in young and adults. In this case, thyroid hormone level in the blood returned to normal, the level of thyroid stimulating hormone was diminished and the hyperplastic follicular cells continued to produce colloid. According to Piosik *et al.* (1997), goat foetuses during gestation have to rely on their own thyroid hormone (T4 and T3) production during the second half of gestation. Iodine deficiency during pregnancy has particularly adverse effects like retardation of foetal development and dead or weak neonates with goitre. The findings of this case are similar with the results reported in cattle (Herzig and Suchy, 1996), sheep (Radostits *et al.*, 1994) and goats (Bires *et al.*, 1996).

The enormous size of the thyroid gland, presence of follicles filled with colloid and endocytotic activity raise several questions about its cause and pathogenic mechanism in this case. Endocytosis and depletion of colloid in the follicles suggested that T4 and T3 were being produced by foetus and the doe did supply some iodine in the late stages of pregnancy. Unfortunately, there was no opportunity to determine serum level of T4

and T3. As a mineral element, iodine cannot be synthesized in the body. Soil and consequently plants are the primary sources of iodine. Because the iodine concentration of soil of this area seems to be low, the feedstuffs cannot supply an adequate iodine intake for animals. So, Jhang district belongs to one of those regions of Pakistan where iodine deficiency disorders occur, both in the human population and farm animals, particularly in goats.

The record of District Veterinary Hospital, Jhang, indicated an entry of 16 cases of dystocia in goats from December 2008 to March 2009. Most of the affected goats belonged to the owners in the urban area, having 1-3 animals kept on green fodder. Animals which were allowed to graze freely were not affected. The preliminary survey made about this disease indicated that goat owners were aware of this problem and they used to supply Lugal's iodine to their animals in the drinking water during the last month of gestation and such animals had normal kidding. This study shows that there is an urgent need to investigate the causes, prevention and prophylaxis of congenital goitre in goats in Pakistan.

REFERENCES

- Ani AFK, WA Khamas, KMA Qudah and OA Rawashdah, 1998. Occurrence of congenital anomalies in Shami breed of goats; 221 cases investigated in 19 herds. *Small Rumin Res*, 28: 225-232.
- Bancroft JD and M Gamble, 2007. *Theory and Practice of Histological Techniques* 5th Ed, Churchill Livingstone London, UK, pp: 125-138.
- Bires J, P Bartko, T Weissona, A Michna and T Matisak, 1996. Iodine deficiency in goats as a cause of congenital goitre in kids. *Vet Med (Parha)*, 41(5): 133-138.
- Herzig I and P Suchy, 1996. Actual experience of importance of iodine for animals (in Czech). *Vet Med Czech*, 41: 379-386.
- McDonald LE and MH Pineda, 1989. *Veterinary Endocrinology and Reproduction*. 4th Ed, Lea and Febiger, Philadelphia, USA.
- Maxi MG, 2007. *Jubb, Kennedy and Palmer's Pathology of Domestic Animals*. 5th Ed, Vol 3rd, Saunders's Elsevier, New York, USA.
- Paulikova I, G Kovac, J Bires, S Paulik, H Seidel and O Nagy, 2002. Iodine toxicity in ruminants. *Vet Med-Czech*, 47(12): 343-350.
- Piosik PA, MV Groeningen, F Boes and JJMD Vijlder, 1997. Effects of maternal thyroid status on foetal development in congenitally hypothyroid goats. *Endocrinology*, 138: 5-11.
- Radostits OM, CC Gay, KW Hinchcliff and PD Constable, 2007. *Veterinary Medicine*. 10th Ed, Saunders-Elsevier, New York, USA.
- Vijlder D, 2003. Primary congenital hypothyroidism: defect in iodine pathways. *European J Endocrinol*, 149(4): 247-256.