

Stomach One-Point Cancer: One Case Report and Literature Review

Hao Zhang¹
Chengzhong Xing¹
Huimian Xu¹
Meixian Wang²

¹ Department of Surgical Oncology; ² Gastric Cancer Lab, the First Affiliated Hospital of China Medical University, Shenyang 110001, Liaoning Province, China.

Correspondence to: Huimian Xu
Tel: 86-24-8179 2725
E-mail: xuhuimian@126.com

Received December 15, 2008; accepted February 25, 2009.

E-mail: 2008cocrc@gmail.com
Tel (Fax): 86-22-2352 2919

KEY WORDS: stomach cancer, one-point cancer, treatment.

Copyright © 2009 by Tianjin Medical University Cancer Institute & Hospital and Springer

Introduction

Gastric cancer is one of the most common cancers and one of the most frequent causes of cancer deaths worldwide. Early detection and accurate preoperative staging of gastric cancer is essential for planning optimal therapy such as endoscopic mucosal resection or gastric resection and offers the best prognosis. With advanced technology in diagnostic instruments and the mass screening, early gastric cancer has been detected easier. One-point cancer of gastric is a special type of early gastric cancer^[1]. Diagnosis of one-point cancer of gastric is important for both the immediate treatment and the prognosis. There is still no consensus on the operation extent and postoperative treatment for patients with one-point cancer of gastric. Learned from previous reports^[2-5], we know that existed in the superficial layer of the gastric mucosa and the superficial ulcer is one of the important characteristics of one point cancer of gastric. Herein, we report a case of one point cancer of gastric with the appearance of a deep infiltrating ulcer. To the best of our knowledge, no such type of one point cancer of gastric has been reported.

Case Report

A 65-year-old man was admitted to the First Affiliated Hospital of China Medical University, Shenyang, China, with symptom of “upper abdominal pain for 6 months and aggravation for 1 month”. Gastroscopy showed a deep ulcer in the middle part of the gastric angle, with a size of approximate 1.0 cm × 1.0 cm, and an uneven bottom. The lesion was hard in texture, and covered by dirty musci, with an annular, dike-like intumescence of around the center of the ulcer. Gastroscopic biopsy revealed that progression of cancer was seen in several superficial layers of gastric mucous membranes. The size of the cancer cells varied, with apparent allotypic. Pathological diagnosis demonstrated that it was an adenocarcinoma of the gastric angle (in line with characteristics of moderately differentiated tubular adenocarcinoma). Under the condition of general anesthesia, the patient underwent radical distant subtotal gastrectomy and Billroth I gastroenterostomy. Postoperative pathology showed an ulcer-infiltrating neoplasm at the lesser curvature side, with blurry boundary, and a size of 3.5 cm × 2.5 cm × 1.3 cm. After serial sections and observation under microscopic, it was found that there was a clustering or irregular adeniform growth of a few cells in some superficial layer of a regenerative mucosa, but

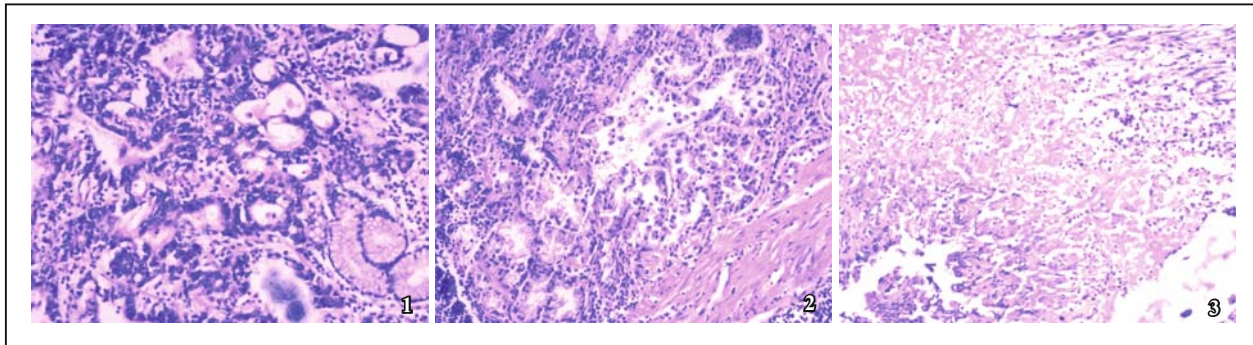


Fig.1. Moderately differentiated adenocarcinoma by gastroscopy

Fig.2. Postoperative pathological outcome: dysplasia/Postoperative dysplasia (H&E×100).

Fig.3. Postoperative pathological outcome: ulceration/Postoperative ulceration (H&E×100).

most of the cells were minor and uniform, with multiplication of individual nucleus in the cells. In general, the raw surface of ulceration was broad and deep, with thickening in the partial artery wall and severe intestinal and atrophic gastritis at rim of the ulceration. No metastatic lymph node was found in the 32 detected lymph nodes. During a postoperative follow-up for 45 months, neither recurrence, nor metastasis was found in the patient, and the survival status was satisfactory.

Discussion

In 1984, the denomination of the One-Point Cancer (OPC) was put forward by the Gastric Cancer Lab, China Medical University, Shenyang, China. The definition of OPC is when biopsy samples of the gastric mucosa are diagnosed as cancer. However, sometimes the cancer site accompanied by a benign ulcer, or anabrosis can not be found by microscopic examination after surgery. No cancer lesion is evident despite taking numerous, detailed, and serial sections. Hence, this tissue can be called OPC. Most reports demonstrated that the OPC was in conjunction with a superficial lesion, e.g., a superficial ulcerative, or intumescent focus of minor

areas^[1,2], and rare reports showed the OPC with deep ulceration. It was believed in quantities of previous reports that most of the OPC onsets result from chronic or superficial gastritis, usually accompanied by intestinal metaplasia, superficial anabrosis and ulceration, as well as dysplasia. The prognosis of OPC is favorable, and its treatment standard and risk factors of metastasis need further discussion.

References

- 1 Zhang PF, Zhang YC, Wang MX, et al. Special types of early gastric cancer. *Zhonghua Zhongliu Zazhi* 1999; 12: 52–54 (Chinese).
- 2 Zhang GW, Jiang ZZ, Chen CG. One point cancer of gastric (with 4 cases report). *Shiyong Aizheng Zazhi* 1994; 9: 206–207 (Chinese).
- 3 Chen QX. Analysis of 9 cases of one point cancer of gastric. *Zhongliu Yanjiu Yu Linchuang* 1999; 11: 56–57 (Chinese).
- 4 Chen HY, Lin WG, Li JY, et al. One point cancer of gastric (with 3 cases report) and review of the civil references. *Zhongguo Neijing Zazhi* 2005; 11: 772–774 (Chinese).
- 5 Zhao BY, Li AX, Ren DH, et al. A case of one point cancer of gastric. *Xiandai Zhongliu Yixue* 2004; 12: 94 (Chinese).